

2024  
March

Research And  
Evaluations In The  
Field Of Oral, Dental  
And Maxillofacial  
**SURGERY**

**EDİTÖRLER**

Prof. Dr. Zübeyde Özlem PARLAK BİÇER

**İmtiyaz Sahibi • Yaşar Hız**  
**Genel Yayın Yönetmeni • Eda Altunel**  
**Yayına Hazırlayan • Gece Kitaplığı**  
**Editörler • Prof. Dr. Murat ÜNAL**

**Birinci Basım • March 2024 / ANKARA**

**ISBN • 978-625-425-584-7**

© copyright

Bu kitabın yayın hakkı Gece Kitaplığı'na aittir.  
Kaynak gösterilmeden alıntı yapılamaz, izin almadan  
hiçbir yolla çoğaltılamaz.

**Gece Kitaplığı**

**Adres:** Kızılay Mah. Fevzi Çakmak 1. Sokak Ümit Apt  
**No:** 22/A Çankaya/ANKARA Tel: 0312 384 80 40

[www.gecekitapligi.com](http://www.gecekitapligi.com)  
[gecekitapligi@gmail.com](mailto:gecekitapligi@gmail.com)

**Baskı & Cilt**  
Bizim Buro  
**Sertifika No:** 42488

**Research And  
Evaluations In The Field  
Of Oral, Dental And  
Maxillofacial Surgery**

**2024 March**

Editörler:  
Prof. Dr. Murat ÜNAL



# İÇİNDEKİLER

## BÖLÜM 1

### TIPS FOR INTRAORAL BONE GRAFTING SURGERY

*Nur ALTIPARMAK, Sıdıka Sinem AKDENİZ*

*Ezgi ERGEZEN..... 1*

## BÖLÜM 2

### EVALUATION OF FILLING APPLICATIONS, TECHNIQUES, COMPLICATIONS AND BASIC PRINCIPLES IN THE FACE AREA

*Hüseyin Tutku BEKAR, Sinan Yasin ERTEM ..... 17*

## BÖLÜM 3

### BOTULINUM TOXIN APPLICATIONS OF ORAL MAXILLOFACIAL REGION

*Fatih DOĞANOĞLU, Sinan Yasin ERTEM..... 31*



# BÖLÜM 1

## TIPS FOR INTRAORAL BONE GRAFTING SURGERY

*Nur ALTIPARMAK<sup>1</sup>*  
*Sıdıka Sinem AKDENİZ<sup>2</sup>*  
*Ezgi ERGEZEN<sup>3 4</sup>*

1 Nur ALTIPARMAK DDS Phd, Baskent University Department of Oral and Maxillofacial Surgery, ANKARA Associate professor

2 Sıdıka Sinem AKDENİZ DDS PhD, Private practice, ANKARA, Professor

3 Ezgi Ergezen DDS, Baskent University Department of Oral and Maxillofacial Surgery, ANKARA, Assistant professor

4 Corresponding author: Ezgi Ergezen

Başkent Üniversitesi Diş Hekimliği Fakültesi, 11.sok No: 26 06490 Bahçelievler, Ankara, Turkey, Phone: +903122151336 +905377415292

Fax: +903122152962, e-mail: ezgiergezen@gmail.com

## **ABSTRACT**

Dental implants in the treatment of tooth deficiencies have been preferred with an increasing ratio. The amount of residual bone in the toothless region is the most important factor for implant indication. In cases where the amount of alveolar bone is inadequate, it is necessary to use various augmentation techniques in order to obtain successful results, to apply the implants in the right angle, to make an aesthetic and functional prosthesis.

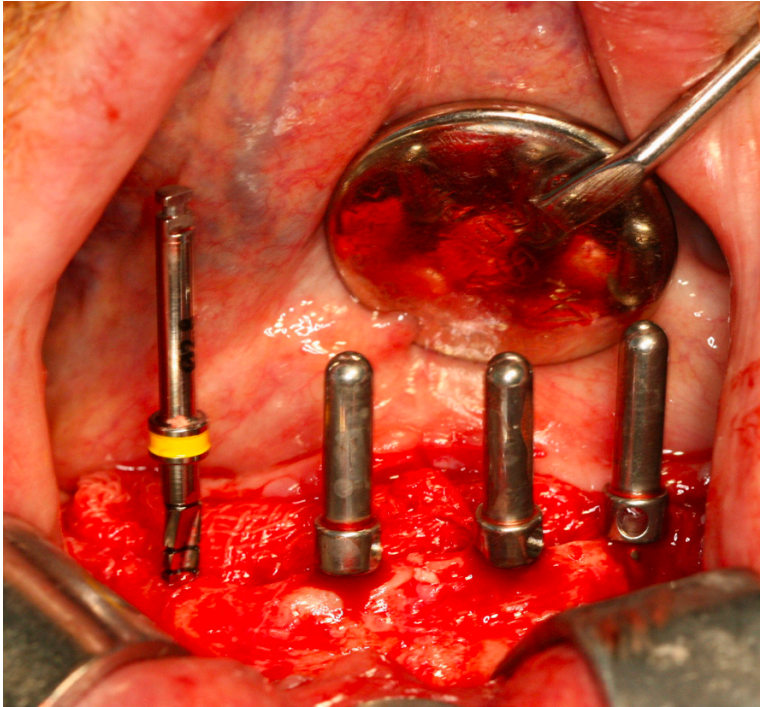
In cases where the alveolar bone width and / or height is insufficient, different reconstruction techniques are used depending on the defect size. For the treatment of alveolar atrophy and bone defects, autogenous bone grafts are considered to be the most successful option and are easily obtained from the mouth. Although transplantation of autogenous tissue has some surgical and technical problems, the most important advantage is that fresh autogenous grafts contain osteogenic cells and do not cause immunological reactions.

## **BODY**

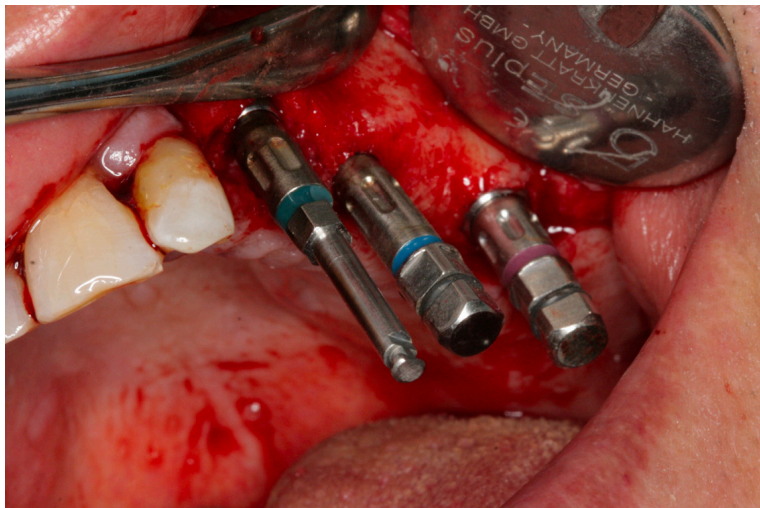
Inadequate bone height and/or width are the most common problems encountered in dental rehabilitation of patients who are totally or partially edentulous. It is essential that ideal relationship be formed between jaws before dental implant surgery. Alveolar crest is one of the most challenging sites of human body in terms of reconstruction, since oral cavity is a moist area and associated with anatomic structures that are always in function (1).

Implant treatment is known to be closely related with the amount of residual alveolar bone and the relationship between jaws (Figure 1-2). Besides these, other possible limiting factors for implant surgery include anatomical properties such as the shape of alveolar bone, position of inferior alveolar nerve, maxillary sinuses and nasal cavity (2).





**Figure 1:** *Implant surgery / lower jaw*



**Figure 2:** *Implant surgery / upper jaw*

Many surgeons on the global scale perform augmentation procedures aimed to increase the volume of atrophic crests for successful implant treatment both functionally and aesthetically. There are 3 objectives of atrophic crest augmentation: to create bone with adequate length and width to

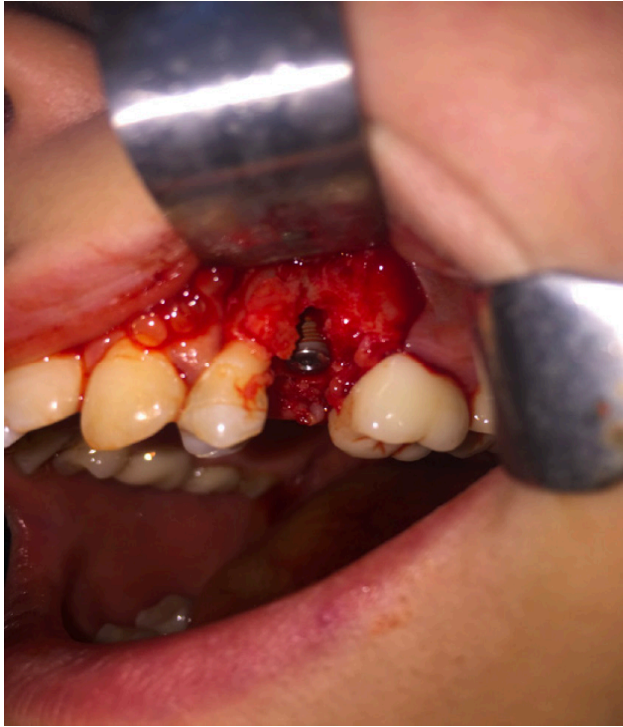allow placement of implant in ideal restorative and functional position; to achieve ideal aesthetic appearance by providing adequate bone support to the soft tissue; and to contribute to the long-term prognosis of the implant (2).

Several reviews reporting treatment outcomes and complications of atrophic crest augmentation techniques; and success rates of augmented areas, implants and prostheses placed at these sites emphasize that these techniques can be applied safely and effectively (3-5).

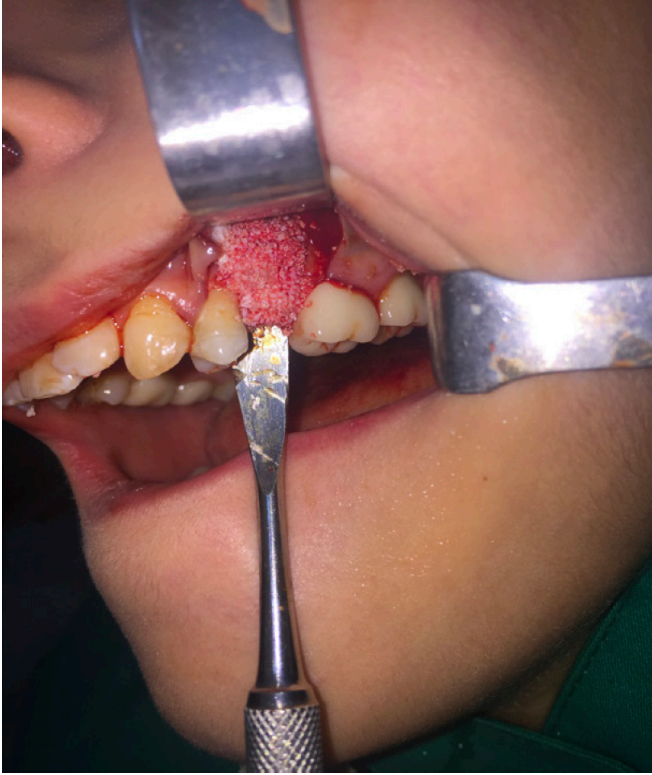Different augmentation techniques are utilized for conditions when alveolar bone width and/or height are insufficient. Decision on the choice of augmentation procedure should be mainly based on the defect size. While small defects are treated with bone splitting and/or guided tissue regeneration, allografts or xenografts; large defects can be successfully treated with alveolar distraction osteogenesis (ADO) inlay or onlay grafting techniques using autogenous grafts obtained from outside the mouth such as iliac, tibial, scapular or calvarial regions, or from inside the mouth such as ramus, symphysis or tuber area (2).

**A brief guidance on the choice of technique is presented below:**


For horizontal bone augmentation, if the crest width is more than 4 mm, and only a small dehiscence is expected as a result of implant placement, it is recommended that implant is placed at the same time with guided bone regeneration (GBR) (6) (Figure 3 a,b,c).



**Figure 3a:** *Buccal dehiscence after implant insertion.*

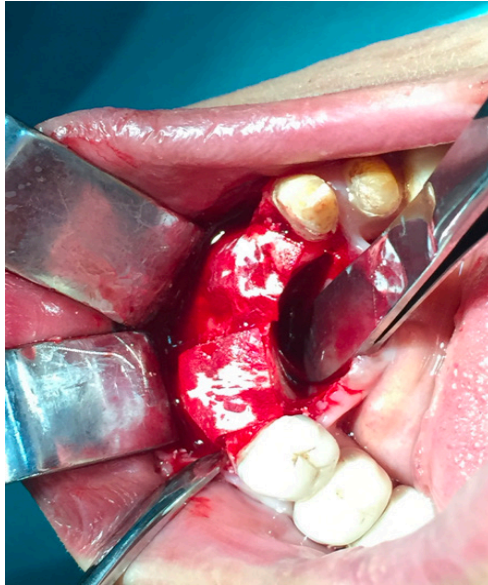

**Figure 3b:** *Applying bone graft, simultaneously with implant insertion*



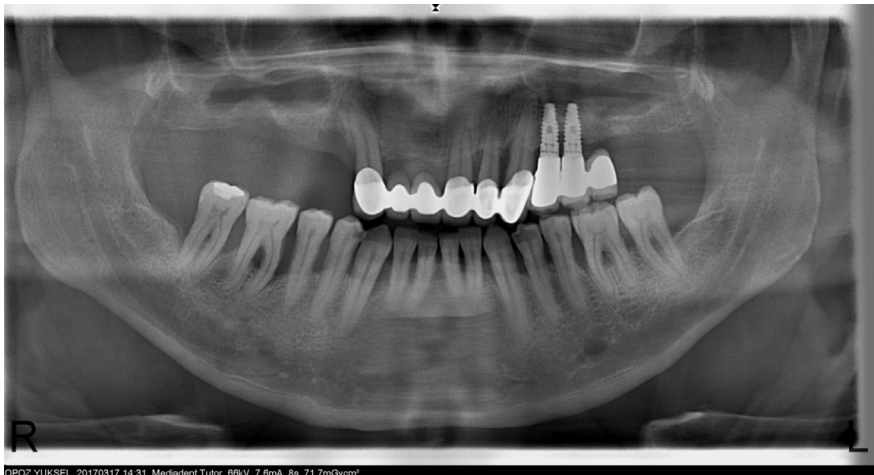**Figure 3c:** *Collagen Membrane for Guided bone regeneration for augmented buccal side.*

If alveolar crest width is smaller than 3.5 mm, delayed implant placement is recommended after completion of bone healing following crest augmentation with GBR or autogenous block grafts alone (6) (Figure 4).

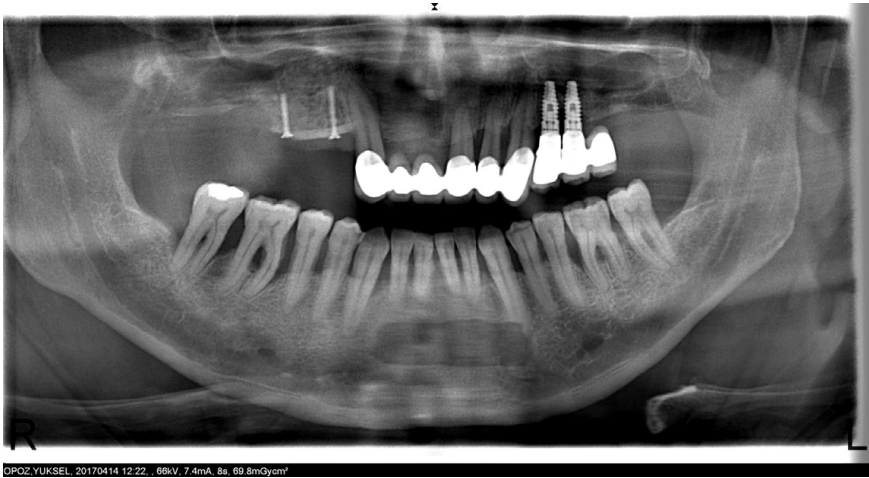

**Figure 4:** *Guided Bone Regeneration for delayed implant insertion.*

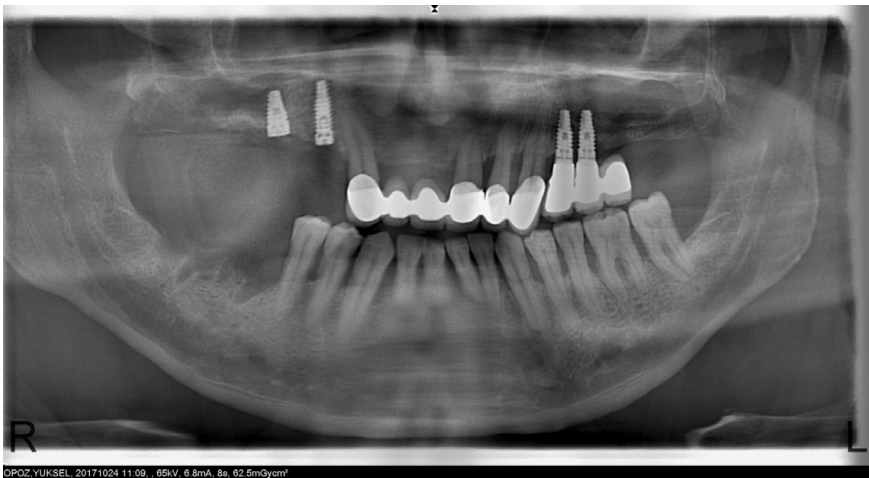For vertical bone augmentation, it is recommended to perform the GBR in defects smaller than 4 mm concurrent with implant placement, whereas two staged implant surgery is appropriate for augmentation of vertical defects larger than 4 mm (6) (Figure 5 a,b,c).



**Figure 5a:** *Vertical deficiency on right posterior upper jaw on preoperative radiograph*



**Figure 5b:** *Postoperative radiograph after intraoral symphysis bone graft augmentation*



**Figure 5c:** *Postoperative radiograph after implants insertion on augmented site.*

Delayed implant placement in vertical augmentation procedure with block grafts was reported to yield 4.7 mm bone acquirement and successful outcomes. Despite these successful results, procedure-related complications are frequent, and advanced clinical experience is required. If vertical bone gain is expected to be greater than 7 mm, ADO is a suitable treatment option. However, this technique has relatively higher complication rate when compared to onlay bone grafting (6,7).

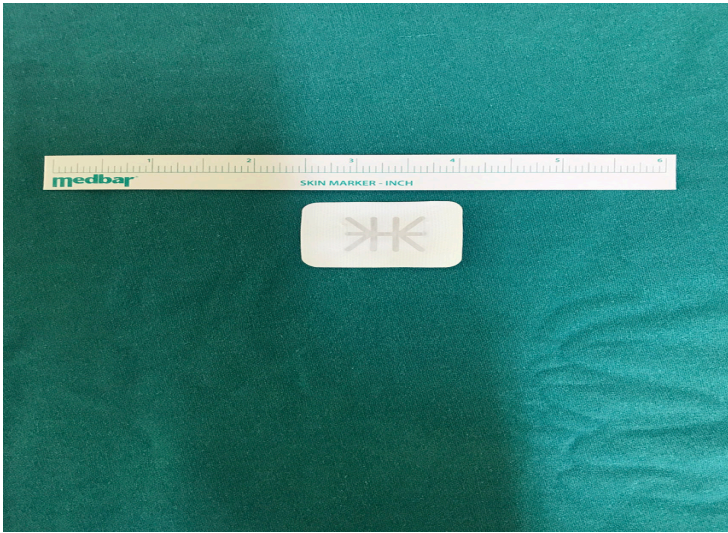
### ***Tips for membrane selection:***

The main obstacle in bone healing and new bone formation is initiation of connective tissue formation before osteogenesis (8). Connective tissue cells move faster than cells with bone production potential, and try to fill the defect area (9). GBR is a membrane technique that was developed with the purpose of allowing passage of only cells with osteogenic capacity to the defect area and preventing rapid connective tissue proliferation. This method is also called as 'membrane-protected bone regeneration (10). Experimental studies indicate that the concept of GBR is successful. New bone is known to be consisting of periosteum and cells of bone marrow origin with osteogenic potential. In this sense, the basic function of the barrier membrane is to provide a suitable environment for a certain time period to allow bone regeneration. Besides acting as a selective barrier for the passage of cells, the membrane also functions to stabilize blood clot and particulate bone graft materials (11).

The intention for membrane placement was considered as; (a) a physical support to prevent the collapse of the overlying soft tissues; (b) creating a space for protection of the granulation tissue and the vascular network during the migration of osteogenic cells; (c) preventing of migration of non-osteogenic cells originating from the overlying soft tissues; and (d) allowing for accumulation of growth factors and other bone-promoting substances (12).

A successful bone augmentation requires preservation of graft integrity. Today, screws, collagen membranes and titanium mesh are widely utilized (4-8) Biomaterials used in the context of GBR technique are divided into two groups as non-resorbable barrier membranes and resorbable barrier membranes (8, 13).

The major disadvantage of non-resorbable membranes such as polytetrafluoroethylene, nano-polytetrafluoroethylene, titanium and titanium-reinforced polytetrafluoroethylene is that these materials have to be removed with a second surgical procedure. This drawback has led the clinicians to develop resorbable membranes (1) (Figure 6). Other disadvantage of non-resorbable membranes is the risk of membrane exposure, which is greater than 31% (13). In case if the dehiscence occurs at the incision line over the barrier membrane, the amount of expected bone formation can reduce by about 60%. This is due to the bacterial contamination of exposed membranes. The biggest advantage of the resorbable membranes is that they do not require a second surgery for their removal. The second advantage is that dehiscence at the incision line is less common, and when it occurs, it is less challenging to handle (14).



**Figure 6:** Non- Resorbable polytetrafluoroethylene membrane

Resorbable membranes are grouped in 3 main categories as collagen membranes, polymeric membranes made of polyactic/polyglycolic acid and cell-free dermal matrix.

Among these, collagen membranes have recently been frequently preferred for their appropriate biological properties. Collagen membranes are generally type 1 and 3, and are produced from cattle or pig. They stop bleeding, they are compatible with the soft tissue, and act as a framework for migrating cells (15).

Taguchi et al. (16) have shown the effect of collagen on osteogenesis. Although the exact mechanism of collagen membrane is not fully clear, the authors reported that it acts as a bed for osteoinductive factors leading to osteogenic differentiation.

In their study including 29 patients, Tawil et al. (17) evaluated the effect of collagen membrane use on graft healing and implant survival. The authors concluded that utilization of membranes improved graft healing and implant survival.

In addition, utilization of collagen also brings other advantages such as weak immunogenicity, hemostasis and fibroblast chemotaxis. The resorption process and barrier function of the material of choice influence the healing of bone graft. In order for a membrane to act as a barrier in GBR procedure, it has to prevent entry of unwanted tissue cells to the bone augmentation site for at least 6-8 weeks. It has been recommended to apply resorbable collagen membrane as in two layers to prevent it from losing its



barrier function at a relatively early period (4-8 weeks) (10). Various methods have been proposed to gain more area when necessary. For instance, non-resorbable membranes reinforced with titanium may be preferred, or screws and pins can be used to support the collagen membrane (11). This procedure is usually called sausage technique (12).

In a retrospective study published by Poly et al., (18) the results of a 12-88 months follow-up of augmentation procedures performed using particulate autogenous bone grafts and titanium mesh, showed a soft tissue dehiscence rate as 8%, implant survival rate as 100%, and amount of bone atrophy as 1.7-1.9 mm.

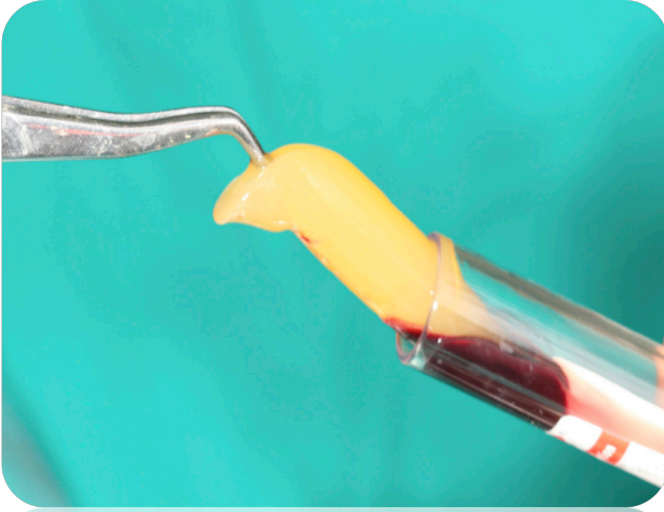
In their systematic review on alveolar ridge reconstruction with titanium mesh, M. Rasia – dal Polo et al. (19) reported rate of dehiscence at soft tissue as 16%, implant survival rate as 100%, and amount of vertical bone acquisition as 4.91 mm.

G. Lizio et al. (20) reported soft tissue dehiscence as 71%, rate of total loss of augmented bone as 24%, and statistically significant atrophy of augmented bone.

M. Rocuzzo (21). published 10-year results of implants placed at the augmented site obtained following vertical augmentation, and reported 94.2% survival, and 0.58 mm vertical bone atrophy.

Another technique that has recently become popular is the open membrane technique developed by Funakoshi (22). In 2005, Funakoshi introduced “Open Barrier Membrane Technique” as novel minimally invasive GBR technique using non-expanded, high-density PTFE (d-PTFE) membrane. Expanded polytetrafluoroethylene (e-PTFE) has been used for guided bone regeneration (GBR) for 20 years. Barrier membranes have such complications as wound dehiscence and membrane exposure that causes infection. Funakoshi et al. (23) claimed that a significant advantage of d-PTFE membranes is impenetrable for bacteria because of its surface characteristics (0.2µm low porosity). Because of this smooth surface, this membrane can be left intentionally exposed and primary closure is not required. Since no primary coverage is necessary, there is no need for periosteal releasing incisions causes swelling and pain.

Another point that requires mentioning in the context of membrane selection in GBR is platelet rich fibrin (PRF), which has been used increasingly common in recent years. Over 15 years ago, PRF was introduced as an autogenous source of blood growth factors that could serve as a tool for tissue regeneration in modern medicine (24). (Figure 7).



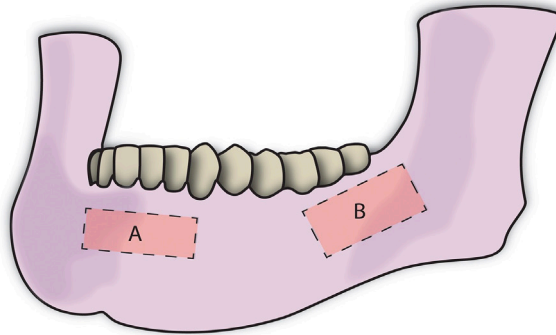
**Figure 7:** *Platelet Rich Fibrin (PRF)*

PRF has been proven to contribute to healing of soft tissue and hard tissue; however, it cannot be an alternative to collagen membrane that is frequently used for GBR. PRF stimulates the vascularization of periosteum and increases the thickness and enhances the quality of the soft tissue over the bone regeneration area (25). Its barrier properties are not as good as collagen membrane, and it resorbs before completion of the bone healing process. However, PRF application over resorbable or non-resorbable membranes during GBR has been reported to have favorable results. Similarly, mixing PRF with particulate synthetic or xenografts in the provides the following benefits to these particulate grafts; major advantages include having completely immune-compatible growth factors collected at relatively no cost without anticoagulants (26-29). While initial and early experiments revealed PRP contained high concentrations of autologous growth factors (up to 6 to 8 times higher than normal blood concentrations), including platelet-derived growth factor (PDGF), vascular endothelial growth factor (VEGF), and transforming growth factor (TGF)- $\beta$ 1, (29) PRF has been shown to release higher total growth factors over a more extended period of time (31). It also boosts the volume of the graft material, and facilitates its manipulation by making it sticky.

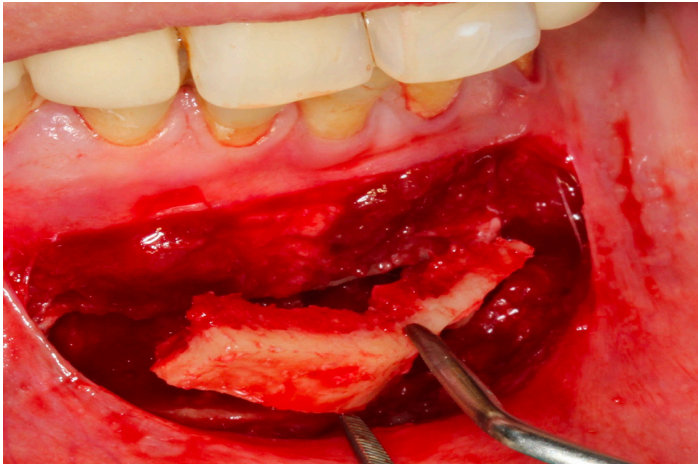
#### **Tips for donor site surgery:**

Mandibular ramus and symphysis areas are the most preferred regions among intraoral donor sites. Mandibular bone grafts have been routinely used for alveolar reconstruction to allow implant placement with short healing time and high favorable results (32). Cortical, cancellous, or cortico-

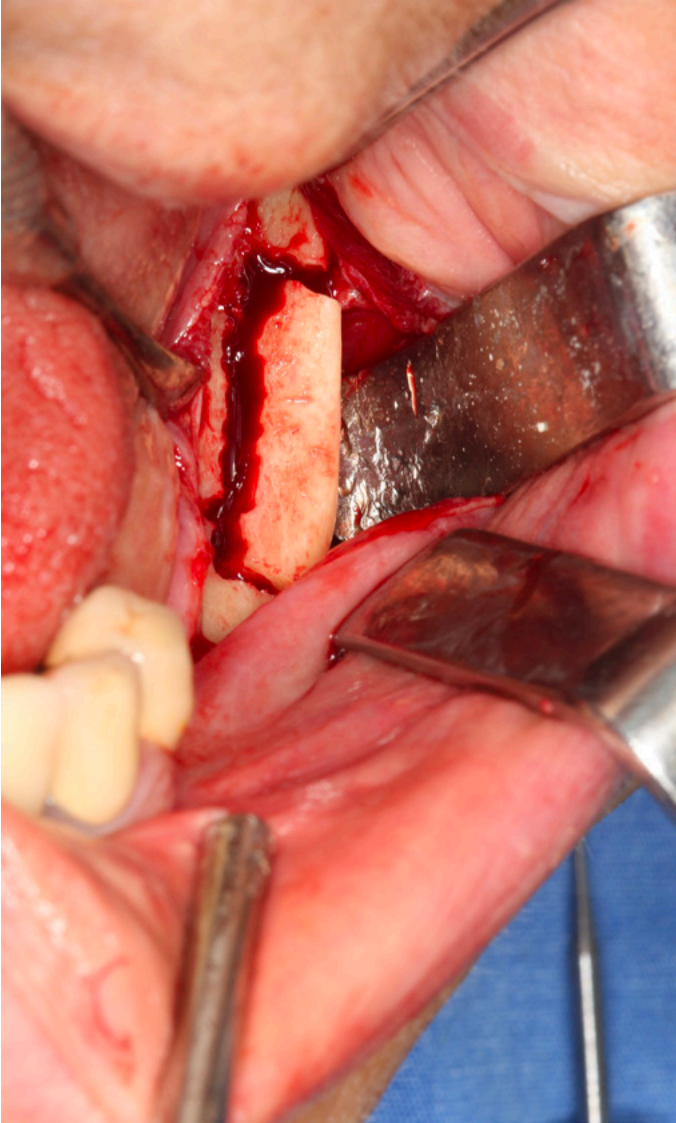
cancellous grafts can be obtained from the symphysis area. The height of the rectangular block graft that can be obtained from this region is  $45,36 \pm 4,82$  mm, width is  $10,31 \pm 2,18$  mm and thickness is  $9,63 \pm 1,10$  mm (33). Higher volume of cortical or corticocancellous graft blocks can be obtained compared to the ramus region (34). Studies suggested that the procedure of harvesting only cortical bone grafts from the ramus has almost zero possibility to damage the mandibular canal. Grafts of rectangular shape with a length of 35 mm, width of 10 mm and thickness of 4 mm can be taken from ramus (33). Intraoral autogenous bone grafts provide advantages such as easy access, low morbidity risk, minimal graft resorption, and no cutaneous scar formation. Studies related bone graft harvesting procedure confirmed the superiority of the ramus area over the symphysis as an intraoral donor site, since it has less associated morbidity (34). (Figure 8 a,b,c)



**Figure 8a:** *Intraoral mandibular autogen graft sources: Mandibular symphysis and ramus.*



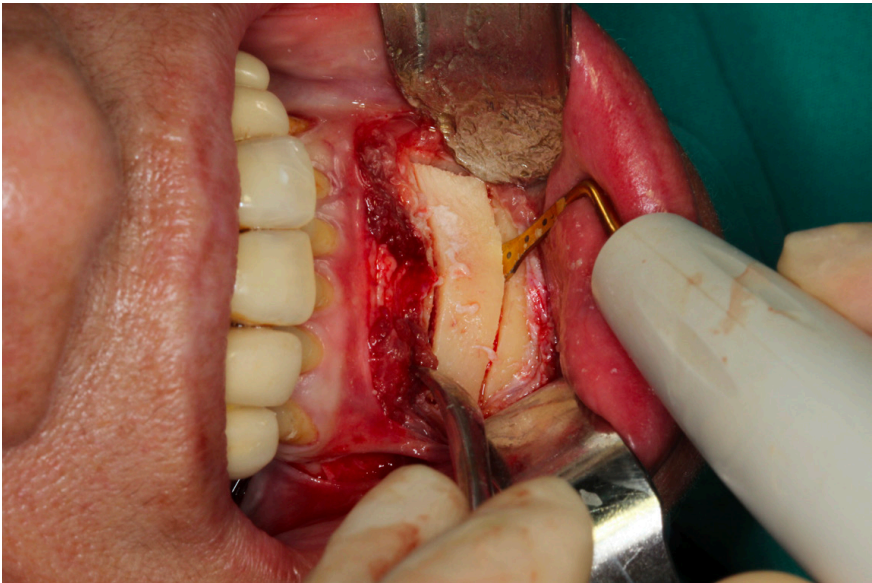**Figure 8b:** *Block graft harvesting from mandibular symphysis*



**Figure 8c:** *Block graft harvesting from mandibular ramus.*

Andersson (35) reported significantly higher paresthesia of the oral mucosa adjacent to the mandibular symphysis bone harvesting site than the mandibular ramus site as assessed with the pointed-blunt test. In another study, block bone grafts obtained from ramus or symphysis were applied to anterior maxilla of 26 patients before dental implant treatment, and postoperative pain and treatment satisfaction at 5th year after operation were compared. It was reported that ramus grafts were associated with higher success rates (35).

The mandibular symphysis donor site showed a higher incidence of minor sensory disturbance of the mucosa and the teeth than the mandibular ramus donor site. The incidence of the temporary paresthesia of the skin and the oral mucosa neighboring symphysis was lower when bone graft was harvested via piezoelectric surgery. The easier and safer alveolar bone harvesting via piezoelectric surgery reduces the morbidity of mandibular donor sites (36) In addition, the loss of vitality of adjacent teeth, and the necessity for root canal treatment were also found lower when symphysis bone graft harvesting is performed by piezoelectric surgery. If the acceptable morbidity rate and the subjective moderate complaints are considered, bone harvesting from the mandibular symphysis remains a good option for the reconstruction of local bone defects. (Figure 9).



**Figure 9:** *Piezoelectric Surgery Device*

Undesirable changes in the lower face esthetics, such as increase in lower incisor exposure, were reported after the bone graft harvesting from mandibular symphysis (37). These changes were attributed to ptosis of the soft tissue surrounding donor sites. Previous studies about the subject focused on graft properties rather than the soft tissue around the surgery site. Similar esthetic problems were also observed after genioplasty operations. Chaushu et. al (37) showed that precise reattachment of the mentalis muscle during genioplasty operation prevented the ptosis of the soft tissue. Altiparmak et al. (38) used the reattachment technique to prevent from the soft tissue problems after bone graft harvesting from mandibular symphysis, which is explained in Chaushu et al's (37) study. Their results indicate

that precise reattachment of mentalis muscle after bone graft harvesting prevents the change in vertical parameters of the soft tissue around mandibular symphyseal area. The increase in lower incisor exposure, which was considered as a major esthetic problem, was also prevented. The authors claimed that it is possible to overcome the negative esthetic effects of the harvesting operation with a simple and reliable method. (38)

#### **Tips for recipient site surgery:**

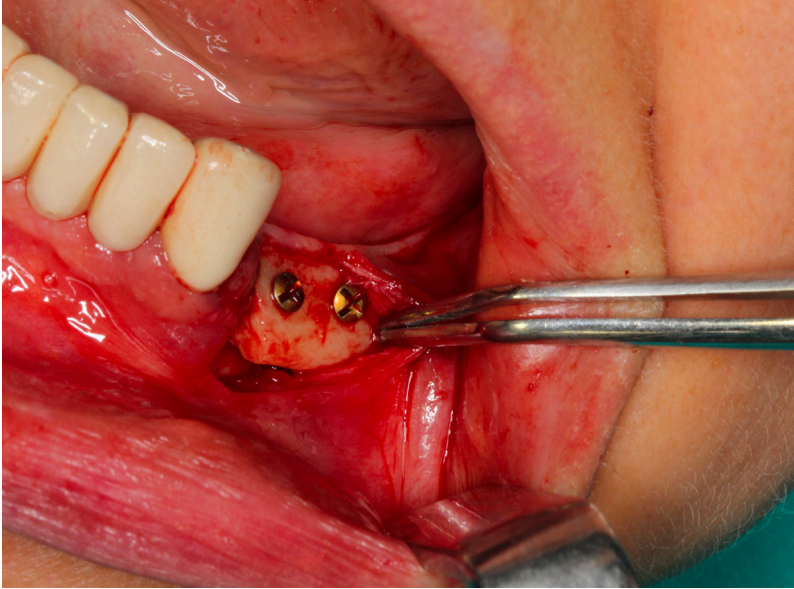
Cortical perforation on recipient site can accelerate bone regeneration because it allows cells migration and increase angiogenic potential of augmentation (39). Several studies recommend to perform cortical perforations at recipient area during augmentation with onlay bone graft to improve bone integration; while, some other studies showing that cortical perforations are not effective in bone regeneration (40,41,42).

Dayangaç et al. (40) performed onlay bone graft augmentation in 7 adult pigs using cortical autogenous bone grafts. Left side of the lower jaws of pigs was assigned to be the experimental group, while right side was assigned to be the control group. In experimental group, cortical perforations were made to the recipient site before graft fixation, whereas in control group, the autograft was fixated without any perforation to the recipient site. After twelve weeks healing period, the pigs were sacrificed and the graft areas were resected. The resected specimens were examined first radiologically, and then histopathologically. In radiological assessments, no significant difference was found between experimental and control groups ( $p>0.05$ ). Histopathological examination revealed significant difference between experimental and control groups with regard to graft thickness ( $p<0.05$ ). Graft thickness was reduced in areas where onlay graft was applied in the cortical perforation group. There was no significant difference between experimental and control groups in terms of remodeling at upper and lower halves of the recipient site, or regarding osteoblastic activity at the grafts ( $p>0.05$ ). According to results of this study it was concluded that cortical perforations created at the recipient site during augmentation with mandibular onlay bone graft did not contribute significantly to bone healing (40).

In literature, most frequently encountered complication at the recipient site following augmentation of localized alveolar defects using block grafts is reported to be dehiscence occurring at the incision line (43). In order to minimize the graft exposure rates and maintain the soft tissue closure several surgical techniques have been developed. The flap design should account for the fact that primary tension free closure will need to be achieved over an increased dimension after the bone graft has been applied to the defect (44).

In recent studies, it is pointed out that this complication is significantly reduced regarding to the modified lingual flap technique (45). A thorough anatomical knowledge is very important to perform this flap after a full thickness mid crestal incision and vertical oblique incisions done, mesiolingually a short 3-4 mm incision is made at the mesiolingual line angle of the most distal tooth in front of the defect. Once the mylohyoid muscle is identified the soft tissue superior to the muscle should be gently pushed lingually using blunt instruments. Lingual flap is carefully separated from the mylohyoid muscle without disturbing any of ascending fibers, In combination with the mini lingual vertical incision the periosteal incision resembles a hockey stick shape (45).

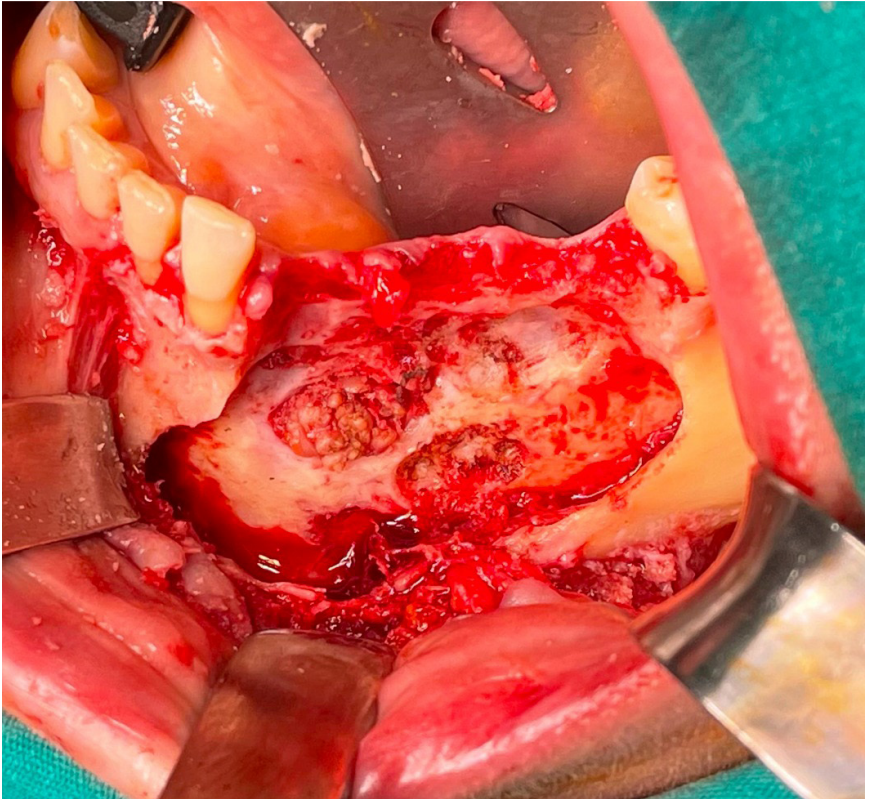
Tunnel incision technique is a minimal invasive technique defined for increasing the success rate of augmentation procedures with autogenous or synthetic bone grafts. Ponte and Khoury (14) reported complication rate of tunnel technique in a case series, including 173 reconstructions with autogenous block grafts. They reported 1 major complication due to flap necrosis and 2 minor complications due to minor exposure of graft. In this case series, low rates of bone graft exposure were related not to use crestal incisions by researchers. A recently published clinical study results showed that tunnel technique significantly decreases soft tissue dehiscence and graft failure. In this prospective clinical study, all patients underwent operations by the same surgeon, performed consecutively using the crestal incision technique (crestal group) or tunnel incision technique (tunnel group). Autogenous bone block grafts were harvested with a piezoelectric surgical device, and the grafts were fixed at the recipient sites by two titanium screws in both two groups. Minor exposure, transient paresthesia, major exposure, permanent paresthesia, gingival recession at adjacent teeth, surgery time, and visual analog scale scores of augmentation procedures were evaluated. A tunnel incision was used in 38 augmentations (27 horizontal, 11 vertical), and a crestal incision was used in 37 augmentations (27 horizontal, 10 vertical). As a Conclusion authors stated that the tunnel technique significantly decreases soft tissue dehiscence and graft failure and minimally invasive tunnel technique can be used as an alternative to the frequently used crestal incision technique (46). (Figure 10).



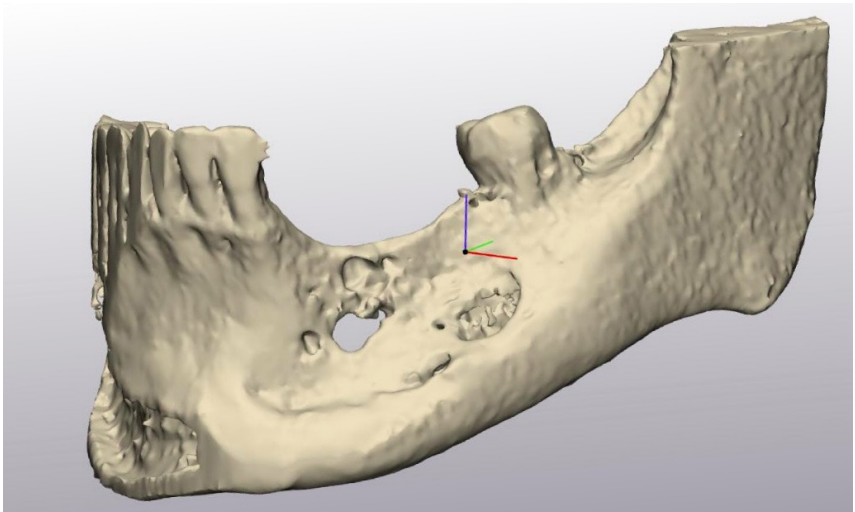
**Figure 10:** *Block graft augmentation through the tunnel incision.*

Recently computer aided designed and manufactured customized titanium meshes have been introduced for the reconstruction of vertical bone defects claiming to increase the prognose predictability of the grafting procedures. Compared to the soft tissue dehiscence rate of 80% with the pre-fabricated meshes, a rate of 25% has been reported. Customized titanium meshes have shown to reduce the post operative complications including deimplantation procedures. With the use of 3D software, the ideal place of the implants is determined and the dimensional evaluation can be made for preplanned implant positions (47) (Figure 11 a,b,c,d).

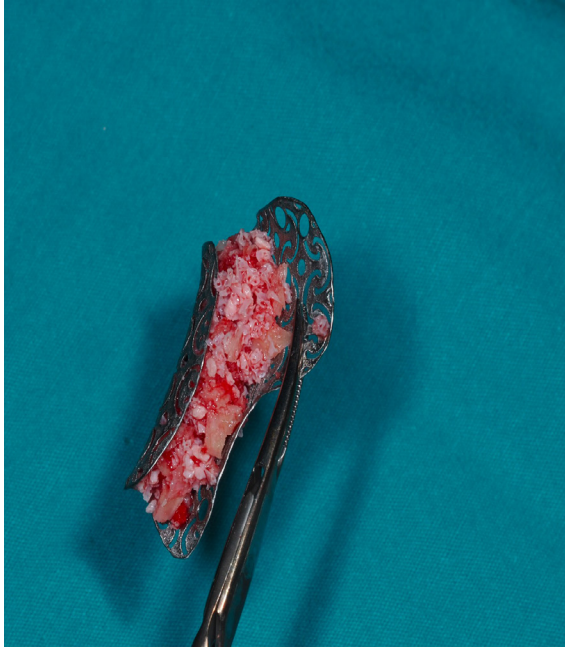



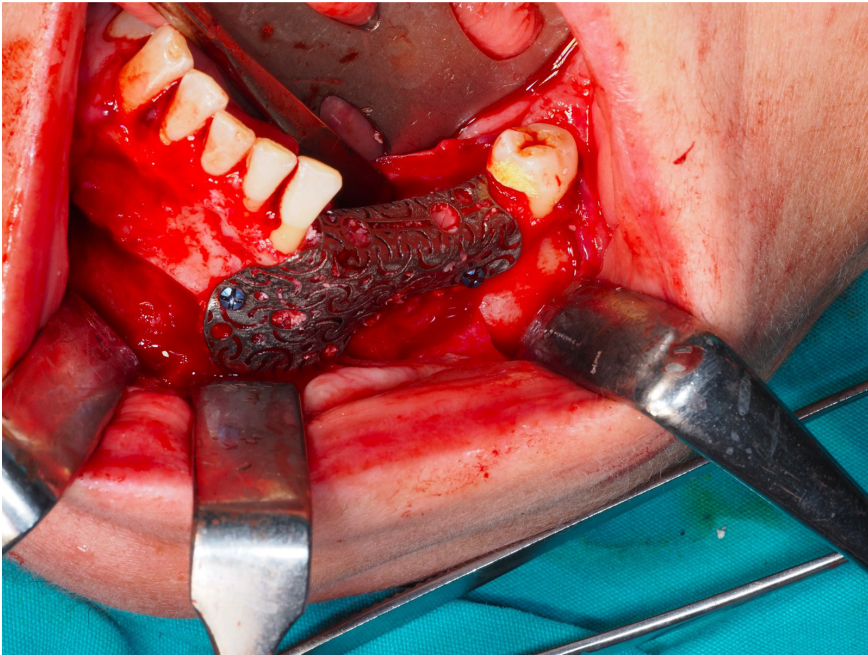
**Figure 11a.** *Defected area after removal of a benign odontogenic tumor*



**Figure 11b.** *Evaluation of the 3D CT model of the surgical site for custom mesh production*



**Figure 11c.** *Custom mesh filled with composite graft material*



**Figure 11 d.** *Adaptation and fixation of the custom mesh*

### **Tips for Further Clinical Studies**

Schwartz et al. showed that tooth roots reveal a structural and biological potential to serve as alternative autografts for ridge augmentation procedures in an animal study (48). Schwartz et al. also reported a case of alveolar ridge augmentation with the root of upper wisdom teeth. They separated and rigidly fixed the tooth root at the defect site following the removal of cement tissue from the root surface. The gained ridge was 4.5 mm and allowed for a successful implant insertion (49). This novel approach may be further investigated in atrophic ridge augmentations.

### **CONCLUSION**

Intraoral bone grafting to allow implant installation in deficient alveolar ridges is a predictable and reliable technique. Treatment outcomes of atrophic crest augmentation procedures by intraoral bone grafting, success rates of augmented areas, implants and prostheses placed at these sites showed that these techniques can be applied safely and effectively. The most important step in treatment planning is to decide the most effective technique considering all the conditions for the patient.

## REFERENCES

1. Misch CE, Misch-Dietsh, F. (2008). Keys to Bone Grafting and Bone Grafting Materials. Misch CE. Contemporary Implant Dentistry St. Louis, Missouri: Mosby Elseiver p: 839-370
2. Van Den Bergh JPA, Ten Bruggenkate CM, Tuinzing DB. Preimplant surgery of the bony tissues. J Prosthet Dent. 1998; 80: 175-183
3. Jensen SS, Terheyden H. Bone augmentation procedures in localized defects in the alveolar ridge: clinical results with different bone grafts and bone-substitute materials. Int J Oral Maxillofac Implants. 2009; 24: 218-236
4. Chiapasco M, Casentini P, Zaniboni M. Bone augmentation procedures in implant dentistry. Int J Oral Maxillofac Implants. 2009; 24: 237-259
5. Aghaloo TL, Moy PK. Which hard tissue augmentation techniques are the most successful in furnishing bony support for implant placement? Int J Oral Maxillofac Implants. 2008; 23 (1): 56
6. Cordaro L, Terheyden H. Literature Review. In Ridge Augmentation Procedures in Implant Patients A Staged Approach. Cordaro L, Terheyden H. Berlin: Quintessence.2014; p.:9-12
7. Uckan S, Veziroglu F, Dayangac E. Alveolar distraction osteogenesis versus autogenous onlay bone grafting for alveolar ridge augmentation: Technique, complications, and implant survival rates. Oral surgery, oral medicine, oral pathology, oral radiology, and endodontics. 2008; 106: 511-515
8. El-Fayomy S, El-Shahat A, Omara M. Healing of bone defects by guided bone regeneration (GBR): an experimental study. Egypt. J. Plast. Reconstr. Surg.2003; 27 (2): 159-166
9. Dahlin C, Alberius, P., Linde A. Osteopromotion for cranioplasty. An experimental study in rats using a membrane technique. Journal of neurosurgery. 1991, 74: 487-491
10. Bosshard D, Schenk R. Biologic Bases of Bone Regeneration. In 20 Years of Guided Bone Regeneration Implant Dentistry. Buser D. Chicago: Quintessence. 2010; p.:15
11. Cordaro L, Terheyden H. The GBR Principle. In Ridge Augmentation Procedures in Implant Patients. Terheyden L, Cordaro L. Berlin: Quintessence. 2014; p.:31-32
12. Buser D, Urban I, Monje A, Kunrath M F, Dahlin C. Guided bone regeneration in implant dentistry: Basic principle, progress over 35 years, and recent research activities. Periodontology 2000. 2023; 93:9–25. DOI: 10.1111/prd.12539
13. Gottlow J. Guided tissue regeneration using bioresorbable and non-resorbable devices: initial healing and long-term results. J Periodontol. 1993; 64: 1157-1165

14. Khoury F, Antoun H, Missika P. Bone augmentation in oral implantology. New York : Quintessence 2006.
15. Miloro M. Peterson's Principles of Oral and Maxillofacial Surgery. London: BC Decker Inc 2004
16. Taguchi, Y., Amizuka, N, Nakadate, M, Ohnishi, H., Fujii, N., Oda, K., Nomura, S., Maeda, T. A histological evaluation for guided bone regeneration induced by a collagenous membrane. *Biomaterials*. 2005; 26: 6158-6166
17. Tawil, G., Mawla, M. Sinus floor elevation using a bovine bone mineral (Bio-Oss) with or without the concomitant use of a bilayered collagen barrier (Bio-Gide): a clinical report of immediate and delayed implant placement. *Int J Oral Maxillofac Implants*. 2001; 16: 713-721
18. Pier PP, Mario B, Marco C, Carlo M. Alveolar Ridge Augmentation with Titanium Mesh. A Retrospective Clinical Study *Open Dent J* 2014; 29: 148-158
19. Rasia-dal Polo M, Poli PP, Rancitelli D, Beretta M, Maiorana C. Alveolar ridge reconstruction with titanium meshes: a systematic review of the literature *Med Oral Patol Oral Cir Bucal*. 2014; 19(6): 639-46.
20. Lizio G, Mazzone N, Corinaldesi G, Marchetti C, Reconstruction of Extended and Morphologically Varied Alveolar Ridge Defects with the Titanium Mesh Technique: Clinical and Dental Implants Outcomes. *Int. J. Periodontics Restorative Dent*. 2016; 36: 689-697
21. Rocuzzo M, Angelis ND, Bonino L, Aglietta M. Ten-year results of a three-arm prospective cohort study on implants in periodontally compromised patients. Part 1: implant loss and radiographic bone loss. *Clinical Oral Implants Researc* 2010; 21: 490-496
22. Funakoshi E, Yamashita M, Maki K, Kage W, Ishikawa Y, Shinichiro H Guided Bone Regeneration with Open Barrier Membrane Technique. 2007, AO 22nd Annual Meeting
23. Motofumi Yamashita, Shinichiro Horita, Noriaki Takei, Yuya Sasada, Wakaho Shibato, Yuko Ishikawa, Kousuke Takao, Koji Maki, and Eiji Funakoshi Minimally Invasive Alveolar Ridge Preservation/Augmentation Procedure (Open Barrier Membrane Technique) Funakoshi Research Institute of Clinical Periodontology, Fukuoka, Japan.
24. Choukroun J, Adda F, Schoeffler C, Vervelle A. Opportunities in implant dentistry: PRF (in French). *Implantodontie* 2001; 42: 62.
25. Wang X, Zhang Y, Choukroun J, Ghanaati S, Miron RJ. Effects of an injectable platelet-rich fibrin on osteoblast behavior and bone tissue formation in comparison to platelet-rich plasma. *Platelets*.2018;29:48-55.
26. Medina-Porqueres I, Alvarez-Juarez P. The efficacy of platelet-rich plasma injection in the management of hip osteoarthritis: A systematic review protocol. *Musculoskelet Care* 2016; 14:121-125.

27. Salamanna F, Veronesi F, Maglio M, Della Bella E, Sartori M, Fini M. New and emerging strategies in platelet-rich plasma application in musculoskeletal regenerative procedures: General overview on still open questions and outlook. *Biomed Res Int* 2015; 2015:846045.
28. Albanese A, Licata ME, Polizzi B, Campisi G. Platelet rich plasma (PRP) in dental and oral surgery: From the wound healing to bone regeneration. *Immun Ageing* 2013;10:23.
29. Panda S, Doraiswamy J, Malaiappan S, Varghese SS, Del Fabbro M. Additive effect of autologous platelet concentrates in treatment of intrabony defects: A systematic review and meta-analysis. *J Investig Clin Dent* 2016; 7:13-26.
30. Peerbooms JC, van Laar W, Faber F, Schuller HM, van der Hoeven H, Gossens T. Use of platelet rich plasma to treat plantar fasciitis: Design of a multi centre randomized controlled trial. *BMC Musculoskelet Disord* 2010; 11:69.
31. Kobayashi E, Flučnikiger L, Fujioka-Kobayashi M, et al. Comparative release of growth factors from PRP, PRF, and advanced-PRF [published online ahead of print January 25, 2016]. *Clin Oral Investig*. doi:10.1007/ s00784-016-1719-1.
32. Clavero J, Lundgren S. Ramus or chin grafts for maxillary sinus inlay and local onlay augmentation: comparison of donor site morbidity and complications. *Clinical implant dentistry and related research*. 2003; 5: 154-160
33. Güngörmüş M, Yılmaz AB, Ertas Ü, Akgül HM, Yavuz MS, Harorli A. Evaluation Of The Mandible as an Alternative Autogenous Bone Source for Oral and Maxillofacial Reconstruction. *J. Int. Med. Res*. 2002; 30: 260-264
34. Bernard GW. Healing and Repair of Osseous Defects; *Dental Clinics of North America*. 1991; 35(3): 469-77
35. Andersson L. Patient self-evaluation of intra-oral bone grafting treatment to the maxillary frontal region. *Dental Traumatology: Official publication of International Association for Dental Traumatology*. 2008; 24: 164-169
36. Altıparmak N, Soydan S, Uçkan S The effect of conventional surgery and piezoelectric surgery bone harvesting techniques on the donor site morbidity of the mandibular ramus and symphysis. *Int J Oral Maxillofac Surg*. 2015; 44(9):1131-7.
37. Chaushu G., Blinder, D., Taicher S., Chaushu S. The effect of precise reattachment of the mentalis muscle on the soft tissue response to genioplasty. *J. Oral Maxillofac. Surg*. 2001; 59: 510-516
38. Altıparmak N, Akdeniz BS, Akdeniz SS, Uçkan S. Changes in the lower lip soft tissue after bone graft harvesting from the mandibular symphysis *Int J Oral Maxillofac Surg*. 2017 ; 46(1): 129-133.
39. Buser D, Dula, K, Belser UC, Hirt HP., Berthold H. Localized ridge augmentation using guided bone regeneration. II. Surgical procedure in the mandible.

The International journal of periodontics & restorative dentistry 1995;15: 10-29

40. Dayangac E, Araz K, Oguz Y, Bacanli D, Caylak B5, Uckan S. Radiological and Histological Evaluation of the Effects of Cortical Perforations on Bone Healing in Mandibular Onlay Graft Procedures. *Clin Implant Dent Relat Res.* 2016; 18(1): 82-8.
41. Lundgren AK, Lundgren D, Hammerle CH, Nyman S, Sennerby L. Influence of decortication of the donor bone on guided bone augmentation. An experimental study in the rabbit skull bone. *Clin Oral Implants Res.* 200; 11: 99-106
42. Jorge RS, Jorge J, Luz JG. Reconstruction of a mandibular critical-sized defect using iliac graft in rats. *Implant Dent.* 2006; 15: 282-289
43. Von Arx T BD. Horizontal ridge augmentation using autogenous block grafts and the guided bone regeneration technique with collagen membranes: a clinical study with 42 patients. *Clin Oral Implants Res.* 2006; **17 (4)**: 359-36
44. Wang HL, Boyapati L. "PASS" principles for predictable bone regeneration. *Implant Dent.* 2006; 15:8-17.
45. Urban I, Traxler H, Romero-Bustillos M, et al. Effectiveness of two different lingual flap advancing techniques for vertical bone augmentation in the posterior mandible: a comparative, split-mouth cadaver study. *Int J Periodontics Restorative Dent.* 2018; 38:35-40.
46. Altiparmak N, Uckan S, Bayram B, Soydan S. Comparison of Tunnel and Crestal Incision Techniques in Reconstruction of Localized Alveolar Defects. *Int J Oral Maxillofac Implants.* 2017; 32(5): 1103–1110.
47. Li L, Wang C, Li X, Fu G, Chen D, Huang Y. Research on the dimensional accuracy of customized bone augmentation combined with 3D-printing individualized titanium mesh: A retrospective case series study *Clin Implant Dent Relat Res.* 2021; 23:5–18. DOI: 10.1111/cid.12966
48. Schwarz F, Golubovic V, Mihatovic I, Becker J. Periodontally diseased tooth root used for lateral alveolar ridge augmentation. A proof-of-concept study. *J Clin. Periodontol* 2016; 43: 797–803.
49. Schwarz F, Schmucker A, Becker J. Initial case report of an extracted tooth root used for lateral alveolar ridge augmentation. *J Clin Periodontol.* 2016 Nov;43(11):985-989.





# BÖLÜM 2

## EVALUATION OF FILLING APPLICATIONS, TECHNIQUES, COMPLICATIONS AND BASIC PRINCIPLES IN THE FACE AREA

*Hüseyin Tutku BEKAR<sup>1</sup>*

*Sinan Yasin ERTEM<sup>2</sup>*

---

1 Araştırma Görevlisi, Ankara Yıldırım Beyazıt Üniversitesi Diş Hekimliği Fakültesi Ağız, Diş ve Çene Cerrahisi ABD, e-mail: huseyintutkubekar@aybu.edu.tr , Orcid: 0009-0008-6629-5768

2 Doçent Doktor, Ankara Yıldırım Beyazıt Üniversitesi Diş Hekimliği Fakültesi Ağız, Diş ve Çene Cerrahisi ABD. e-mail: syertem@ybu.edu.tr , Orcid: 0000-0002-8217-9889

## **Introduction**

In today's world where cosmetic developments are constantly advancing, individuals who have various aesthetic expectations and want to solve these expectations in a non-surgical way are turning to non-surgical medical procedures that offer natural-looking results and fast recovery time. Among these procedures, the use of facial fillers has gained significant popularity and has become an attractive treatment option for those who aim to rejuvenate and beautify their facial features. Hyaluronic acid, a substance found naturally in the body, has given effective results in dermal filler applications due to its natural occurrence in human skin, its high ability to adhere to water, its low side effects, and its ability to maintain moisture and elasticity of the skin, and has found widespread use in the field of medical aesthetics.

HA (Hyaluronic Acid), a fundamental element of the extracellular matrix, is naturally present in tissues as a biopolymer. Hyaluronic acid is a glycosaminoglycan that is composed of repetitive disaccharide units of D- N-acetylglucosamine and D-glucuronic acid. The body degrades non-cross-linked HA chains rapidly. Enzymes like hyaluronidase and free radicals naturally occurring in the tissue can decompose non-cross-linked HA polymers quickly and can break large sections of polymer chains at a rapid rate. As a consequence, its half-life is one to two days in tissue, where it suffers aqueous dilution and then in the liver undergoes enzymatic degradation to carbon dioxide and water (1). For this reason, non-crosslinked HA filler preparations do not achieve the permanence required for a dermal filler (2). In addition, the fluidity of the appropriate filler to be used varies according to the areas to be filled. For example, high-viscosity products (high G' fillers) are an appropriate choice in a large atrophic cicatrix or nasolabial sulcus. Low viscosity products (low G' fillers) are more suitable in thin areas such as around the eyes and mouth or for correction of superficial lines.

## **Face Filling Application Areas - Basic Principles**

In this developing field of medical aesthetics, the practitioner must have sufficient theoretical and practical knowledge. Complications reported from injections of facial fillers included tissue loss due to necrosis, erythema, paralysis, blindness, and possibly even death. The most serious complications are usually caused by accidental injury to the vessels or intravenous injections.

There are general principles that should be applied for safe filler injections. These are;

1. It is better to use fillers that can be reversible (e.g. hyaluronic acid)
2. It is recommended to use a small needle (27 Gauge or smaller)
3. The use of a cannula in risky areas allows for a safer application.
4. It is recommended to use an anterograde/retrograde injection technique, keeping the syringe in constant motion.
5. It is safer to use small syringes (0.5-1 cc) and to proceed with small injections in a controlled manner.
6. It is necessary to inject the filler with low pressure. Injections requiring high pressure may indicate dangerous areas or inappropriate injection sites.
7. It is recommended to be very careful when applying fillers to areas with previous trauma/scarring or to avoid these areas.
8. The anatomical map of the area to be filled should be mastered.
9. A filler rescue kit should always be available (e.g. nitroglycerin ointment, acetylsalicylic acid, hyaluronidase)

If intravenous injection is given, a pre-planned protocol should be activated immediately (3);

1. Stop the injection.
2. Inject hyaluronidase under the dermis in the affected area; 100 units or more may be required.
3. Acetylsalicylic acid can be given orally.
4. Massage the area to disperse the remnants of the filling material.
5. A warm compress should be applied.
6. Sildenafil (Viagra) may be considered for vasodilation.
7. Nitropaste application to the affected area may be considered.
8. The patient should be closely monitored and more hyaluronidase should be injected if necessary.
9. Hyperbaric oxygen therapy may be considered if there is a risk of tissue loss.
10. Antibiotics or steroids are not indicated.

If visual impairment occurs, an ophthalmologist should be notified immediately and retrobulbar hyaluronidase injection should be considered within 1 hour.

## **Eyebrow- Glabellar Region**

### **Anatomy**

The corrugator muscle starts from the nasal process of the frontal bone, runs superolaterally below the frontalis, and is located in the dermal region of the eyebrow. The contraction of this muscle over time causes vertical lines along the eyebrow line. A branch of the ophthalmic artery, the supratrochlear artery arises from the superomedial artery 17 to 22 mm lateral to the median line, pierces or passes superficially through the corrugator muscle, and is located deep to the frontalis and orbicularis (4-5). At about 15 to 25 mm from the orbital ridge, the artery crosses the frontalis and orbicularis and enters the subcutaneous plain (4). It runs superior to the subcutaneous plain in the paramedian position 15 to 20 mm from the center line (6). Vertically, the supratrochlear artery lies at the level of the eyebrow, plus or minus 3 mm from the medial canthus (7).

### **Basic Principles**

In the nasoglabellar region, supratrochlear, supraorbital, angular, and dorsal nasal arteries anastomose. Considering this network, it would not be too surprising if an accidental intravascular injection spreads to the ophthalmic artery. After exiting the orbita, the arteries rapidly superficialize, especially near the supratrochlear artery and frown lines (8). In this region, dermal injections are performed into the wrinkles with low-viscosity filler using a serial puncture technique. During injection into the eyebrow zone, one should apply digital pressure to occlude the supratrochlear and supraorbital vessels across the edge to avoid backflow in case of accidental injection of the dermal filler. Superficial injection in this area is extremely important. The vessels can be easily ruptured with the wrong technique and can be compressed by the neighboring filler due to their small size. Intravenous injection into this region may cause visual loss and/or necrosis of the tissue. In many investigations, the glabella is the most frequent site of injection of fillers causing loss of vision.

## **Temporal Region**

### **Anatomy**

A. temporalis superficialis: the terminal branch of the a. carotis externa. It superficializes just above the apex of the eyebrow on the upper edge of the zygomatic bone, and the a. temporalis superficialis enters between the two leaves of the temporoparietal fascia, giving off parietal and frontal branches. The a. temporalis superficialis runs within the temporoparietal fascia immediately under the subcutaneous adipose tissue, where the vein

is more superficial than the artery. In a cadaveric model, the artery origin of the frontal branch of the superficial temporal artery was located on a mean 17.2 mm anterior and 36.9 mm superior to the tragus tip (9). In this study, the researchers identified the danger zone as starting from 3.0 mm superior and 2.5 mm lateral to the apex of the eyebrow and suggested that this zone should be digitally pressurized when injected into the temporal fossa (9). The middle temporal vein lies approximately 2 cm superior and in parallel to the zygomatic arcade (10).

### **Basic Principles**

Embolic events occur when filler introduced into the artery spreads into the supra-orbital system or when the filler passes retrogradely to the system of the main superficial temporal artery. Both may cause blindness. The filler should not be injected at intermediate depths in the tissue, as it can become almost impossible to distinguish which tissue layer it has been inserted into. The use of a cannula should be strongly considered to reduce the possibility of venipuncture. Rotating the patient's head to the medial side will help to distinguish the superficial veins, which can be avoided later on. The filler can then be applied by massaging around the veins. Although not a highly recommended method, the filler can also be injected deeply at the pre-periosteal level.

If deep filler injections are to be made into the temporal fossa, they must be in the pre-periosteal position. The middle temporal vein passes parallel to and about 2 cm superior to the zygomatic arch. Therefore, injections should be made one finger width or at least a few centimeters above the zygomatic arch. In the pre-periosteal plane, a greater amount of high-viscosity filler will be required to make the results superficially visible. The preferred practice is therefore to inject the filler into the superficial subcutaneous tissue, applying it directly beneath the dermis and applying pressure right above the apex of the eyebrow. The filling material can then be massaged and manipulated to fill in the missing sites. Of course, injections at this level will require a larger amount of filler to superficially make a difference.

### **Infraorbital Region**

#### **Anatomy**

The infraorbital nerve and artery originate from the infraorbital foramen. In general, the infraorbital foramen is situated about one-third of the distance from the medial to the lateral canthus, about 11 mm beneath the infraorbital margin (11,12). It is clinically usually located in the vertical

line of the medial limbus or just lateral to it, slightly less than one finger width below the orbital margin.

### **Basic Principles**

If the infraorbital artery is accidentally damaged during filling application, this may cause embolization of the filling. Damage to the nerve may cause hypoesthesia or hyperesthesia and may result in pain. It is preferable to refrain from direct deep injection into this region and only inject laterally. More medial injections approaching the medial canthus should be avoided altogether. If filler is required in this area, it can be injected laterally and pushed medially.

### **Upper Lip**

#### **Anatomy**

The point where the facial artery branches into the superior labial artery is on average 10.4 to 12.1 mm lateral and approximately 43 degrees superior to or 5 to 9 mm above the corner of the mouth (13,14). Subsequently, the superior labial artery usually courses superior to the vermilion margin and then crosses the margin inferiorly just before converging on Cupid's bow. On the lateral side, the artery usually crosses above the vermilion line of the lip. However, as the artery crosses Cupid's bow, it may be 1 to 4 mm below the vermilion line (14). In the upper lip, the superior labial artery is 3 to 7.6 mm under the skin, generally running between the musculus orbicularis and the oral mucosa, or more rarely within the musculus orbicularis (13,14).

### **Basic Principles**

The patient's expectations should be well analyzed before the injection. The required touch on the lip may be to increase the volume. It may be the clarification of the vermilion-cutaneous border. Or it may be a combination of both procedures. In this case, younger patients usually have sufficient volume in their lips but want the vermilion-cutaneous border to be defined. Older patients or patients with thin lips will want a significant increase in lip volume. In this case, vermilion-cutaneous enhancement may also be required. This is a matter that can be decided according to the patient's anatomical condition and wishes. In general, injections are performed at a depth of less than 3 mm utilizing a soft filler with a medium or low G' filler. These low-viscosity fillers are more easily dispersed and thereby reduce the frequency of unevenness (14). As the needle will be much nearer to the artery in the medial part than laterally, it is critical to

superficially inject. Similarly, the small septal branches from the superficial labial artery on the orbicularis may cross in this area (14).

## **Commissures**

### **Anatomy**

The facial artery has been observed to extend beneath the musculus zygomaticus major and musculus risorius muscles and 12 to 15.5 mm distal to the commissure (14,15,16,17). The area covering the origin of the facial artery and superior labial artery can be estimated clinically by placing the thumb near the commissures (14).

### **Basic Principles**

When injecting into the lip commissures, a cross-hatching technique is recommended by blocking the superior labial artery origin (18). Filler injection into the commissures provides a more youthful appearance by pulling up the corner of the mouth.

## **Lower Lip**

### **Anatomy**

The inferior labial artery is an artery that shows many variations. In general, it originates from the facial artery and passes between the mucosa and the lower part of the musculus orbicularis oris. As the labial arteries cross the lips, they will anastomose with the labial arteries on the opposite side. The anastomosis creates a lateral blood supply for the lips and underlying muscles. At the level of the vermilion-cutaneous line, the inferior labial artery is 6.4 to 7.1 mm from the anterior border, 5.9 to 9.4 mm from the superior border, and 4.4 to 4.8 mm from the posterior border of the lower lip (19,20).

### **Basic Principles**

Lower lip injections should be performed with medium or low-viscosity filler materials at a maximum depth of 3 mm, either at the cutaneous line of the vermilion or in the dry vermilion (19,20). The inferior labial artery is usually located at the mucosal-muscular intersection and posterior to the upper border of the lip. Inadvertent injections of intravascular filler into this region may lead to complications such as necrosis of the tissue.

## **Nasolabial Fold**

### **Anatomy**

In general, the facial artery continues superiorly contiguous to the nasolabial fold and branches into the superior labial artery near the commissure. In the ala nasi level, the facial artery branches to form the inferior alar artery and just above it the lateral nasal artery and continues as the angular artery. The facial artery is located approximately 3.2 mm distal to the most lateral point of the nasal ala. (21,22) The facial artery runs approximately 1.7 - 0.3 mm medial to the nasolabial fold (22).

### **Basic Principles**

When filling the nasolabial fold, it would be more appropriate to use a cannula considering its closeness to the facial artery and its possible location in the subcutaneous tissue. It is necessary to place the filler inside the nasolabial fold or just medial to it. If it remains lateral, it may cause the fold to seem deeper and may give an older appearance. To reduce the possibility of bleeding intravascularly, the injection needle or cannula must be in continuous motion. Moving cannula along the nasolabial fold to break tissue adhesions will also give a better result. If the facial artery or its branches are damaged during applications in this area and the filler is introduced intravenously, it may cause alar and/or cheek necrosis. Also, this area is a route of ocular embolism in anastomoses with the angular artery and dorsal nasal branches. Nasolabial fold fillers were the second most common injection site for tissue necrosis (23). Nasolabial fold fillers are the third most frequent location for vision loss (24).

## **Nose**

### **Anatomy**

Before its transformation into the angular artery, the facial artery gives off the branch of the inferior alar artery and the branch of the lateral nasal artery. In the subdermal layer at the tip of the nose, the dorsal nasal artery, lateral nasal arteries and columellar artery form a network of rich vessels. In the areolar layer beneath the muscular layer, there is sparse vasculature except for the “deep” or “lateral nasal veins” that extend cephalically to the lateral crura (25).

### **Basic Principles**

Injections in the nasal region are prone to complications due to the anatomical structure and require caution. Nasal filler injections are the most common cause of tissue necrosis (23). Considering the shallow stru-



cture of the vascular system in the nose, an incorrect injection may cause undesirable results. Injections that compress or injure superficial vessels in the nasal tip and the alar facial groove may cause necrosis in these areas. In addition, given the anastomosis of the ophthalmic artery with the tip, dorsal, and lateral wall vessels, any intravascular injection in these regions may lead to the retrograde spread of the filler, causing ocular ischemia and vision loss. Nasal fillers are reported to be the second most common cause of blindness after glabella fillers (24).

## **Chin and Jawline**

### **Anatomy**

The mental and submental arteries, branches of the inferior alveolar artery and facial artery, feed the jaw. Mental nerve supplies the jaw and lower lip with sensory innervation; which usually arises from the mental foramen beneath the apices of the first and second mandibular premolars. Special attention must be given to facial artery and the marginal mandibular branch of the facial nerve, as these pass superficially on the mandibular margin just anterior to masseter muscle.

### **Basic Principles**

Injections in the chin area vary according to the indications. In this section, the points to be considered according to the indications will be emphasized.

#### **a. Mental Wrinkle**

Labiomental or mental wrinkle is a line on the horizon that forms just over the chin during aging. These wrinkles are caused by loss of volume of soft tissue, decreased elasticity of the skin, dermal atrophy, hyperdynamic muscle contractions of lower facial muscles, and underlying mandibular bone resorption (25). Care must be taken to avoid sublabial artery and vein during filler application. Superficial subcutaneous filler injection should be performed with a linear retrograde technique. Alternatively, if starting from the lateral side, injection can be performed with a linear anterograde technique. Injections should be done slowly and under control. The amount of filler given should be checked after each injection and over-injection should be avoided, as over-injection may cause irregularities.

#### **b. Marionette Lines**

The marionette lines give the face a sad or harsh appearance. Filler application is applied to two areas on each side. Care must be taken to prevent inferior labial artery and sublabial arteries and veins. A superficial

injection should be made using a linear retrograde technique. It is recommended to inject the filler slowly into the medial part of the marionette line, giving the majority of the filler volume to the upper third of the line. Upper point injection of the marionette line is done by slowly injecting the needle using the vertical column technique, where the needle is inserted inferior to the modiolus, injected into the deeper tissue and then injected with filler that is withdrawn.

### **c. Chin Tip**

An indented protruding chin is undesirable aesthetically; augmentation improves the visibility of the chin and roundness (25). Care must be taken when injecting the filler to prevent mental artery and mental vein. For the initial injection, it is necessary to determine the midline of the jawline, locate the needle in the midline, aspirate slowly, and inject the filler slowly. The jaw should be gently squeezed with two fingers to prevent the filler from flowing into the unwanted area. The injection is done supraperiosteal. When filling, it is necessary to compare the symmetry before and after injection. It is necessary not to cause asymmetry by keeping the injection in the midline. It is recommended not to inject the filler too low because this practice may cause the “witch’s jaw” formation. Excessive injection should be avoided and proceed in a controlled manner. After the injection, massage should be performed to ensure a homogeneous distribution of the filler. The other two injections should be made in the superiolateral areas on both sides of the midline, paying attention to the mentioned points.

### **d. Prejowl Region**

The Prejowl region is the triangular space extending from the mental foramen to the mid-lateral region of the mandible. Care must be exercised during injection to ensure that mental artery, vein, and mental nerve are avoided. It is necessary to position the needle on the jawline and aspirate the prejowl area before injection of the filler. Insert very gently and guide with the fingers to check the filler placement. To inject filler into the distal parts of the triangular anterior pre-jowl area, a subcutaneous deep injection is made using the fan technique. While injecting slowly, the fingers are used to control the displacement of the filler. Excessive injection lateral to the mandibular ligament can aggravate the prejowl area. Therefore, it is useful to proceed in a controlled manner.

### **e. Mandibular Angle and Body**

Filler injection in this region creates a more pronounced jawline contour and provides a more masculine appearance. Two to three filler injections are made on each side of the mandible. When applying filler, it is

necessary to determine the location of the facial artery, vein, and parotid gland and avoid them. By subcutaneous injection, it is necessary to superficially locate the needle to avoid the facial artery. It would be safer to use a cannula to fill the line at this point.

Supraperiosteal injections are performed with the syringe on the mandibular angle. Before each injection, aspirate slowly and apply the filler slowly and carefully, avoiding scraping the periosteum. One or two small boluses are administered into the mandibular angle for supraperiosteal filler injections. For male patients this is ideal. For female patients, the subcutaneous injection is preferred. The treatment site can be susceptible to the formation of deep hematomas, particularly in the area of supraperiosteal injections.

### **Conclusion**

The field of filler procedures has undoubtedly become one of the most effective branches of aesthetic medicine today, offering people the opportunity to improve their facial features in the direction they want and to address various concerns. Since it is a non-surgical procedure and results are obtained quickly, the number of individuals applying to these procedures is increasing. Although fast and relatively safe results are obtained, it should not be forgotten that filler applications are a medical procedure and each procedure should be planned to protect the patient's health first and then to manage aesthetic concerns. The physician who will perform the application, mastering the anatomy of the injection area, knowing the danger zones, and avoiding them will greatly reduce the risk of complications. It is also the physician's responsibility to recognize fillers, know their side effects and manage complications. With the increase in available fillers, the advancement of techniques, and the constant renewal of aesthetic concerns and trends, this field is dynamic and practitioners need to constantly improve themselves. There is a need for more extensive research on filler applications, especially in the process of excretion from the body, standardization of application techniques and the amount of application of filler materials with objective criteria, thus reducing complications and increasing clinical success.

## REFERENCES

1. Monheit GD, Coleman KM. Hyaluronic acid fillers. *Dermatol Ther.* 2006;19:141–150.
2. Matarasso SL. Practice forum: Understanding and using hyaluronic acid. *Aesthetic Surg J.* 2004;24:361–4.
3. DeLorenzi C. Complications of Injectable fillers, part 2: vascular complications. *Aesthet Surg J* 2014;34: 584–600.
4. Kleintjes WG. Forehead anatomy: Arterial variations and venous link of the midline forehead flap. *J Plast Reconstr Aesthet Surg.* 2007;60:593–606.
5. Webster RC, Gaunt JM, Hamdan US, et al. Supraorbital and supratrochlear notches and foramina: Anatomical variations and surgical relevance. *Laryngoscope* 1986;96:311–315.
6. Shumrick KA, Smith TL. The anatomic basis for the design of forehead flaps in nasal reconstruction. *Arch Otolaryngol Head Neck Surg.* 1992;118:373–379.
7. Ugur MB, Savranlar A, Uzun L, et al. A reliable surface landmark for localizing supratrochlear artery: Medial canthus. *Otolaryngol Head Neck Surg.* 2008;138:162–165.
8. Vural E, Batay F, Key JM. Glabellar frown lines as a reliable landmark for the supratrochlear artery. *Otolaryngol Head Neck Surg.* 2000;123:543–546.
9. Lee JG, Yang HM, Hu KS, et al. Frontal branch of the superficial temporal artery: Anatomical study and clinical implications regarding injectable treatments. *Surg Radiol Anat.* 2015;37:61–68.
10. Jung W, Youn KH, Won SY, et al. Clinical implications of the middle temporal vein with regard to temporal fossa augmentation. *Dermatol Surg.* 2014;40:618–623.
11. Canan S, Asim OM, Okan B, et al. Anatomic variations of the infraorbital foramen. *Ann Plast Surg.* 1999;43:613–617.
12. Liu DN, Guo JL, Luo Q, et al. Location of supraorbital foramen/notch and infraorbital foramen with reference to soft- and hard-tissue landmarks. *J Craniofac Surg.* 2011;22:293–296.
13. Mağden O, Edizer M, Atabey A, et al. Cadaveric study of the arterial anatomy of the upper lip. *Plast Reconstr Surg.* 2004;114:355–359.
14. Lee SH, Gil YC, Choi YJ, et al. Topographic anatomy of the superior labial artery for dermal filler injection. *Plast Reconstr Surg.* 2015;135:445–450.
15. Jack F. Scheuer III, David A. et al. Campbell, Andrew A. Gassman, Rod J. Rohrich, Anatomy of the Facial Danger Zones: Maximizing Safety during Soft-Tissue Filler Injections *Plast. Reconstr. Surg.* 139: 50e, 2017.
16. Pinar YA, Bilge O, Govsa F. Anatomic study of the blood supply of perioral region. *Clin Anat.* 2005;18:330–339.

17. Lohn JW, Penn JW, Norton J, et al. The course and variation of the facial artery and vein: Implications for facial transplantation and facial surgery. *Ann Plast Surg.* 2011;67:184–188
18. Scheuer JF 3rd, Sieber DA, Pezeshk RA et al. Facial Danger Zones: Techniques to Maximize Safety during Soft-Tissue Filler Injections *Plast Reconstr Surg.* 139: 1103, 2017.
19. Al-Hoqail RA, Meguid EM. Anatomic dissection of the arterial supply of the lips: An anatomical and analytical approach. *J Craniofac Surg.* 2008;19:785–794.
20. Edizer M, Magden O, Tayfur V, et al. Arterial anatomy of the lower lip: A cadaveric study. *Plast Reconstr Surg.* 2003;111:2176–2181.
21. Nakajima H, Imanishi N, Aiso S. Facial artery in the upper lip and nose: Anatomy and a clinical application. *Plast Reconstr Surg.* 2002;109:855–863.
22. Yang HM, Lee JG, Hu KS, et al. New anatomical insights on the course and branching patterns of the facial artery: Clinical implications of injectable treatments to the nasolabial fold and nasojugal groove. *Plast Reconstr Surg.* 2014;133:1077–1082.
23. Ozturk CN, Li Y, Tung R, et al. Complications following injection of soft-tissue fillers. *Aesthet Surg J.* 2013;33:862–877.
24. Li X, Du L, Lu JJ. A novel hypothesis of visual loss secondary to cosmetic facial filler injection. *Ann Plast Surg.* 2015;75:258–260.
25. Small R. Dermal Filler Procedures. *New York: Wolters Kluwer Health;* 2012.



# BÖLÜM 3

## BOTULINUM TOXIN APPLICATIONS OF ORAL MAXILLOFACIAL REGION

*Fatih DOĞANOĞLU<sup>1</sup>*

*Sinan Yasin ERTEM<sup>2</sup>*

---

1 BİLGİ GELECEK

2 Doçent Doktor, Ankara Yıldırım Beyazıt Üniversitesi Diş Hekimliği Fakültesi Ağız, Diş ve Çene Cerrahisi ABD. e-mail: syertem@ybu.edu.tr , Orcid: 0000-0002-8217-9889

## **Introduction**

The utilization of botulinum toxin (BTX) for aesthetic purposes by means of injection is among the most frequently executed cosmetic procedures in contemporary medicine. Although it was initially introduced as a therapeutic agent to treat disorders characterized by local muscle hyperactivity, particularly around the eyes, it has gained widespread popularity in recent years as an effective treatment for various conditions. BTX has been proven to be safe and efficacious in many clinical studies, and its successful use in hundreds of thousands of patients has been documented over the years. It is now considered a reliable treatment option for most types of focal dystonia. (1)

Botulinum toxin has been widely applied in the medical field since its inception. In particular, ophthalmologists and neurologists were among the first to recognize the potential of botulinum toxin type A treatment beyond its intended use, as it not only improved facial dystonias but also provided relief from associated discomfort and disability. Consequently, many medical professionals have expanded their practices to include the cosmetic use of botulinum toxin. This has resulted in the discovery of new applications for botulinum toxin, as well as the refinement of its use in medical and cosmetic applications.

Cosmetic surgeons were among the pioneers to observe the effectiveness of facial injections in alleviating tension and migraine headaches in specific patients. This revelation has generated substantial interest in botulinum toxin research in this domain, making it one of the most thrilling fields of study today. Such findings have the potential to revolutionize treatment methods for tension and migraine headaches, thereby enhancing the quality of life for millions of individuals globally. (2,3)

## **Mechanism of Botulinum Toxin**

The botulinum neurotoxin (BTX) family is comprised of seven subtypes, namely, A, B, C1, D, E, F, and G. While all subtypes are capable of disrupting acetylcholine release, they differ in their biosynthesis, size, and cellular mechanism of action, resulting in varying clinical efficacy. BTX-A is the most potent subtype and was the first to be approved for clinical use. BTX-B and BTX-F have also exhibited positive results in humans, and a commercial version of BTX/B has been recently introduced in the United States. However, the remaining subtypes have not been extensively studied, but they are expected to exhibit clinical applications in the future. Short-acting toxins, such as BTX-E and BTX-F, may provide surgical or post-trauma benefits. Botulinum toxin (BTX) is a polypeptide comprising of a protein molecule that consists of heavy and light chains. The heat-la-



bile disulfide bond holds these chains together, and its disruption leads to the inactivation of the neurotoxin. Therefore, proper storage of BTX at the recommended temperature is highly critical. It is imperative to adhere to the storage guidelines to maintain its efficacy and safety, as any deviation from the recommended conditions may lead to a decline in its potency and effectiveness.

During reconstitution, it is important to handle the BTX carefully to maintain the integrity of both chains.(4,5) Botulinum toxin (BTX) is a neurotoxin that acts by impeding the release of Acetylcholine at the skeletal neuromuscular junction. This, in turn, leads to paralysis by hindering the transmission of a nerve impulse across the synaptic junction to the motor end plate. The inhibitory effects of BTX on the neuromuscular junction have been thoroughly documented in the literature. Specifically, research studies have established that BTX acts as a potent and selective inhibitor of Acetylcholine release at the site of injection. Overall, these findings highlight the clinical significance of BTX in the management of neuromuscular disorders.

The Botulinum toxin (BTX) exerts its effect by binding to the nerve membrane via the heavy chain, which facilitates the transportation of the light chain to its site of action, namely the protein complex. The light chain enzyme then cleaves the protein specific to the particular neurotoxin, leading to the cessation of neuromuscular transmission and consequent weakness or paralysis of the targeted muscle. Improper handling of BTX can cause the molecule to break and become ineffective. Notably, the binding of BTX to the motor end plate is irreversible and takes approximately 24 to 48 hours to achieve therapeutic action due to the depletion of acetylcholine storage in the presynaptic motor end plate. Although the binding is permanent, the paralytic effect lasts only 2 to 6 months due to the reestablishment of the neurotransmitter pathway via the formation of new axonal sprouts during the neurogenesis process. This process allows the complete recovery of the transmission pathway and the restoration of muscle function. It is vital to note that the paralysis caused by BTX can be reversed, and full muscle function can be restored. (6)

### **Indications Contrendications of Botulinum Toxin**

Botulinum toxin (BTX) is a versatile treatment option that has proven effective in both cosmetic and non-cosmetic applications. In cosmetic settings, BTX has been used to address a range of aesthetic concerns, including crow's feet, frown lines, nasal wrinkles, upper lip rhytids, nasolabial folds, neck bands, scar management, and pebbled chin. (7) Beyond these cosmetic uses, non-cosmetic applications of BTX have been explored for their therapeutic potential in addressing conditions such as migraine, stra-

bismus, hemifacial spasm, bruxism, blepharospasm, spasmodic torticollis, post-facial nerve palsy synkinesia, hyperhidrosis, and esophageal achalasia.

The identification of cosmetic indications and contraindications of Botulinum Toxin (BTX) is critical to the optimization of patient satisfaction and the minimization of complications. Its primary use is for patients with dynamic wrinkles formed during facial expression. Common injection sites include areas of dynamic movement, such as the glabella, forehead, peri-orbital lines, nasal rhytides, and perioral rhytides. Candidates with static wrinkles present at rest may also be suitable; however, additional treatment sessions or aesthetic procedures such as fillers may be necessary to achieve the desired results. Maximizing patient satisfaction and minimizing complications through precise identification and administration of BTX is essential in the field of cosmetic dermatology.

In addition, targeting specific muscles can lead to aesthetically pleasing outcomes in patients with various facial features, such as gummy smiles, asymmetrical smiles, sunken mouth corners, drooping eyebrows, enlarged nostrils, sunken nasal tips, temporal hypertrophy, and trapezius hypertrophy. Additionally, selected cases of hypertrophic submandibular and parotid glands can benefit aesthetically as well. These techniques can be effectively employed to improve the overall facial appearance of such patients.

There are several situations where botulinum toxin applications should not be used due to systemic or local contraindications. These include:

### **Infection at the injection site**

- Patients with unrealistic expectations or dysmorphophobic tendencies
- People who rely on facial movements and expressions in their profession (such as actors and musicians)
- Individuals with neuromuscular disorders (such as myasthenia gravis)
- Allergy to any of the components of BTX-A or BTX-B (albumin, saline, lactose, and sodium succinate)
- Taking medications that enhance the effects of BTX (such as aminoglycosides)
- Pregnant or breastfeeding women (pregnancy category C)
- Use in children and the elderly is not yet proven

- Those with inflammatory skin diseases. (8)

### **Basic Principles of Botulinum Toxin Applications**

It is imperative to adhere to the manufacturer's guidelines with utmost diligence to minimize the risk of denaturation and ensure the maximum potency of the product. Prior to reconstitution, the product should be stored at a temperature of  $-5^{\circ}$  if frozen or between  $2^{\circ}$  and  $8^{\circ}$  if refrigerated. Once reconstituted, it must be stored within the temperature range of  $2^{\circ}$ – $8^{\circ}$  to avoid degradation and maintain its efficacy. Adherence to these guidelines is crucial to achieve optimal results.

It is essential to follow the standard aseptic precautions while reconstituting BTX. The product is vacuum-sealed, and, to avoid rapid constitution, air can be injected. It is critical not to push saline into the vial, as it can mechanically agitate the solution. Rotating the vial gently assists in the reconstruction process. After reconstitution, during transportation, it is recommended to use a cold pack insulation box. Otherwise, reconstitution should be done after the journey, as agitation denatures the toxin and reduces the duration of action. It is important to ensure that these guidelines are followed for the safe and effective administration of BTX.

Intramuscular administration is the preferred route for BTX injections, unless otherwise indicated. When injecting in proximity to critical structures, careful dosage and depth analysis are necessary. Optimal therapeutic effect and precision are achieved through intramuscular placement. In areas such as the corner of the mouth, subcutaneous injection may be a viable alternative. Clinicians must possess a comprehensive understanding of the muscles in the area to be injected. For beginners, marking the injection sites with a washable skin marker is an advisable precautionary measure. Strict adherence to aseptic procedures is of paramount importance. During injections, it is crucial to exercise caution and avoid the nerve, vein, and artery complex in the glabella region. Familiarity with the surface anatomical landmarks, such as supraorbital nerves, is essential for administering injections in the glabellar area. (9)

It is imperative to exercise extreme caution while administering injections in the facial region. Special attention must be paid to avoid contact with the periosteum and prevent needle penetration in the danger zone. Injection at the lateral canthus necessitates careful needle placement to avoid the orbital septum. In the glabellar area, holding the muscle between two fingers can aid in precise and accurate injection. During injection in the lateral orbital skin, it is advised to spread the skin to observe the orbital veins clearly and avoid contact with superficial veins. Slow insertion of the needle during injection significantly reduces pain perception by limiting

mechanical stimulation. These measures are crucial in ensuring the safety and comfort of the patient during the injection procedure.[10,11]

## **BOTULINUM TOXIN APPLICATIONS FOR UPPER FACE**

### **Glabellar Wrinkles (Frown Lines)**

The glabellar complex refers to a group of muscles located in the region between the eyebrows. Three primary muscles constitute the complex, namely, m. corrugator supercili, m. procerus, and m. depressor supercili. The m. procerus is a slender muscle situated vertically between the eyebrows, extending from the root of the nose to the skin of the glabellar region. Its contraction leads to the appearance of horizontal lines between the eyebrows. On the other hand, the m. corrugator supercili is a robust bilateral muscle that attaches deeply into the glabellar periosteum medially and superficially into the midline of the eyebrow's skin laterally. Its contraction results in narrowing the distance between the eyebrows and causing vertical lines. Additionally, the m. corrugator supercili and m. procerus pulls the medial ends of the eyebrows medially and inferiorly.

The injection point targeting the m. procerus is the point where the nasal root intersects the imaginary line drawn between the eyebrows. The other four injection points are two points medial and lateral to the medial half of the eyebrows, targeting the m. corrugator supercili on both sides. There are different practices regarding the placement of the lateral points. There are applications at the level of the mid-pupillary line, as well as applications more medial to the mid-pupillary line, targeting the second 1/3 of the m. corrugator supercilis. Targeting the medial part of the m. corrugator supercilis will prevent the risk of eyebrow ptosis.

### **Horizontal Forehead Lines**

Forehead wrinkles are the horizontal lines that are formed by the contraction and shortening of the right and left parts of the frontalis muscle. The frontalis muscle acts as an antagonist to the muscles that pull the eyebrows downward, namely the procerus muscle, corrugator supercilii muscle, depressor supercilii muscle, and orbicularis oculi muscle. In a resting state, the frontalis muscle pulls the eyebrows upwards and ensures that they are in their normal position. When this muscle is used, it further shortens and raises the eyebrows, creating an expression of surprise on the face. (11)

Before administering injections into the M. frontalis, it is imperative to evaluate the patient's medical history for the presence of droopy eyebrows or eyelids. Injecting this muscle group may impair the strength of the m. frontalis, leading to ptosis of the eyebrow and adversely affecting the patient's field of vision. In such cases, injections into the m. frontalis should

be avoided, especially when dealing with elderly patients. Furthermore, administering injections solely into the m. frontalis without simultaneous injections into the glabella should be avoided as well. A comprehensive assessment of the patient's medical history is crucial for determining the appropriate injection sites and avoiding potential complications.(11) It is recommended that injections administered to the forehead be performed at a minimum distance of 1 cm above and outward from the orbital opening. In recent times, in order to preserve some eyebrow movements and prevent a dull gaze, it is suggested that injections be performed even higher, at a minimum distance of 2 cm above the orbital opening. The injections should be made subcutaneously at an angle of 45-60 degrees. (12)

### **Crow's Feet (Crow's Feet, Lateral Canthal Tendons)**

The lateral cantal lines, otherwise known as crow's feet, are the lines extending from the lateral part of the eyes towards the temporal region, formed during laughter and squinting. The muscles responsible for their formation are the orbicularis oculi and zygomaticus major and minor. Prior to administering injections, it is imperative to distinguish which muscle is responsible for the wrinkle. To determine the originating muscle, the patient should be instructed to squeeze their eyes instead of laughing, and the wrinkle formation should be observed. This way, injections into the zygomatic muscles can be avoided, which are dangerous in terms of low cheek and asymmetrical smile formation. By directing the injection towards the corresponding muscle, unnecessary and potentially harmful injections can be avoided.(11)

### **Under Eye Wrinkles**

Injections to the lower eyelid have been found to effectively reduce under-eye creases resulting from the contraction of the m. orbicularis oculi muscle, while also promoting increased eye opening. However, patients who have previously undergone eyelid surgery or those with lower eyelid laxity should not undergo lower eyelid injections as they are particularly vulnerable to ectropion. Furthermore, patients with Sjögren's syndrome or dry eye should refrain from botulinum toxin injection into the lower eyelid as it may exacerbate dry eye symptoms. It is also not advisable to administer toxin injections to patients with a structurally wide scleral distance below the pupil.

The injections are targeted at the pretarsal part of the m. orbicularis oculi muscle, wherein the needle should be directed horizontally from the lateral position and tangential to the lower eyelid to prevent its inadvertent entry into the orbit during sudden eye movement that may occur during injection. Typically, one or two points are injected, the first one being 3 mm

below the intersection of the midpupillary line with the ciliary margin, and the second one being 3 mm below the ciliary margin at the midpoint between the lateral canthus and the midpupillary line. Intradermal injection at a 30-degree angle is recommended in this region, avoiding deeper injections that may cause toxin diffusion into the m. obliquus inferior muscle and lead to double vision in the patient.

## **BOTULINUM TOXIN APPLICATIONS FOR MIDFACE**

### **Nasoglabellar Wrinkles (Bunny Lines)**

Nasoglabellar wrinkles are facial wrinkles that are more prominently visible in some individuals when they engage in activities such as speaking, laughing, or frowning. These wrinkles extend bilaterally tangential to the lateral walls of the nose and are formed by the contraction of the m. nasalis pars transversa (m. compressor naris). The m. nasalis muscle originates from the maxilla and ends on the bridge of the nose. In individuals who have undergone botulinum toxin-induced glabellar paralysis, these lines become more pronounced as a compensatory measure. As a result, they are also referred to as the ‘botox sign.’ (11)

It is recommended to administer injections at three specific points, with one point on the m. procerus and one point on both m. nasalis. The anatomical localization of m. nasalis injections are anterior and superior to the nasofacial junction, located just below the nasal root. It is essential to note that the skin of this region is thin and rich in vascular structures; therefore, caution must be exercised to avoid excessive depth during injections. Injections should be made subcutaneously at a 45-degree angle to prevent injection into the angular vessels. By following these guidelines, the risk of adverse effects can be significantly reduced.

### **Nasal Tip Drop**

In some individuals, a downward rotation of the tip of the nose can be seen with age. This is partly due to the effect of gravity and partly due to overworking of the m. depressor septi nasal. In suitable individuals, botulinum toxin injection can non-invasively create a rhinoplasty effect in the nose. The m. depressor septi nasi originates from the fossa incisura of the maxilla and terminates on the m. orbicularis oris. It also has fibers on the alar cartilage. It also pulls the upper lip downwards and directs the tip of the nose downwards. Deep subcutaneous injection to the lower end of the columella, targeting this muscle, results in elevation of the nasal tip as a result of some release. Some lengthening can be seen in the distance between the columella and vermillion with the effect of injection. Injections to this

area should be avoided in people with a structurally long columella-vermillion distance to prevent further lengthening. (11,12)

### **Gummy Smile**

A “gummy smile” refers to a situation where the gingival appearance is more than 3 mm during the smile. The types of gummy smiles have been categorized into four types: anterior, posterior, mixed, and asymmetric by Mazzuco and Hexsel. In a moderate gummy smile, the upper lip is lifted and everted by the levator labii superioris alaeque nasi (LLSAN), while the depressor septi nasi muscle pulls the nasal tip down. In a severe gummy smile, the upper lip is lifted by the LLS and the zygomaticus minor (ZMi) to a lesser extent. To target these three muscles, a single point injection on each side, 1 cm lateral to the nostril ala, also known as the Yonsei point, can be used.

## **BOTULINUM TOXIN APPLICATIONS FOR LOWER FACE**

### **Perioral Wrinkles(Smoker’s line)**

Perioral wrinkles also referred to as smoker’s lines, are vertical wrinkles that manifest on the skin above the lips when the lips are in the puffing position. These wrinkles are caused by the M. orbicularis oris, a circular muscle with sphincter function located around the lips. Injections to this area should be administered superficially intradermally, 1 mm above the vermilion border, at an angle of less than 30 degrees, parallel to the skin. It is worth noting that perioral wrinkles return much sooner after injection than forehead and glabellar wrinkles, necessitating injections approximately every 2-3 months. (11)

### **Chin Wrinkles (Dimpled Chin)**

Chin wrinkles refer to the uneven surface of the chin, which is caused by the loss of connective tissue and fat, as well as the contraction of the m. mentalis muscle. The m. mentalis muscle is located symmetrically and originates from the mandible, covering the entire surface of the chin and terminating in the skin of the lower lip. When the muscle contracts, it causes wrinkles on the skin of the chin, lifts the chin upward, and enables the lower lip to protrude. This phenomenon is a natural part of the aging process and is often a concern for individuals seeking to maintain a youthful appearance.

Injections are made intramuscularly at a 90-degree angle, targeting both m. mentalis. Since the chin area may contain some fat, the injections should be deeply located. Injections should remain below the transverse labiomental line to avoid affecting the m. orbicularis oris and m. depres-

or labii inferioris. Injections made at higher levels may affect the m. orbicularis oris and m. depressor labii inferioris and cause uncontrolled lip movements, inability to depress the lower lip during laughing, eating and speaking, and impaired sphincter function of the lips. (13)

### **Platysma Bands**

The m. platysma muscle is a thin and sizable muscle located bilaterally, originating from the pectoral and deltoid fascia, traversing over the clavicle, and terminating in the skin over the mandible. Its contraction enables the lower jaw to move downwards and the mouth to open slightly, leading to the downward movement of the corners of both mouth and the lower lip. The appearance of platysmal bands on the skin over the m. platysma increases with age and time. Botulinum toxin applications for neck wrinkles require careful patient selection. Optimum outcomes are observed in young individuals with good skin elasticity. With proper patient selection and accurate application, horizontal neck wrinkles can also be reduced. During the application of platysmal band injections, patients are instructed to clench their teeth in order to contract the m. platysma. This contraction results in the visibility of platysmal bands. Each band should be grasped between the index and thumb fingers and injected at intervals of 1-1.5 cm from the jawline to the clavicular line. Possible side effects of this procedure include neck weakness, which may manifest as difficulty getting out of bed, as well as dysphonia and swallowing dysfunction. It is important to consider these potential risks when deciding whether to proceed with platysmal band injections.

### **Masseter Hypertrophy**

The general aesthetic understanding asserts that a wide and square-shaped chin structure is desirable for men. However, women tend to prefer an oval-shaped and narrow jaw structure. The hypertrophy of the masseter muscle can be observed idiopathically or due to dental problems such as asymmetric chewing, gum chewing, bruxism, or psychiatric problems. This hypertrophy causes an asymmetry in the lower facial contour or a wider appearance of the lower jaw. To address this issue, partial paralysis of the M. masseter with botulinum toxin can reduce muscle volume and narrow the lower jaw contour, resulting in a more oval-shaped face. Botulinum toxin application to the M. masseter muscle was introduced in 1994 and is now a preferred alternative to invasive surgical procedures for lower facial contouring.

During the administration of the treatment, the patient is instructed to clench their teeth by firmly closing their jaw. This enables the identification of the muscle's location and the most pronounced point where



it forms the jaw contour. After marking the 2-6 most prominent points, a deep intramuscular injection is administered. The deep injection technique is recommended due to the close anatomical proximity. Following the insertion of the needle, retraction of 2-5 mm is necessary to confirm that it is inside the masseter muscle, which is confirmed by checking for bleeding.

## **CONCLUSION**

BTX applications maintain their importance as a successful treatment method with few complications, whose widespread use in the clinic is increasing. BTX applications are applied not only for aesthetic purposes but also for the physiologic restoration of function in clinical practice with great success. It is known that the rate of complications will be low when used with the right indications by following the general principles during application. In maxillofacial surgery practice, masseter BTX application is on the agenda with masseter BTX application due to bruxism, but other aesthetic and functional treatments are also applied in addition to conventional treatments.

## REFERENCES

1. Carruthers J, Stubbs HA. (1987). Botulinum toxin for benign essential blepharospasm, hemifacial spasm and age-related lower eyelid entropion. *Canad J Neurol.* 14(1), 42–45.
2. Binder WJ, Brin MF, Blitzer A, Schoenrock LD, Pogoda JM. (2000). Botulinum toxin type A (BOTOX) for treatment of migraine headaches: an open-label study. *Otolaryngol Head Neck Surg.* 123(6), 669–676.
3. Carruthers A, Langtry JA, Carruthers J, Robinson G. (1999). Improvement of tension-type headache when treating wrinkles with botulinum toxin A injections. *Headache.* 39(9), 662–665.
4. Moriarty KC.(2003) *Botulinum Toxin in Facial Rejuvenation.* 1st ed. Spain: Mosby
5. Huang, W, Foster JA, Rogachefsky AS. (2000). Pharmacology of botulinum toxin. *J Am Acad Dermatol.* 43(2 Pt 1), 249–259.
6. Niamtu J, 3rd (1999). Aesthetic uses of botulinum toxin A. *J Oral Maxillofac Surg.* 57(10), 1228–1233.
7. Jandhyala R. (2013). Impact of botulinum toxin a on the quality of life of subjects following treatment of facial lines. *J Clin Aesthet Dermatol.* 6(9), 41–45.
8. Soğancı G, Yağcı F. (2016). Dış Hekimliğinde Botoks: Derleme. *Atatürk Üniversitesi Dış Hekimliği Fakültesi Dergisi.* 26(2), 358-365.
9. Snider CC, Amalfi AN, Hutchinson LE, Sommer NZ. (2017). New Insights into the Anatomy of the Midface Musculature and its Implications on the Nasolabial Fold. *Aesthetic Plast Surg.* 41(5), 1083–1090.
10. Nestor M, Ablon G, Pickett A. (2017). Key Parameters for the Use of AbobotulinumtoxinA in Aesthetics: Onset and Duration. *Aesthet Surg J.* 37(suppl\_1), S20–S31.
11. Benedetto AV. *Botulinum toxin in clinical dermatology.* CRC Press; 2006.
12. Bertossi D, Cavallini M, Cirillo P, Piero Fundarò S, Quartucci S, Sciuto C, Tonini D, Trocchi G, Signorini M. (2018). Italian consensus report on the aesthetic use of onabotulinum toxin A. *J Cosmet Dermatol.* 17(5), 719–730.
13. de Sa Earp AP, Marmur ES. (2008). The five D's of botulinum toxin: doses, dilution, diffusion, duration and dogma. *J Cosmet Laser Ther.* 10(2), 93–102.