



# RESEARCH & REVIEWS IN HEALTH SCIENCES

*December 2022*

## Editors

Prof. Dr. Engin ŞAHNA

Prof. Dr. Hasan AKGÜL

Prof. Dr. Zeliha SELAMOĞLU

**İmtiyaz Sahibi / Publisher • Yaşar Hız**  
**Genel Yayın Yönetmeni / Editor in Chief • Eda Altunel**  
**Kapak & İç Tasarım / Cover & Interior Design • Gece Kitaplığı**  
**Editörler / Editors • Prof. Dr. Engin ŞAHNA**  
Prof. Dr. Hasan AKGÜL  
Prof. Dr. Zeliha SELAMOĞLU  
**Birinci Basım / First Edition • © Aralık 2022**  
**ISBN • 978-625-430-557-3**

**© copyright**

Bu kitabın yayın hakkı Gece Kitaplığı'na aittir.

Kaynak gösterilmeden alıntı yapılamaz, izin  
almadan hiçbir yolla çoğaltılamaz.

The right to publish this book belongs to Gece Kitaplığı.  
Citation can not be shown without the source, reproduced in any way  
without permission.

**Gece Kitaplığı / Gece Publishing**  
**Türkiye Adres / Turkey Address:** Kızılay Mah. Fevzi Çakmak 1. Sokak  
Ümit Apt. No: 22/A Çankaya / Ankara / TR  
**Telefon / Phone:** +90 312 384 80 40  
**web:** www.gecekitapligi.com  
**e-mail:** gecekitapligi@gmail.com



**Baskı & Cilt / Printing & Volume**

Sertifika / Certificate No: 47083

# Research & Reviews in Health Sciences

December 2022

## Editors

Prof. Dr. Engin ŞAHNA  
Prof. Dr. Hasan AKGÜL  
Prof. Dr. Zeliha SELAMOĞLU



# İÇİNDEKİLER

## **CHAPTER 1**

### **VARICOCELE AND SOME EFFECTS**

*Saadet BELHAN*..... 1

## **CHAPTER 2**

### **PROS AND CONS OF MICRORNAS IN CLINICAL USE FROM DIAGNOSTIC, PROGNOSTIC, AND THERAPEUTIC PERSPECTIVES**

*Menderes Yusuf TERZİ, Hasret ECEVİT*..... 11

## **CHAPTER 3**

### **NANO PARTICLES AND GREEN SYNTHESIS**

*Nurhan GÜMRÜKÇÜOĞLU* ..... 27

## **CHAPTER 4**

### **TYPES OF HYPERPIGMENTATIONS AND TREATMENT OPTIONS**

*Tunahan Mustafa CEYLAN, Abdulsamet TANIK*..... 45

## **CHAPTER 5**

### **DIABETES MELLITUS AND CYTOKINES**

*Dilek Nur BESTİL, Burcu Menekşe BALKAN, Tevhide SEL*..... 67

## **CHAPTER 6**

### **IATROGENIC FACTORS THAT NEGATIVELY AFFECT THE PERIODONTIUM CAUSED BY ENDODONTIC TREATMENTS: AN OVERVIEW**

*Raif ALAN, Arslan TERLEMEZ* ..... 81

**CHAPTER 7**

**CURRENT REHABILITATION APPROACH IN  
PERIPHERAL VESTIBULAR DISORDERS: A REVIEW ON  
TASK-ORIENTED TRAINING**

*Yasemin APAYDIN, Umut APAYDIN*..... 95

**CHAPTER 8**

**PREVALENCE OF DIROFILARIASIS AND DIROFILARIA  
SPP. IN DOGS IN TURKEY**

*Özgür Yaşar ÇELİK, Burçak ASLAN ÇELİK*..... 105

**CHAPTER 9**

**GENERAL PERSPECTIVES OF ANTIOXIDANTS AND  
NATURAL SOURCES**

*Deniz KARAKCI, Nilay SEYIDOGLU*..... 125

**CHAPTER 10**

**VARICOCELE, TESTOSTERONE HORMONE AND  
VARICOCELECTOMY**

*Saadet BELHAN*..... 141

**CHAPTER 11**

**EFFECTS OF THE PANDEMIC ON MOTHER-INFANT  
ATTACHMENT: A LITERATURE REVIEW**

*Gizem ÇITAK, Özlem DURAN AKSOY*..... 153

**CHAPTER 12**

**THE EFFECT OF EXERCISE ON INFLAMMATION**

*Cemre AYDEĞER, Hüseyin Avni EROĞLU*..... 165

**CHAPTER 13**

**THE BUFFALO IN THE WORLD AND TÜRKİYE FROM 1961  
TO 2020**

*Memiş BOLACALI, Cahit ÖZCAN, Mürsel KÜÇÜK.....177*

**CHAPTER 14**

**TELOMERASE ACTIVITY IN NEUROBLASTOMA**

*Nihal İNANDIKLIOĞLU.....197*

**CHAPTER 15**

**REPRODUCTIVE SYSTEM IN FEMALE RATS**

*Volkan KOŞAL.....209*

**CHAPTER 16**

**IS THE ENERGY OF THE FEED GOING INTO THE AIR?**

*Cahit ÖZCAN, Mehmet IRMAK.....223*

**CHAPTER 17**

**MORPHOMETRY AND ORGANIZATION OF FORAMEN  
JUGULARE IN FETAL CADAVERS**

*Özcan ÖZGEL, Soner ALBAY.....233*







# ***CHAPTER 1***

## **VARICOCELE AND SOME EFFECTS**

*Saadet BELHAN<sup>1</sup>*

---

<sup>1</sup> Assoc. Prof. Dr., Van Yuzuncu Yil University, Faculty of Veterinary Medicine, Department of Reproduction and Artificial Insemination, Van, Turkey. ORCID ID: <http://orcid.org/0000-0002-8115-2051>

## INTRODUCTION

Varicocele, which has a very important place in male infertility, is defined as the enlargement of the veins in the plexus pampiniformis beyond the physiological limits (Kendirci et al., 2003). Varicocele may occur as a result of compression of the renal vein or internal spermatic vein as a result of tumor or other pathology. Varicocele usually occurs with increased fluid pressure in the testicular veins. It is characterized by dilatation, stasis and high pressure in the veins in the spermatic cord (Raifer 1998, Ahlberg et al., 1966). While it is mostly seen in the left testis, it is less bilateral (Kantartzi and Goulis, 2007). It has been reported that varicocele causes problems on the hypothalamo-pituitary-gonadal axis and blood-testis barrier (Jarrow and Sanzone, 1992).

In studies conducted on humans, it has been determined that there are changes in seminal parameters and hormonal values, and follicle stimulating hormone (FSH) values increase in varicocele. It has been suggested that these changes may cause damage to the germinal epithelium (Nagao et al., 1986; Nieschlag et al., 1997). In a reported study, it was reported that there is a link between varicocele and erectile dysfunction (Kim and Choi, 1992). In another study, it was determined that the mean serum testosterone level was low in patients with varicocele and sexual dysfunction (Comhaire and Vermeulen, 1975).

Varicocele creates serious problems on testicular structure and function. In particular, various hypotheses have been elaborated to explain its deleterious effect on testicular function. Of these hypotheses, changes in testicular temperature are the most widely accepted. Because the thermoregulation in the testis is very important for the spermatogenesis to take place in a healthy way. There are two mechanisms in the regulation of scrotal temperature in the testis. One of them is the scrotum itself. The other is the heat exchange between the arteries and veins in the plexus pampiniformis in the spermatic cord. In this heat exchange system, the temperature of the spermatic artery blood entering the testis is cooled by the low temperature of the blood in the veins leaving the testis. While this is the normal mechanism, it is thought that this mechanism is impaired in varicocele (Dahl and Hendrick, 1959). In this case, the scrotal temperature rises. As spermatic enzyme activity such as 17 $\alpha$ -hydroxyprogester aldolase is inhibited at high temperatures, testosterone production decreases (Andò et al., 1983). In addition, it has been emphasized that increased temperature causes abnormal increases in reactive oxygen species (ROS) levels, decreases the efficiency of DNA polymerase enzyme, causes apoptosis and impairs the spermatogenesis process (Rao et al., 2015; Witt and Lipshultz, 1993; Xu et al., 2016).

It has been reported that varicocele has pathological effects on Leydig and Sertoli cells (Oh et al., 2016), and it causes decreases in testosterone levels, especially with apoptosis on Leydig cells (Luo et al., 2011). It is known how important and indispensable testosterone is for spermatogenesis and fertility (Benoff and Gilbert, 2001).

## **EFFECTS OF VARICOCELE ON SOME PARAMETERS**

### **1-The effects of varicocele on sperm parameters**

It has been reported that testicular temperature increases in varicocele and this temperature increase causes excessive ROS formation (Xu et al., 2016). While ROS formed at physiological levels during the realization of cellular activities are desirable, cellular functions and sperm functions are damaged when they occur at pathological levels (Saalu, 2010). Increasing ROS also causes some problems on sperm parameters (Agarwal and Said, 2005). Sperm are particularly vulnerable to ROS because they contain large amounts of polyunsaturated fats and the amount of antioxidant enzymes in their cytoplasm is low (Al-Maghrebi and Renno, 2016). In addition, testicular tissue consumes large amounts of oxygen as it is active in cell division and spermatogenesis continues continuously. Therefore, it is a very sensitive tissue against oxygen depletion and free radicals (Agarwal et al., 2008). When the reported study results are evaluated, it is seen that varicocele causes problems on sperm parameters (Alizadeh et al., 2016; Asadi et al., 2019; Erfani Majd et al., 2019; Hassani-Bafrani et al., 2019; Moshtaghion et al., 2013). ; Soni et al., 2018).

In the study investigating the effects of silmarin on varicocele; It has been determined that varicocele causes significant decreases in sperm count, motility and viability. In addition, varicocele created a decrease in the number of Sertoli cells. Silmarin was administered at a dose of 50 mg in the study and evaluations (structural integrity of DNA, Sertoli cell count, testicular MDA, total thiol content, as well as some sperm parameters such as sperm count and motility) were made after 42 days. Silmarin significantly attenuated the negative effects of varicocele on sperm count and sperm motility. In addition, the rate of dead sperm decreased in the group that was treated with silymarin. Researchers have reported that silmarin significantly alleviates varicocele-induced sperm damage (Moshtaghion et al., 2013).

In the study evaluating the effects of Motiliperm on varicocele, it was determined that the number of sperm in the vas deferens decreased more than the number of sperm in the epididymis in the varicocele group. In addition, it was observed that sperm motility decreased significantly in the varicocele group compared to the other groups. Researchers have reported that motiliperm increases both sperm count and sperm motility. In

particular, they found that the 200 mg dose caused significant increases in sperm count and the sperm count approached the control group values (Soni et al., 2018).

In another experimental varicocele study, the effects of Royal jelly on spermatogenesis and antioxidant enzymes were investigated. In the study, sperm count and viability were found to be significantly lower in varicocele rats. However, it was emphasized that Royal jelly administered at a dose of 200 mg caused significant increases in sperm count and live sperm rate (Asadi et al., 2019). Hassani-Bafrani et al. (2019) investigated the effects of berberine on oxidative stress, inflammation and sperm parameters in their experimental varicocele study. Researchers, in the varicocele group; They observed significant decreases in sperm count, percentage of sperm viability, motility and chromatin condensation. They reported that there were significant improvements in sperm density, motility, viability and chromatin with the berberine they applied. In addition, berberine significantly reduced DNA damage caused by varicocele. In another experimentally induced varicocele study, it was determined that there were problems in sperm parameters and increases in sperm DNA damage. Based on their results, the researchers suggested that varicocele has a negative effect on spermatogenesis and will lead to the production of sperm with damaged chromatin, which may endanger the future health of offspring (Erfani Majd et al., 2019).

Alizadeh et al. (2016) evaluated sperm parameters 10 weeks after varicocele induction. They found that there was a decrease in sperm viability and motility. However, it was observed that all parameters increased significantly aminoguanidine administered as 50 mg/kg daily for 10 weeks.

## **2-The effects of varicocele on biochemical parameters**

Many studies have shown that increased ROS in varicocele causes testicular tissue damage and biochemical changes. In the study investigating the effects of melatonin on nitric oxide (NO) levels and antioxidant enzymes in testicular tissues of varicocele rats, ROS and NO levels of testicular tissue increased significantly. However, in the study, it was determined that melatonin, which was prepared and applied freshly daily for 4 weeks after varicocele induction, increased antioxidant enzyme activity and decreased NO levels. Researchers reported that the NO level in the left testes of rats increased twofold compared to the right testes (Semercioz et al., 2003).

In the study conducted to determine whether berberine has an anti-inflammatory effect in varicocele, polymorphonuclear and mononuclear immune cell infiltration and testicular interleukin-6 (IL-6) and tumor necrosis factor- $\alpha$  (TNF- $\alpha$ ) levels were analyzed. In the study, it was determined that increased immune cell infiltration and IL-6 and TNF- $\alpha$  positive reac-

tions were higher in the varicocele group. In the groups treated with berberine, on the other hand, decreased immune cell infiltration and testicular IL-6 and TNF- $\alpha$  positive reactions were found to be very reduced. In addition, in the varicocele group, manganese superoxide dismutase (Mn-SOD), copper/zinc-superoxide dismutase (CuZn-SOD), Extracellular superoxide dismutase (EC-SOD), glutathione peroxidase (GSH-px), total antioxidant capacity (TAC) levels and superoxide levels. A significant decrease was detected in dismutase (SOD) and GSH-px activities. An increase in testicular malondialdehyde (MDA) level was observed. In the study, increases in mRNA levels and TAC levels of Mn-SOD, CuZn-SOD, EC-SOD and GSH-px were detected in the berberine-treated groups. It has also been reported that there is an increase in SOD and GSH-px activity and a decrease in MDA content (Hassani-Bafrani et al., 2019).

In a study evaluating the antioxidant status in sperm and testis in experimental varicocele rats, it was determined that there were significant decreases in catalase (CAT), SOD and GPx levels, while significant increases in MDA levels (Erfani Majd et al., 2019). In another study, it was determined that the glutathione (GSH) level decreased and the MDA level increased in the varicocele group. However, it has been reported that applied motilipermin produces improvements in GSH and MDA levels (Soni et al., 2018).

### **3-The effects of varicocele on the testicular structure**

Atrophy of the seminiferous tubules and severe degenerative changes in the germinal epithelium of the varicoceles testicles were observed. In addition, a decrease in spermatogenetic cells and vascular congestion were detected (Semercioz et al., 2003). Moshtaghion et al. (2013) reported in their study that detached germinal epithelium was found in 25% of the seminiferous tubules on the side where varicocele was applied, and this rate was reduced to 15% after simarin application. The researchers found that the varicocele group had higher tubular depletion and severe edema in the interstitial connective tissue, and the number of Sertoli cells was significantly reduced. However, they reported that simarin application reduced interstitial edema and significantly increased the number of Sertoli cells per tubule. In another study, reduction and degeneration were observed in tubular diameter and germ cell number. However, it has been reported that royal jelly application reduces degenerative changes (Asadi et al., 2019).

Varicocele; It has been reported that in Leydig cells cause hyperplasia, decrease in the number of Sertoli cells, increase vacuole in the endoplasmic reticulum, maturation arrest, shedding in the germinal epithelium and thickening of the basal membrane of the tubules (Paduch and Skoog, 2001). In a study conducted to determine whether iNOS (inducible nitric ox-

ide synthase) has a role in testicular dysfunction associated with varicocele, significant differences were found in % iNOS activity in both testicles of the varicocele group compared to the control group (Köksal et al., 2004).

In the study investigating the effect of *Fumaria parviflora* on apoptosis in varicocele, it was reported that *Fumaria parviflora* had curative effects on seminiferous tubule diameter, Johnsen score and epithelial thickness. It has also been emphasized that it reduces testicular damage while significantly reducing Bax density (Dolatkhah et al., 2020).

In the study evaluating the effects of varicocele on apoptosis and StAR mRNA expression in Leydig cells, it was determined that the mean apoptosis index of Leydig cells was significantly higher than the control group and the StAR mRNA levels in Leydig cells were significantly lower than the control group. Researchers have suggested that varicocele impairs Leydig cell function by increasing apoptosis and suppressing the expression of StAR protein. They also reported that the level of apoptosis in the left testis was higher than that in the right, and the number of Leydig cells on the left side was significantly reduced compared to that on the right side (Luo et al., 2011).

Khosravian et al. (2014) found that seminiferous tubule diameter and germinal epithelial height decreased in the varicocele group, that there was a significant atrophy and edema in the seminiferous tubules and highly degenerated testes, and that there were improvements when Vit E and testosterone were administered together. They also reported that the number of Leydig cells decreased in the varicocele group and the percentage of hypertrophied Leydig cells increased. Researchers reported that the Vit E and testosterone they applied alleviated the degeneration in Leydig cells.

#### **4-The effects of varicocele on testicular weight**

When the studies on whether varicocele has an effect on testicular weight are examined; It has been reported that varicocele causes reductions in testicular weights. In the same studies, it has been suggested that the application of simarin or the combined application of Vit E and testosterone compensates for the reductions in testicular weights (Khosravian et al., 2014; Moshtaghion et al., 2013; Soni et al., 2018).

#### **5-The effects of varicocele on some reproductive hormones**

It is known that enzyme activity is dependent on temperature. It has been reported that the increase in intratesticular temperature impairs the activities of enzymes involved in the conversion of cholesterol to testosterone (Bedrak et al., 1971; Gomes et al., 1971).

Luo et al. (2011) suggested that testicular distress in varicocele is bi-

lateral and gradual and that the intratesticular testosterone level falls earlier than the serum testosterone level. Researchers found that serum testosterone levels decreased after 4 and 8 weeks of operation, but this decrease was not significant, and intratesticular testosterone levels decreased significantly after 8 weeks. It was also reported that the mean apoptosis index of Leydig cells in the varicocele group increased significantly after 4 or 8 weeks. Researchers explained that varicocele impairs Leydig cell function by increasing apoptosis and suppressing the expression of StAR protein.

In another study, it was found that serum free testosterone levels are lower and estradiol and steroid-binding globulin levels are higher in varicocele (Kazama, 1995). Khosravanian et al. (2014) found that there were significant decreases in serum testosterone levels in varicocele, and that Vit E and testosterone administration increased testosterone levels.

In another study, it was reported that the basal testosterone level was lower in men with varicocele compared to normal men. Researchers found significant improvements in testosterone levels in hypogonadal men after varicocelectomy, but minor changes in eugonadals (Abdel-Meguid et al., 2014). Saylam et al. (2020) reported increases in FSH, luteinizing hormone (LH) and total testosterone levels after microsurgical varicocele repair in their study in hypogonadal infertile men with varicocele. Another study reported significant improvements in serum testosterone after varicocelectomy in men aged 40 years (Hsiao et al., 2011).

In addition to these listed studies, some investigators reported that some hormone levels such as FSH, LH, testosterone and estradiol in patients with varicocele remained within normal limits (Schiff et al., 1976; Swerdloff and Walsh, 1975).

## CONCLUSION

As a result of the literature review on varicocele, it has been reported that varicocele causes increases in ROS levels. Increasing ROS levels cause an increase in lipid peroxidation, DNA fragmentation and induction of apoptosis. When the studies in this field are examined, it has been understood that varicocele creates problems on many parameters that will cause problems in male reproduction. Evaluation of these parameters together will provide more information about the mechanisms of varicocele causing male infertility. Therefore, it will help to provide a molecular mechanism-based therapeutic approach in studies in this field.

## REFERENCES

- Abdel-Meguid, T. A., Farsi, H. M., Al-Sayyad, A., Tayib, A., Mosli, H. A., & Halawani, A. H. (2014). Effects of varicocele on serum testosterone and changes of testosterone after varicocelectomy: a prospective controlled study. *Urology*, 84(5), 1081–7.
- Agarwal, A., Makker, K., & Sharma, R. (2008). Clinical relevance of oxidative stress in male factor infertility: an update. *American Journal of Reproductive Immunology*, 59(1), 2–11.
- Agarwal, A., & Said, T. M. (2005). Oxidative stress, DNA damage and apoptosis in male infertility: a clinical approach. *BJU International*, 95(4), 503–7.
- Ahlberg, N. E., Bartley, O., Chidekel, N., & Fritjofsson, A. (1966). Phlebography in varicocele scroti. *Acta Radiologica: Diagnosis*, 4(5), 517–28.
- Alizadeh, R., Navid, S., Abbasi, N., Yari, A., Mazaheri, Z., Daneshi, E., Agarwal, A., & Abbasi, M. (2016). The effect of aminoguanidine on sperm motility and mitochondrial membrane potential in varicocele rats. *Iranian Journal of Basic Medical Sciences*, 19(12), 1279–1284.
- Al-Maghrebi, M., & Renno, W. M. (2016). Genistein alleviates testicular ischemia and reperfusion injury-induced spermatogenic damage and oxidative stress by suppressing abnormal testicular matrix metalloproteinase system via the Notch 2/Jagged 1/Hes-1 and caspase-8 pathways. *Journal of Physiology and Pharmacology*. 67(1), 129–37.
- Andò, S., Giacchetto, C., Colpi G., Panno, M. L., Beraldi, E., Lombardi, A., & Sposato, G. (1983). Plasma levels of 17-OH-progesterone and testosterone in patients with varicoceles. *Acta Endocrinologica*, 102(3), 463–9.
- Asadi, N., Kheradmand, A., Gholami, M., Saidi, S. H., & Mirhadi, S. A. (2019). Effect of royal jelly on testicular antioxidant enzymes activity, MDA level and spermatogenesis in rat experimental Varicocele model. *Tissue & Cell*, 57, 70–77.
- Bedrak, E., Samiloff, V., Sod-Moriah, U. A., & Goldberg. S. (1971). Synthesis of androgens in vitro by testes of rats acclimatized to a hot environment. *Journal of Endocrinology*, 51(3), 489-98
- Benoff, S., & Gilbert, B. R. (2001). Varicocele and male infertility: part I. Preface. *Human Reproduction Update*. 7(1). 47–54.
- Comhaire, F., & Vermeulen, A. (1975). Plasma testosterone in patients with varicocele and sexual inadequacy. *Journal of Clinical Endocrinology and Metabolism*, 40(5), 824–9.
- Dahl, H. V., & Hendrick, J. F. (1959). A vascular mechanism for maintaining testicular temperature by counter-current exchange. *Surgery Gynecology & Obstetrics*, 108(6), 697–705.
- Dolatkah, M. A., Shokoohi, M., Charvande, S., Tvrda, E., Shoorei, H., Moghimian, M., & Alihemmati, A. (2020). Fumaria parviflora regulates oxidative stress and apoptosis gene expression in the rat model of varicocele induction. *Andrologia*, 52(11), e13826.
- Erfani Majd, N., Sadeghi, N., Tavalae, M., Tabandeh, M. R., & Nasr-Esfahani,



- M. H. (2019). Evaluation of oxidative stress in testis and sperm of rat following induced varicocele. *Urology Journal*, 16(3), 300–306.
- Gomes, W. R., Butler, W. R., & Johnson, A. D. (1971). Effect of elevated ambient temperature on testis and blood levels and in vitro biosynthesis of testosterone in the ram. *Journal of Animal Science*, 33(4), 804–7.
- Hassani-Bafrani, H., Najaran, H., Razi, M., & Rashtbari, H. (2019). Berberine ameliorates experimental varicocele-induced damages at testis and sperm levels; evidences for oxidative stress and inflammation. *Andrologia*, 51(2), e13179.
- Hsiao, W., Rosoff, J. S., Pale, J. R., Greenwood, E. A., & Goldstein, M. (2011). Older age is associated with similar improvements in semen parameters and testosterone after subinguinal microsurgical varicocelectomy. *Journal of Urology*, 185(2), 620–5.
- Jarrow, J. P., & Sanzone, J., J. (1992). Risk factors for male partner antisperm antibodies. *Journal of Urology*, 148(6), 1805–7.
- Kantartzi, P. D., Goulis, Ch. D., Goulis, G. D., & Papadimas, I. (2007). Male infertility and varicocele: myths and reality. *Hippokratia*, 11(3), 99–104
- Kazama, T. (1995) Effect of experimental varicocele on rat Leydig cell function. *Nihon Hinyōkika Gakkai zasshi*, 86(2), 308–15.
- Kendirci, M., Boylu, U., & Miroglu, C. (2003). Andrologic surgery of the 15th century. In *Cerrahiyetü'l Haniye. The history of Male-Female Sexuality and fertility in Asia Minor (Today's Turkey)*. (Eds: Kendirci, M., Kadioglu, A., Miroglu, C.), Istanbul, 127–148.
- Khosravanian, N., Razi, M., Farokhi, F., & Khosravanian, H. (2014). Testosterone and vitamin E administration up-regulated varicocele-reduced Hsp70-2 protein expression and ameliorated biochemical alterations. *Journal of Assisted Reproduction and Genetics*, 31(3), 341–54.
- Kim, Y. C., & Choi, H. K. (1992). Clinical value of scrotopenogram for evaluating varicocele and erectile dysfunction. *Urology*, 39(2), 150–6
- Köksal, I. T., Erdoğan, T., Gülkesen, H., Sezer, C., Usta, M., Çiftçioglu, A., & Baykara, M. (2004) The potential role of inducible nitric oxide synthase (iNOS) activity in the testicular dysfunction associated with varicocele: an experimental study. *International Urology and Nephrology*, 36(1), 67–72.
- Luo, D. Y., Yang, G., Liu, J. J., Yang, Y. R., & Dong, Q. (2011). Effects of varicocele on testosterone, apoptosis and expression of StAR mRNA in rat Leydig cells. *Asian Journal of Andrology*, 13(2), 287–91.
- Moshtaghion, S. M., Malekinejad, H., Razi, M., & Shafie-Irannejad, V. (2013). Silymarin protects from varicocele-induced damages in testis and improves sperm quality: evidence for E2f1 involvement. *Systems Biology in Reproductive Medicine*, 59(5), 270–80.
- Nagao, R. R., Plymate, S. R., Berger, R. E., Perin, E. B., & Paulsen, C. A. (1986): Comparison of gonadal between fertile and infertile men with varicocele. *Fertility and Sterility*, 46(5), 930–3.
- Nieschlag, E., Behre, H. M., Meschede, D., & Kamischke, A. (1997). Disorders

- at the testicular level. In: *Andrology, Male Reproductive Health and Dysfunction*, chapter 8, 133–157.
- Oh, Y. S., Jo, N. H., Park, J. K., Gye, M. C. (2016). Changes in inflammatory cytokines accompany deregulation of claudin-11, resulting in inter-sertoli tight junctions in varicocele rat testes. *Journal of Urology*, 196(4), 1303–12.
- Paduch, D. A., Skoog, S. J. (2001). Current management of adolescent varicocele. *Reviews in Urology*, 3(3), 120–33.
- Rao, M., Zhao, X. L., Yang, J., Hu, S. F., Lei, H., Xia, W., & Zhu, C. H. (2015). Effect of transient scrotal hyperthermia on sperm parameters, seminal plasma biochemical markers, and oxidative stress in men. *Asian Journal of Andrology*, 17(4), 668–75.
- Raifer, J. (1998). Varicocele. Congenital anomalies of the scrotum and testis. *Campbell's Urology*. (Eds: Walsh, P. C., Retik, A. B., Vaughan, E. D., Wein, A. J.), Philadelphia, W.B. Saunders Company, 2186–2195.
- Saalu, L. C. (2010). The incriminating role of reactive oxygen species in idiopathic male infertility: an evidence based evaluation. *Pakistan Journal of Biological Sciences*, 13(9), 413–22.
- Saylam, B., Çayan, S., & Akbay, E. (2020). Effect of microsurgical varicocele repair on sexual functions and testosterone in hypogonadal infertile men with varicocele. *Aging Male*, 23(5), 1366–1373.
- Schiff, I., Wilson, E., Newton, R., Shane, J., Kates, R., Ryan, K. J., & Naftolin, F. (1976). Serum luteinizing hormone, folliclestimulating hormone and testosterone responses to gonadotrophin-releasing factor in males with varicoceles. *Fertility and Sterility*, 27(9), 1059–1061.
- Semercioz, A., Onur, R., Ogras, S., & Orhan, I. (2003). Effects of melatonin on testicular tissue nitric oxide level and antioxidant enzyme activities in experimentally induced left varicocele. *Neuro Endocrinology Letters*, 24(1-2), 86–90.
- Soni, K. K., Zhang, L. T., Choi, B. R., Karna, K. K., You, J. H., Shin, Y. S., Lee, S. W., Kim, C. Y., Zhao, C., Chae, H. J., Kim, H. K., & Park, J. K. (2018). Protective effect of MOTILIPERM in varicocele-induced oxidative injury in rat testis by activating phosphorylated inositol requiring kinase 1 $\alpha$  (p-IRE1 $\alpha$ ) and phosphorylated c-Jun N-terminal kinase (p-JNK) pathways. *Pharmaceutical Biology*, 56(1), 94–103.
- Swerdlow RS & Walsh PC. (1975). Pituitary and gonadal hormones in patients with varicoceles. *Fertility and Sterility*, 26(10), 1006–12.
- Witt, M. A., & Lipshultz, L. I. (1993). Varicocele: a progressive or static lesion? *Urology*, 42(5), 541–3.
- Xu, F., Chen, Y., Chen, H., Xu, Z., Han, Y., Yu, W., & Dai, Y. (2016). Impact of varicocele and varicocelectomy on the apoptosis of spermatogenic cells and the levels of nitrogen monoxidum and interleukin 1 in the rat testis. *National Journal of Andrology*, 22(3), 200–4.



## **CHAPTER 2**

### **PROS AND CONS OF MICRORNAS IN CLINICAL USE FROM DIAGNOSTIC, PROGNOSTIC, AND THERAPEUTIC PERSPECTIVES**

*Menderes Yusuf TERZİ<sup>1,2</sup>, Hasret ECEVİT<sup>1</sup>*

---

1 Assist. Prof. Dr., Department of Medical Biology, Faculty of Medicine, Hatay Mustafa Kemal University, Hatay, Türkiye. Department of Molecular Biochemistry and Genetics, Graduate School of Health Sciences, Hatay Mustafa Kemal University, Hatay, Türkiye. ORCID ID: 0000-0001-8478-0451

2 Assist. Prof. Dr., Department of Medical Biology, Faculty of Medicine, Hatay Mustafa Kemal University, Hatay, Türkiye. ORCID ID: 0000-0002-4444-475X

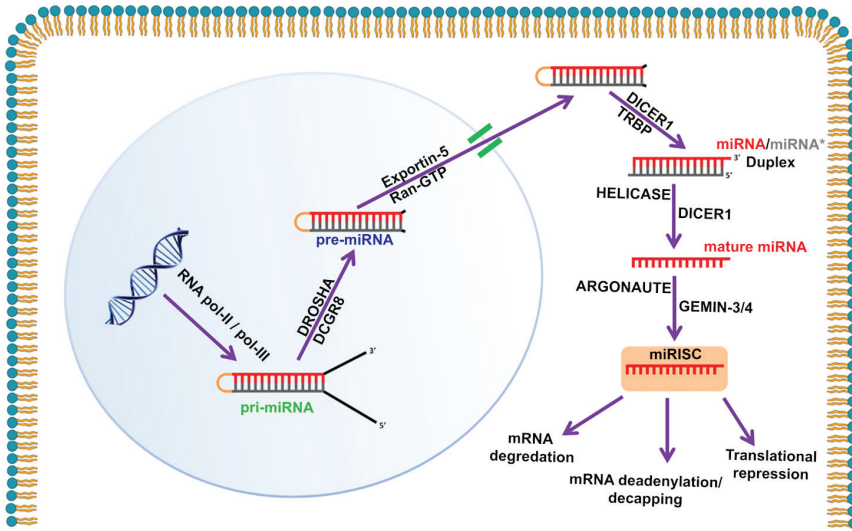
## INTRODUCTION

Surveillance of patients with non-invasive circulatory biomarkers is very significant for diagnostic and prognostic processes of many chronic diseases since it is relatively simpler to apply, more easily reproducible than invasive methods and it does not bring a burden to health system and national economies as it is cost-effective. In addition, they are essential for the traceable diseases which can be monitored for many years during their pre-clinic stage (Nagaraj, 2017; Varesi et al., 2022). Surgical interventions have to be applied to diagnose most of the diseases such as cancer, central nerve system ailments, etc. (Schulz, Loloi, Pina Martina, & Sankin, 2022; Varesi et al., 2022). For instance, invasive interventions are performed for the quantitative estimation of tau protein and amyloid beta levels to diagnose the various stages of Alzheimer disease (Varesi et al., 2022). However, these invasive procedures are not risk-free and they are painful processes for the patients which makes the non-invasive biomarkers an attractive option to avoid the potential physical, mental and, financial burden of invasive procedures and to experience more comfortable diagnostic and progression monitoring from the earliest stage of the disease (Nagaraj, 2017; Schulz et al., 2022). Recently microRNAs (miRNAs) have been in the focus of the science world as a circulatory biomarker which has a potential to be an alternative candidate in addition to current non-invasive biomarkers including various proteins and lipids (Nagaraj, 2017). Because, miRNAs are not only present in cells but also being secreted into blood stream, which are called circulating miRNAs (K. Wang, Zhang, Weber, Baxter, & Galas, 2010; Zen & Zhang, 2012).

MicroRNAs (miRNAs) are small non-coding gene regulatory oligonucleotides (19-30 nucleotide long) which function by mostly targeting mRNAs via perfect or imperfect complementation resulting in mRNA degradation or protein synthesis inhibition (Ecevit, Motor, & İzmirli, 2013; Ha & Kim, 2014). The biogenesis of mature miRNAs is depicted in Figure 1. Specifically, circulating miRNAs are thought to function to mediate intercellular communications (Chen, Liang, Zhang, Zen, & Zhang, 2012). They are also considered to carry the underlying information of a cell under stressful circumstances which makes them a potential candidate for intercellular signaling. In addition, the miRNAs in circulation due to apoptosis are supposed to be an indicator of cellular state (Nagaraj, 2017). Moreover, there are some studies reporting the *in vitro* assimilation of miRNA exosomes by neighboring cells which looks like ‘message in a bottle’ and supports the idea of their function in intercellular communication (Kharaziha, Ceder, Li, & Panaretakis, 2012; Morello et al., 2013; Valadi et al., 2007). Further, circulating miRNAs are reported to be expressed differentially between post and pre-operated colorectal cancer patients as

well as control subjects which supports the idea that miRNAs can be originated from tumor tissues and tend to decrease after tumor resection in cancer patients (Li et al., 2015).

Since the discovery of their presence in cell-free biological fluids such as plasma, urine, saliva, seminal fluid, breast milk, colostrum, tears, amniotic fluid, cerebrospinal fluid, pleural fluid, peritoneal fluid, and bronchial lavage (Weber et al., 2010), they have taken full scope and attention of researchers to utilize them for clinical purposes (Terzi, 2020). As one of the gene expression regulatory epigenetics mechanisms, non-coding RNAs and their one of the most prominent member miRNAs, have been involved in several physiological and pathological conditions such as cancer, cardiovascular diseases, and renal failures (Fazmin, Achercouk, Edling, Said, & Jeevaratnam, 2020; Okuyan, Dogan, Terzi, Begen, & Turgut, 2021; Terzi, 2020). When secreted into bodily fluids, miRNAs are protected from RNase-mediated degradations via multiple mechanisms such as formation of miRNA-protein complexes or internalization by exosomes, which equip them with high stability and thereby make them detectable for longer times (Xiao et al., 2019). The fact that RNA molecule is very susceptible to nucleases and thereby easily degradable may bring about a concern regarding the sustained traceability of the miRNA levels in circulation for clinical purposes (Condrat et al., 2020). To be more specific, circulating miRNAs are known to be secreted in exosomes with a 10% percent and the rest 90% form complexes with various proteins including argonaute 2 (Ago2) (Arroyo et al., 2011), nucleophosmin 1 (NPM 1) (K. Wang et al., 2010), and high density lipoprotein (HDL) (Vickers, Palmisano, Shoucri, Shamburek, & Remaley, 2011) which provide them a protective shield against RNases that are known to be present in different body fluids (Lu, Li, Moussaoui, & Boix, 2018). Besides, the levels of some certain cell-free miRNAs distinctly alter between healthy and disease people (Fazmin et al., 2020; Jin, 2021).



**Figure 1. Representation of microRNA biogenesis.** Firstly, *pri-miRNA* is produced by RNA polymerases by using DNA as a template in nuclear region. After processing of *pri-miRNA* by modulating enzymes, the yielded *pre-miRNA* is transported into the cytoplasm through a special molecular complex. *pre-miRNA* is further modified with other nucleolytic enzymes to obtain mature double-stranded miRNA. Thereafter, passenger strand (in gray) is degraded and guided strand is incorporated with other proteins to constitute miRISC complex which inhibits protein synthesis. miRISC; microRNA-induced silencing complex, *pri-miRNA*: primary microRNA, RNA pol-II, -III: RNA polymerases II and III, *pre-miRNA*: precursor microRNA (Terzi, 2020).

### Diagnostic and prognostic advantages of miRNAs in diseases

From the perspective of clinicians, surveillance of patients via monitoring non-invasive circulating biomarkers provides practicality and easier standardization between each measurement. Moreover, it relieves the patients' undesirable pains due to invasive sampling techniques e.g. puncturing for tissue biopsy or cerebrospinal fluid aspiration (Nagaraj, 2017). Of which, circulating miRNAs are becoming the novel candidates for diagnosis and/prognosis of acute or chronic diseases due to their easy accessibility and stability in bodily fluids (Ho, Clark, & Le, 2022).

Researchers have reported that certain miRNAs have been implicated in various diseases such as cardiovascular, renal, immunological, and neurological disorders, and cancers (Di Gregoli et al., 2017; Yamada et al., 2018). Furthermore, genome-wide, the presence of relatively smaller number of miRNAs compared to the number of encoding genes, i.e.  $\sim 1$  in  $10^{\text{th}}$ , makes them more unique to certain pathways and diseases (Nagaraj,

2017). It was previously claimed that the circulating miRNAs whose blood levels are not affected by confounder factors (age, BMI, gender, smoking, etc.) can be promising diagnostic markers in cancer patients (H. Wang, Peng, Wang, Qin, & Xue, 2018). In a clinical study, the differential expression of four miRNAs in urine (miR-125b-5p, miR-155-5p, miR-21-5p, miR-451-5p) has been linked to the disease in breast cancer patients (Erbes et al., 2015). In another study conducted with non-small cell lung cancer patients, the levels of miR-195-5p decreased in cancer patients who were at more severe stages and/or have metastasis at lymph nodes (Su, Zhang, Wang, & Hao, 2016). In this manner, the versatile expression pattern of miRNAs in bodily fluids can provide prognostic inferences about diseases. The need for searching novel biomarkers over protein biomarkers is due to saving time with higher sensitivity and accuracy in not only diagnosis but also prognosis and surveillance of patients' responses throughout treatment period. On the light of the latest findings, the multi-biomarker miRNA panels and libraries provide higher accuracy and sensitivity over single biomarker for disease characterization and follow ups (Table 1) such as early diagnosis of lupus nephritis and accurate diagnosis of breast cancer (Condrat et al., 2020; Sole, Moline, Vidal, Ordi-Ros, & Cortes-Hernandez, 2019; Xiong et al., 2017). Besides diagnostic purposes, miRNAs have been utilized in prognosis and follow ups to surveil response to cancer therapy.

*Table 1. Available miRNAs and their relevant panels and libraries utilized in pre-/clinical studies and applications*

<b>miRNAs/Panels/ Libraries</b>	<b>Action Mechanism</b>	<b>Clinical Use</b>	<b>Clinical Phase</b>
CogniMIR (panel)	Brain diseases	Diagnostic	Phase I
ThyraMIR/ThyGENX1 (panel)	Thyroid/pancreatic cancer	Diagnostic	In Use
miRview mets (library)	Tumor origin detection	Diagnostic	In Use
Reveal (library)	Thyroid	Diagnostic	In Use
OsteomiR (panel)	Osteoporosis	Diagnostic	In Use
ThrombomiR (panel)	Cardiovascular diseases	Diagnostic	In Use
MRG-106 (miR-155 LNA antagomiR)	Lymphoma and leukemia	Therapeutic	Phase I-II
MRG-107 (miR-155 antagomiR)	Amyotrophic lateral sclerosis	Therapeutic	Preclinical
MRG-110 (miR-92 LNA antagomiR)	Ischemia	Therapeutic	Phase I
Miravirsen (miR-122 antagomiR)	HCV	Therapeutic	Phase II
MRG-201 (miR-29a LNA agomiR)	Fibrosis	Therapeutic	Phase I
MRG-201 (miR-29b agomiR)	Fibrosis	Therapeutic	Phase II
Mesomir (miR-16 agomiR)	Mesothelioma	Therapeutic	Phase II
ABX464 (miR-124 inducer)	Crohn's disease and ulcerative colitis	Therapeutic	Phase II
MRX34 (miR-34a agomiR)	Cancers	Therapeutic	Phase I

miR: MicroRNA, antagomiR: anti-microRNAs, agomiR: miRNA mimics, HCV: Hepatitis C virus (Ho et al., 2022).

Dysregulation of certain miRNAs (miR-125b) or their multi-signatures (miR-372, -216, -145, -130, -20a) have been associated with the poor prognosis and/or resistance to chemotherapy in various cancer patients (H. Wang et al., 2012; Zhang et al., 2014). Furthermore, a previous study has reported several miRNAs, also designated as myomiRs (Vechetti et al., 2019), to be upregulated shortly after myocardial infarction (Condrat et al., 2020). As to neurological ailments, the diminished expression of miR-107 has been linked to the Alzheimer's disease, irrelevant to disease severity (W. X. Wang et al., 2008). Furthermore, in Parkinson's disease, augmented levels of three miRNAs have been reported to possess diagnostic poten-



tial (Margis, Margis, & Rieder, 2011). Today, there are several established miRNA panels in clinical use as a diagnostic tool for cancer, osteoporosis, and cardiovascular diseases (Ho et al., 2022). In the near future, the clinical potential of miRNAs will probably warrant us to present more options than today's alternatives for accurate diagnosis and prognosis of numerous other diseases.

### **Advantages of miRNAs in disease therapy**

Among miRNA modulation strategies, two of them have come forward; either by supplying abolished or insufficiently expressed miRNAs with their synthetic substitutes extrinsically, so called agomiRs, or by knocking down the upregulated miRNAs using their complementary anti-sense oligonucleotides so called antagomiRs (Ho et al., 2022). Until today, some candidate miRNAs, therapeutic potential of which have been demonstrated in in vitro and in vivo disease models, have been reached to the clinical trial phases (Table 1) such as an agomiR called miR-34 mimic (phase I) to suppress tumor progression and an antagomiR against miR-122 to diminish hepatitis C proliferation (Gebert et al., 2014; Rupaimoole & Slack, 2017). Moreover, an antagomiR targeting miR-92 has being tested in clinical phase trial I against ischemia-induced afflictions e.g. cardiovascular-based heart failures (Abplanalp et al., 2020). Addition to these clinical examples, some of other miRNAs are still under development for therapeutic purposes, of which miR-200b/c and miR-188-5p mimics have been reported to ameliorate memory loss and improve learning capacity by inhibiting A $\beta$  deposition in mouse model of Alzheimer's disease (Lee et al., 2016). In another in vivo animal model seeking for potential effective non-invasive therapeutics against age related macular degeneration claimed that, intravitreal administration of antagomiR targeting miR-142-3p decelerated macular degeneration progression by inhibiting neovascularization and inflammation (Roblain et al., 2021).

Owing to their smaller size, miRNAs can be handy tools in their manipulation, however, off-target issues, due to multiple complementation possibilities of a single miRNA with several mRNAs or vice versa, should be taken into consideration to prevent any possible undesired responses before their clinical use (Condrat et al., 2020).

### **Disadvantages of miRNAs for use in clinical purposes**

Beside their favorable characteristics to utilize them as potential biomarkers, miRNAs have some disadvantages to be considered and overcome. There are alternative methods for detection of cell-free circulating miRNAs as aforementioned however, there is not a gold-standard, verified, and universally-accepted detection method. The commonly used miRNA identification techniques include in situ hybridization (ISH) (Kloosterman,

Wienholds, de Bruijn, Kauppinen, & Plasterk, 2006; Romeo et al., 2018), northern blot analysis (Valoczi et al., 2004), next-generation sequencing (NGS) (J. Wang et al., 2015), miRNA microarray (J. Wang et al., 2014), and quantitative reverse transcriptase PCR (qRT-PCR) (Murray et al., 2015).

Among others, qRT-PCR is the closest option as the gold-standard method, however, sensing errors can take place and it has a high risk of contamination during the amplification steps (Gillespie, Ladame, & O'Hare, 2018). Besides, lack of a universal internal reference gene for normalization of miRNAs in circulation makes the analyses controversial and sometimes contradictory with each other (Schwarzenbach, da Silva, Calin, & Pantel, 2015).

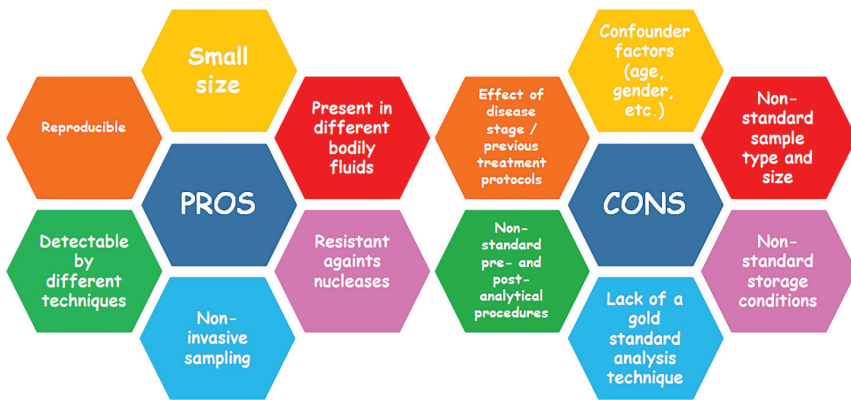
Northern blot is another traditional technique in which total RNA is denatured through a polyacrylamide gel then transferred to a membrane and hybridized with a UV-cross-linked, radioactively labeled probe. However, the classical protocol is time-consuming, necessitates large quantities of RNA sample, and usually fails to identify rare miRNAs and to separate different miRNA family members. So, new modification options should be experimented to improve its sensitivity and specificity (Pacak et al., 2016; Smoczynska et al., 2019).

miRNA expression can also be carried out by ISH method in which RNA in fixed tissue can be visualized in different cell types through different labeling methods (fluorescent, digoxigenin, radioactive, etc.). Tissue sample must be fixed adequately, embedded in paraffin, and should be sliced into suitable sections. So, ISH technique is time-consuming and prone to mistakes one of which is the fixation process. Fixation must not be too weak, which can result in the loss of signal and tissue structure, and too strong which will not allow the probe penetration (Javelle & Timmermans, 2012; Smoczynska et al., 2019).

NGS is the most highly sensitive and accurate technique that enables the examination and comparison of all miRNAs in test sample by a single experiment. The procedure consists of total RNA isolation, specific adaptor ligation, cDNA synthesis, amplification, gel purification, and sequencing. However, there are disadvantages of NGS too; one of which is the bias in ligation efficiency of adaptor depending on RNA sequence and structure and the other is overrepresentation of highly expressed miRNAs and underrepresentation of low expressed miRNAs. But the most important restrictive factor of NGS is its restricted accessibility which is highly limited because of high-cost especially when a particular miRNA is analyzed (Condrat et al., 2020; Gunaratne, Coarfa, Soibam, & Tandon, 2012; Smoczynska et al., 2019).

As mentioned above, miRNAs can be analyzed by different methods, along with this, consistent results cannot be obtained due to the differences

in experimental protocols. The non-standardization of pre- and post-analytical procedures, especially normalization, is an important hurdle to overcome. In addition, sample type and size, storage conditions, confounder factors (demography, gender, age, BMI, life style, etc.), stage of the disease or previous treatment protocols are among the major shortcomings (Moldovan et al., 2014; Saliminejad, Khorram Khorshid, & Ghaffari, 2019). To conclude, the potential of miRNAs as a non-invasive biomarker is promising specifically for diseases that require invasive interventions for their diagnostic, prognostic, and even therapeutic processes however, there are still many challenges that need to be resolved and standardized (Figure 2).



**Figure 2.** Advantages and disadvantages of circulatory miRNAs in clinical use.

## CONCLUDING REMARKS

There are several numbers of miRNAs have been described since their discovery which is a relatively young field but has a great potential about integrating their role with diagnosis, prognosis, and therapy processes of different pathologies. miRNAs are attracting a remarkable attention as a promising candidate in scientific realm due to their potential to be a new and alternative biomarker in early diagnosis which can be life-saving in diseases with high mortality such as cancer and cardiovascular diseases. The dramatic difference of its level between a pathological process and healthy period is the most important criteria in determining a biomarker. In addition, sample size, the selection of the correct analysis technique and its sensitivity and specificity, the low margin of error as possible, the standardization of the pre- and post-analytical techniques, low cost, and short processing time are as important as obtaining the study sample by non-invasive methods. Since circulatory miRNAs can be obtained

from body fluids by non-invasive techniques, they are in the focus of the scientific world as an important biomarker candidate. However, the field of miRNA is extremely new. They have many properties that need to be clarified in terms of their different aspects including its synthesis, structure, intracellular and extracellular functions, mechanisms of extracellular transport and complex structures during transport, reference range in intracellular and extracellular body fluids, demographic characteristics such as age and gender, lifestyle features such as smoking and diet, environmental factors, effect of previous treatment protocols, the stage of the disease, ethnicity, etc. To conclude, it is very essential to overcome the aforementioned uncertain issues about miRNAs by further studies, especially for pathologies requiring invasive techniques to be diagnosed, prognosed, and treated in order to avoid the potential physical, mental, and financial burden by which comfortable diagnostic and progression monitoring could be achieved from the earliest stage of the disease.

## REFERENCES

- Abplanalp, W. T., Fischer, A., John, D., Zeiher, A. M., Gosgnach, W., Darville, H., . . . Dimmeler, S. (2020). Efficiency and Target Derepression of Anti-miR-92a: Results of a First in Human Study. *Nucleic Acid Ther*, *30*(6), 335-345. doi:10.1089/nat.2020.0871
- Arroyo, J. D., Chevillet, J. R., Kroh, E. M., Ruf, I. K., Pritchard, C. C., Gibson, D. F., . . . Tewari, M. (2011). Argonaute2 complexes carry a population of circulating microRNAs independent of vesicles in human plasma. *Proc Natl Acad Sci U S A*, *108*(12), 5003-5008. doi:10.1073/pnas.1019055108
- Chen, X., Liang, H., Zhang, J., Zen, K., & Zhang, C. Y. (2012). Secreted microRNAs: a new form of intercellular communication. *Trends Cell Biol*, *22*(3), 125-132. doi:10.1016/j.tcb.2011.12.001
- Condrat, C. E., Thompson, D. C., Barbu, M. G., Bugnar, O. L., Boboc, A., Cretoiu, D., . . . Voinea, S. C. (2020). miRNAs as Biomarkers in Disease: Latest Findings Regarding Their Role in Diagnosis and Prognosis. *Cells*, *9*(2). doi:10.3390/cells9020276
- Di Gregoli, K., Mohamad Anuar, N. N., Bianco, R., White, S. J., Newby, A. C., George, S. J., & Johnson, J. L. (2017). MicroRNA-181b Controls Atherosclerosis and Aneurysms Through Regulation of TIMP-3 and Elastin. *Circ Res*, *120*(1), 49-65. doi:10.1161/CIRCRESAHA.116.309321
- Ecevit, H., Motor, S., & İzmirli, M. (2013). New Approaches from Gene to therapies: Non-Coding Nucleic Acids. *Medical journal of Mustafa Kemal University*, *4*(13), 27-36.
- Erbes, T., Hirschfeld, M., Rucker, G., Jaeger, M., Boas, J., Iborra, S., . . . Stickeler, E. (2015). Feasibility of urinary microRNA detection in breast cancer patients and its potential as an innovative non-invasive biomarker. *BMC Cancer*, *15*, 193. doi:10.1186/s12885-015-1190-4
- Fazmin, I. T., Achercouk, Z., Edling, C. E., Said, A., & Jeevaratnam, K. (2020). Circulating microRNA as a Biomarker for Coronary Artery Disease. *Bio-molecules*, *10*(10). doi:10.3390/biom10101354
- Gebert, L. F., Rebhan, M. A., Crivelli, S. E., Denzler, R., Stoffel, M., & Hall, J. (2014). Miravirsin (SPC3649) can inhibit the biogenesis of miR-122. *Nucleic Acids Res*, *42*(1), 609-621. doi:10.1093/nar/gkt852
- Gillespie, P., Ladame, S., & O'Hare, D. (2018). Molecular methods in electrochemical microRNA detection. *Analyst*, *144*(1), 114-129. doi:10.1039/c8an01572d
- Gunaratne, P. H., Coarfa, C., Soibam, B., & Tandon, A. (2012). miRNA data analysis: next-gen sequencing. *Methods Mol Biol*, *822*, 273-288. doi:10.1007/978-1-61779-427-8\_19
- Ha, M., & Kim, V. N. (2014). Regulation of microRNA biogenesis. *Nat Rev Mol Cell Biol*, *15*(8), 509-524. doi:10.1038/nrm3838

- Ho, P. T. B., Clark, I. M., & Le, L. T. T. (2022). MicroRNA-Based Diagnosis and Therapy. *Int J Mol Sci*, 23(13). doi:10.3390/ijms23137167
- Javelle, M., & Timmermans, M. C. (2012). In situ localization of small RNAs in plants by using LNA probes. *Nat Protoc*, 7(3), 533-541. doi:10.1038/nprot.2012.006
- Jin, Z. Q. (2021). MicroRNA targets and biomarker validation for diabetes-associated cardiac fibrosis. *Pharmacol Res*, 174, 105941. doi:10.1016/j.phrs.2021.105941
- Kharaziha, P., Ceder, S., Li, Q., & Panaretakis, T. (2012). Tumor cell-derived exosomes: a message in a bottle. *Biochim Biophys Acta*, 1826(1), 103-111. doi:10.1016/j.bbcan.2012.03.006
- Kloosterman, W. P., Wienholds, E., de Bruijn, E., Kauppinen, S., & Plasterk, R. H. (2006). In situ detection of miRNAs in animal embryos using LNA-modified oligonucleotide probes. *Nat Methods*, 3(1), 27-29. doi:10.1038/nmeth843
- Lee, K., Kim, H., An, K., Kwon, O. B., Park, S., Cha, J. H., . . . Kim, H. S. (2016). Replenishment of microRNA-188-5p restores the synaptic and cognitive deficits in 5XFAD Mouse Model of Alzheimer's Disease. *Sci Rep*, 6, 34433. doi:10.1038/srep34433
- Li, J., Liu, Y., Wang, C., Deng, T., Liang, H., Wang, Y., . . . Ba, Y. (2015). Serum miRNA expression profile as a prognostic biomarker of stage II/III colorectal adenocarcinoma. *Sci Rep*, 5, 12921. doi:10.1038/srep12921
- Lu, L., Li, J., Moussaoui, M., & Boix, E. (2018). Immune Modulation by Human Secreted RNases at the Extracellular Space. *Front Immunol*, 9, 1012. doi:10.3389/fimmu.2018.01012
- Margis, R., Margis, R., & Rieder, C. R. (2011). Identification of blood microRNAs associated to Parkinsonis disease. *J Biotechnol*, 152(3), 96-101. doi:10.1016/j.jbiotec.2011.01.023
- Moldovan, L., Batte, K. E., Trgovcich, J., Wisler, J., Marsh, C. B., & Piper, M. (2014). Methodological challenges in utilizing miRNAs as circulating biomarkers. *J Cell Mol Med*, 18(3), 371-390. doi:10.1111/jcmm.12236
- Morello, M., Minciacchi, V. R., de Candia, P., Yang, J., Posadas, E., Kim, H., . . . Di Vizio, D. (2013). Large oncosomes mediate intercellular transfer of functional microRNA. *Cell Cycle*, 12(22), 3526-3536. doi:10.4161/cc.26539
- Murray, M. J., Raby, K. L., Saini, H. K., Bailey, S., Wool, S. V., Tunnacliffe, J. M., . . . Coleman, N. (2015). Solid tumors of childhood display specific serum microRNA profiles. *Cancer Epidemiol Biomarkers Prev*, 24(2), 350-360. doi:10.1158/1055-9965.EPI-14-0669
- Nagaraj, S. (2017). Pros and Cons of miRNAs as Non-Invasive Circulatory Biomarkers. *Research & Reviews: Research Journal of Biology*, 5(1), 6-7.
- Okuyan, H. M., Dogan, S., Terzi, M. Y., Begen, M. A., & Turgut, F. H. (2021).

Association of serum lncRNA H19 expression with inflammatory and oxidative stress markers and routine biochemical parameters in chronic kidney disease. *Clin Exp Nephrol*, 25(5), 522-530. doi:10.1007/s10157-021-02023-w

- Pacak, A., Barciszewska-Pacak, M., Swida-Barteczka, A., Kruszka, K., Segal, P., Milanowska, K., . . . Szweykowska-Kulinska, Z. (2016). Heat Stress Affects Pi-related Genes Expression and Inorganic Phosphate Deposition/Accumulation in Barley. *Front Plant Sci*, 7, 926. doi:10.3389/fpls.2016.00926
- Roblain, Q., Louis, T., Yip, C., Baudin, L., Struman, I., Caolo, V., . . . Heymans, S. (2021). Intravitreal injection of anti-miRs against miR-142-3p reduces angiogenesis and microglia activation in a mouse model of laser-induced choroidal neovascularization. *Aging (Albany NY)*, 13(9), 12359-12377. doi:10.18632/aging.203035
- Romeo, P., Colombo, C., Granata, R., Calareso, G., Gualeni, A. V., Dugo, M., . . . Borrello, M. G. (2018). Circulating miR-375 as a novel prognostic marker for metastatic medullary thyroid cancer patients. *Endocr Relat Cancer*, 25(3), 217-231. doi:10.1530/ERC-17-0389
- Rupaimoole, R., & Slack, F. J. (2017). MicroRNA therapeutics: towards a new era for the management of cancer and other diseases. *Nat Rev Drug Discov*, 16(3), 203-222. doi:10.1038/nrd.2016.246
- Saliminejad, K., Khorram Khorshid, H. R., & Ghaffari, S. H. (2019). Why have microRNA biomarkers not been translated from bench to clinic? *Future Oncol*, 15(8), 801-803. doi:10.2217/fon-2018-0812
- Schulz, A., Loloi, J., Pina Martina, L., & Sankin, A. (2022). The Development of Non-Invasive Diagnostic Tools in Bladder Cancer. *Onco Targets Ther*, 15, 497-507. doi:10.2147/OTT.S283891
- Schwarzenbach, H., da Silva, A. M., Calin, G., & Pantel, K. (2015). Data Normalization Strategies for MicroRNA Quantification. *Clin Chem*, 61(11), 1333-1342. doi:10.1373/clinchem.2015.239459
- Smoczynska, A., Segal, P., Stepień, A., Knop, K., Jarmolowski, A., Pacak, A., & Szweykowska-Kulinska, Z. (2019). miRNA Detection by Stem-Loop RT-qPCR in Studying microRNA Biogenesis and microRNA Responsiveness to Abiotic Stresses. *Methods Mol Biol*, 1932, 131-150. doi:10.1007/978-1-4939-9042-9\_10
- Sole, C., Moline, T., Vidal, M., Ordi-Ros, J., & Cortes-Hernandez, J. (2019). An Exosomal Urinary miRNA Signature for Early Diagnosis of Renal Fibrosis in Lupus Nephritis. *Cells*, 8(8). doi:10.3390/cells8080773
- Su, K., Zhang, T., Wang, Y., & Hao, G. (2016). Diagnostic and prognostic value of plasma microRNA-195 in patients with non-small cell lung cancer. *World J Surg Oncol*, 14(1), 224. doi:10.1186/s12957-016-0980-8
- Terzi, M. Y. (2020). Clinical significance of miRNAs: A valuable diagnostic, prognostic, therapeutic tool. *Academic Studies in Health Sciences-II*, 295.

- Valadi, H., Ekstrom, K., Bossios, A., Sjostrand, M., Lee, J. J., & Lotvall, J. O. (2007). Exosome-mediated transfer of mRNAs and microRNAs is a novel mechanism of genetic exchange between cells. *Nat Cell Biol*, *9*(6), 654-659. doi:10.1038/ncb1596
- Valoczi, A., Hornyik, C., Varga, N., Burgyan, J., Kauppinen, S., & Havelda, Z. (2004). Sensitive and specific detection of microRNAs by northern blot analysis using LNA-modified oligonucleotide probes. *Nucleic Acids Res*, *32*(22), e175. doi:10.1093/nar/gnh171
- Varesi, A., Carrara, A., Pires, V. G., Floris, V., Pierella, E., Savioli, G., . . . Pascale, A. (2022). Blood-Based Biomarkers for Alzheimer's Disease Diagnosis and Progression: An Overview. *Cells*, *11*(8). doi:10.3390/cells11081367
- Vechetti, I. J., Jr., Wen, Y., Chaillou, T., Murach, K. A., Alimov, A. P., Figueiredo, V. C., . . . McCarthy, J. J. (2019). Life-long reduction in myomiR expression does not adversely affect skeletal muscle morphology. *Sci Rep*, *9*(1), 5483. doi:10.1038/s41598-019-41476-8
- Vickers, K. C., Palmisano, B. T., Shoucri, B. M., Shamburek, R. D., & Remaley, A. T. (2011). MicroRNAs are transported in plasma and delivered to recipient cells by high-density lipoproteins. *Nat Cell Biol*, *13*(4), 423-433. doi:10.1038/ncb2210
- Wang, H., Peng, R., Wang, J., Qin, Z., & Xue, L. (2018). Circulating microRNAs as potential cancer biomarkers: the advantage and disadvantage. *Clin Epigenetics*, *10*, 59. doi:10.1186/s13148-018-0492-1
- Wang, H., Tan, G., Dong, L., Cheng, L., Li, K., Wang, Z., & Luo, H. (2012). Circulating MiR-125b as a marker predicting chemoresistance in breast cancer. *PLoS One*, *7*(4), e34210. doi:10.1371/journal.pone.0034210
- Wang, J., Paris, P. L., Chen, J., Ngo, V., Yao, H., Frazier, M. L., . . . Sen, S. (2015). Next generation sequencing of pancreatic cyst fluid microRNAs from low grade-benign and high grade-invasive lesions. *Cancer Lett*, *356*(2 Pt B), 404-409. doi:10.1016/j.canlet.2014.09.029
- Wang, J., Raimondo, M., Guha, S., Chen, J., Diao, L., Dong, X., . . . Sen, S. (2014). Circulating microRNAs in Pancreatic Juice as Candidate Biomarkers of Pancreatic Cancer. *J Cancer*, *5*(8), 696-705. doi:10.7150/jca.10094
- Wang, K., Zhang, S., Weber, J., Baxter, D., & Galas, D. J. (2010). Export of microRNAs and microRNA-protective protein by mammalian cells. *Nucleic Acids Res*, *38*(20), 7248-7259. doi:10.1093/nar/gkq601
- Wang, W. X., Rajeev, B. W., Stromberg, A. J., Ren, N., Tang, G., Huang, Q., . . . Nelson, P. T. (2008). The expression of microRNA miR-107 decreases early in Alzheimer's disease and may accelerate disease progression through regulation of beta-site amyloid precursor protein-cleaving enzyme 1. *J Neurosci*, *28*(5), 1213-1223. doi:10.1523/JNEUROSCI.5065-07.2008
- Weber, J. A., Baxter, D. H., Zhang, S., Huang, D. Y., Huang, K. H., Lee, M. J., . . . Wang, K. (2010). The microRNA spectrum in 12 body fluids. *Clin Chem*,



56(11), 1733-1741. doi:10.1373/clinchem.2010.147405

- Xiao, K., Lu, D., Hoepfner, J., Santer, L., Gupta, S., Pfanne, A., . . . Thum, T. (2019). Circulating microRNAs in Fabry Disease. *Sci Rep*, 9(1), 15277. doi:10.1038/s41598-019-51805-6
- Xiong, D. D., Lv, J., Wei, K. L., Feng, Z. B., Chen, J. T., Liu, K. C., . . . Luo, D. Z. (2017). A nine-miRNA signature as a potential diagnostic marker for breast carcinoma: An integrated study of 1,110 cases. *Oncol Rep*, 37(6), 3297-3304. doi:10.3892/or.2017.5600
- Yamada, S., Hsiao, Y. W., Chang, S. L., Lin, Y. J., Lo, L. W., Chung, F. P., . . . Chen, S. A. (2018). Circulating microRNAs in arrhythmogenic right ventricular cardiomyopathy with ventricular arrhythmia. *Europace*, 20(F11), f37-f45. doi:10.1093/europace/eux289
- Zen, K., & Zhang, C. Y. (2012). Circulating microRNAs: a novel class of biomarkers to diagnose and monitor human cancers. *Med Res Rev*, 32(2), 326-348. doi:10.1002/med.20215
- Zhang, J., Zhang, K., Bi, M., Jiao, X., Zhang, D., & Dong, Q. (2014). Circulating microRNA expressions in colorectal cancer as predictors of response to chemotherapy. *Anticancer Drugs*, 25(3), 346-352. doi:10.1097/CAD.0000000000000049





## **CHAPTER 3**

### **NANO PARTICLES AND GREEN SYNTHESIS**

*Nurhan GÜMRÜKÇÜOĞLU<sup>1</sup>*

---

<sup>1</sup> Prof. Dr., ORCID ID [https:// orcid.org/0000-0002-9669-6318](https://orcid.org/0000-0002-9669-6318) Karadeniz Technical University, Vocational School of Health Sciences, Department of Medical Services and Techniques, Trabzon, TURKEY ngumrukuoglu@ktu.edu.tr

Natural materials are the simplest way to understand nanoscience. For example, microscope images become very different when starting from macro objects (like a plant leaf) and going down to finer and finer tissues in magnified images. Every material can be defined in the nanoscale. “Natural nanomaterials” are materials of the natural world (animals and minerals); It is not handmade and has remarkable properties because of its inherent nanostructure.

The properties and identity of a substance depend on its molecular structure. The nanostructure of a biological material results from its supramolecular organization; In such an organization, tens to hundreds of molecules in shape and form are at the nanoscale level. With the interaction of these nanostructures with light, water and other materials, natural materials with impressive properties in the macrostore can be obtained.

In everyday life, we come across hundreds of examples of nanoscience, from lizards that can walk on ceilings despite gravity to iridescent butterflies to glowing fireflies at night.

Some natural nanomaterials are briefly summarized below.

Nanoparticles formed from natural erosion and volcanic events.

·Minerals such as nanostructured clays: Clays are a type of layered silicate that is described as a fine 2D crystalline structure.

Natural colloids such as milk and blood (liquid collides), fog (aerosol type), gelatin: The nanoparticles in these materials are dispersed in their environment (liquid or gas), not in solution form. Light scattering is observed in natural colloids, and their color (as in blood and milk) is often due to light scattering by the nanoparticles it contains.

Mineralized natural materials such as shell, coral and bone: Three-dimensional structures formed spontaneously from calcium carbonate crystals with other natural materials (such as polymers).

Materials such as skin, claws, beak, feathers, muzzle, hair: These materials consist of very flexible proteins such as keratin, elastin and collagen.

·Paper and cotton are mostly cellulose. The high strength, durability and absorbance of cotton are due to the nanoscalar arrangement of the fibers.

·Insect wings and opals: The colors seen in opals and butterflies are directly related to their fine structure.

·Spider silk: Silk is the strongest material known; It is five times stronger than steel of the same weight. The extraordinary property of spider silk is due to the organization of proteins at the nanoscale level. Lotus

leaf and nasturtium: The nanostructure of the leaves of these plants gives them exceptional surface properties and “self-cleaning” ability.

The lizard foot is a surprising and astonishing example of the relationship between function and nanostructure.

Natural materials are inspiring not only in understanding the amazing properties of biological materials, but also in the design and engineering of new materials with advanced properties. The remarkable properties of many biological materials stem from their complex and often hierarchical structure. They are extremely adaptable and multifunctional. They form a well-established model in the design of many advanced artificial materials (solar cells, fuel cells, textiles, drug delivery systems, etc.). The inspiration in nature is based on some simple laws: Nature exists by sunlight; uses only as much energy as it needs; natural nanomaterials are highly energy efficient. Everything in nature is ‘recyclable’, waste products are minimal. Nature is collaborative, although it preserves diversity and local expertise.

Nanotechnology can be defined as manipulating and controlling the size of matter to fall in the range of 1-100 nm [1]. NPs, which form the basis of nanotechnology, have remarkable properties due to their specific size, shape, composition, greater surface area/volume ratio and purity of individual components [2]. These properties of NPs are due to the different methods used in the synthesis phase. These features are; It enabled the preparation of antimicrobial, anticancer, anti-inflammatory, surfactant, drug carrier and pharmacological products. NPs produced from biological materials are known as biogenic NPs and the associated synthesis process is called green synthesis. Green synthesis of NPs involves the use of prokaryotic/eukaryotic cells or extracted biomolecules that act as reducing agents [3]. Plant biomass/extract has several inert advantages over other microscopic organisms in NP synthesis from a variety of biological materials. Plant-mediated biosynthesis of metallic NPs occurs through biomolecules in plant biomass that contain organic functional groups [4]. In addition to the synthesis method, the techniques used are an important element that enables NPs to be in the nanoscale range.

The term “nanoparticle” is used to describe materials smaller than 100 nm, which are used as building blocks in nano research [5]. NPs have distinctly different physicochemical and morphological properties such as small sizes, large surface areas containing large amounts of binding sites, electronic structure, and interfacial reactivity [6]. As the sizes and shapes of NPs change, the physical, chemical, optical, electrical, thermal, catalytic, bioactivity and toxicity properties of the particles also change. In order to prevent particle growth, NPs of desired size can be produced by using separating agents.




Figure 1. Silver (Ag) and gold (Au) nanoparticles of different shapes and sizes colors [7]

In addition to these; NPs consisting of various particles can have different catalytic, magnetic, optical properties compared to NPs consisting of a single type of particle [8]. Since approximately 40-50% of NP atoms are on the surface, its reactivity is high [9]. These properties increase the importance of NPs compared to other materials.

### Nanomaterials fabrication

Nanomaterial properties are highly dependent on the shape and size of the material, which can be controlled by the appropriate fabrication technique. Extensive research has been done using different techniques such as chemical vapor deposition, hydrothermal synthesis, atomic layer deposition, electrochemistry on the synthesis of different nanomaterials such as nanotubes, nanowires, nanolayers and nanoparticles.

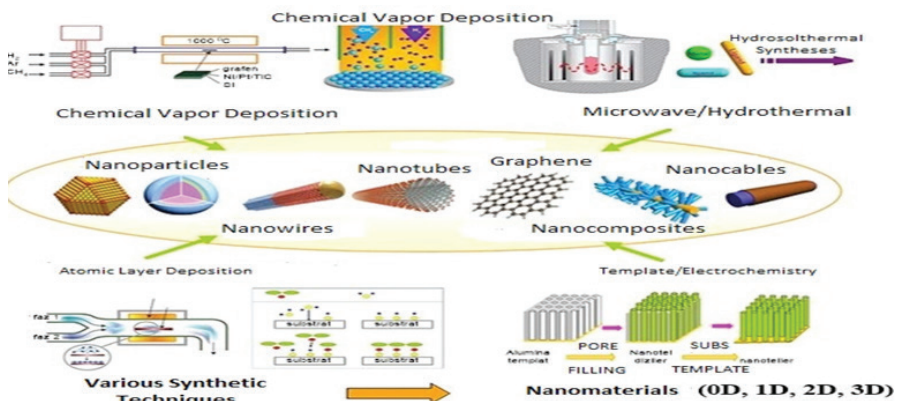


Figure 2. Different geometries of nanomaterials synthesized with different production techniques [10]

### ***Chemical methods***

Chemical methods for the synthesis of NPs include; chemical reduction, microemulsion, electrochemical and thermal decomposition. It is one of the commonly preferred methods in the synthesis of metal particles due to the ease of use of equipment in chemical reduction with inorganic and organic agents. Sodium borohydride [11], potassium bitartrate [12], methoxy polyethylene glycol, trisodium citrate dihydrate [13], ascorbate and elemental hydrogen are commonly used reducing agents in this method. These chemicals reduce metallic ions and cause the formation of metallic NPs. It is synthesized gold NPs (AuNPs) using sodium borohydride as a reducing agent to produce monodispersed particles that are easy to disperse in organic solvent and re-decompose as pure powders [14]. In electrochemical synthesis method, it is the process of passing an electric current between two or more electrodes called anode and cathode in an electrolyte. In this technique, the anode can be oxidized to metal ion species in the electrolyte and the metal ion is then reduced to metal by the cathode with the support of a stabilizer. Synthesis occurs at the electrode-electrolyte interface [15]. To control the particle size, the intensity of the electric current and voltage supply can be varied [16]. NPs produced by this method have a uniform size distribution and high purity due to good size control, but are simple, inexpensive, environmentally friendly and cost-effective [17]. Electrochemical procedure is used based on dissolving a metal anode in an aprotic solvent to prepare silver NPs (AgNP) ranging from 2 to 7 nm. Researchers have also shown that it is possible to obtain different Ag particle sizes by varying the current density. Although the chemical synthesis route has several benefits, the use of high amounts of solvents, surfactants and other chemicals limits the bioactive application areas of synthesized NPs [18]. Therefore, some researchers have tried to develop clean, biocompatible, non-toxic and environmentally friendly methods for NP synthesis [19].

### ***Mechanisms for the Formation of Natural Nanoparticles (DNP)***

The classification of DNP and all the possible pathways leading to its formations are complex and enormous. It is seen that the formation of DNP occurs in chemical elements/species and in a wide variety of mechanisms, processes and conditions in all areas surrounding the world. The aforementioned syntheses are from molecular/ionic, it can take place with a bottom-up approach, starting from species, for example, the formation of iron hydride DNP due to their microbiological activities, or the formation of halide and aqueous sulfate DNP from the evaporation of sea spray.

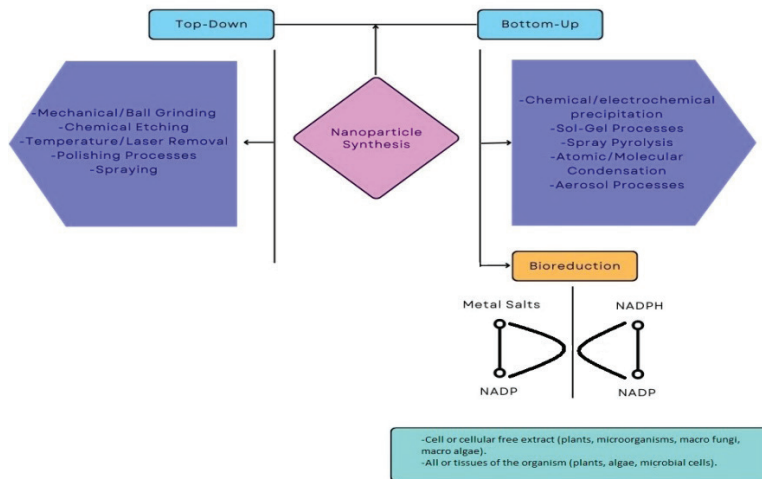


Figure 3. Ways to obtain nanoparticles [20]

Synthesis can also occur with a top-down approach, starting with larger fragments such as nanosized mineral fragments produced by wind erosion over deserts or the formation of carbon nanoparticles from the combustion of biomass.

### ***Green Method (Biosynthesis)***

In order to select greener materials, the effects of nanotechnological materials on design should be considered in terms of environmental, cost and performance of a material. Material shortages and abundance, rapidly renewable materials, embedded energy, recycling should have knowledge about recycled materials and toxicity [21].

### ***Green Nanotechnology and Green Nano-materials***

The findings obtained from the studies have led to the formation of the concept of Green Nanotechnology, which is pro-environmental, low toxicity, based on the production of nanoparticles from living cells. This concept is expressed as working techniques that help solve the problems caused by waste products, do not pose a risk to human health, and examine practical techniques within the field of nanotechnology. Green plant extracts and microorganisms are widely used in green nanotechnology studies.

Recent advances in nanoscience include characterizing and using naturally occurring nanomaterials; and also engineered nanoparticles (e.g. metal oxides, carbon nanotubes and buckminsterfullerene) provides various possibilities to produce and market. It is now possible to control the chemical and physical properties of nanoparticles and thus to see nanotechnol-



ogies in green building applications. New generation materials reinforced with nanoparticles are used for clean energy, national security and economic development. The superior mechanical, thermal, electrical, magnetic and electromagnetic properties of these materials have been proven.

Environmentally friendly synthesis methods are synthesis using biological resources. Sources such as plants, algae, bacteria, viruses, fungi are used for the synthesis of NPs [23]. Among them, synthesis studies with herbal sources are more acceptable, simple and inexpensive. Since it is a natural process, the NPs obtained here are biocompatible. There is no risk of infection, it does not require laboratory conditions [24].

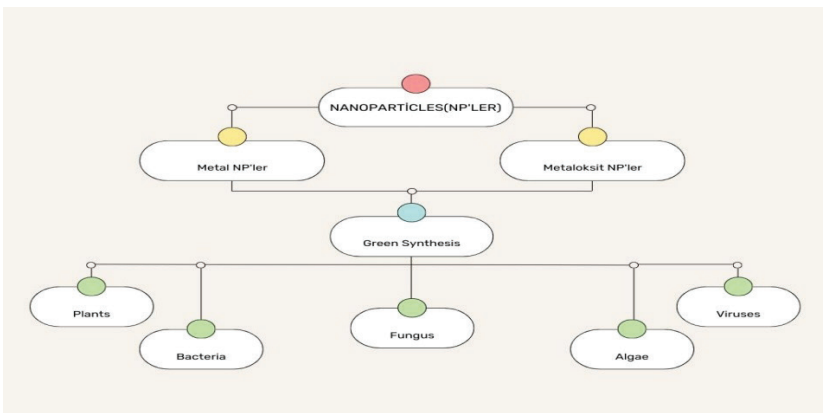


Figure 4. Biological resources used for green synthesis of nanoparticles [23]

Green synthesis of NPs in bacteria [25], fungi, yeast [26], virus [27], microalgae [28] and plant biomass/extract [29] using different biomaterials. Thanks to the green method, NPs with different shapes, sizes, contents and physicochemical properties can be synthesized. Molecules such as proteins, enzymes, phenolic compounds, amines, alkaloids and pigments found in plants and microorganisms produce NP in one step by reducing [30].

Microorganisms are capable of synthesizing NPs under ambient conditions without toxic chemicals and harsh conditions. The properties of NPs formed in this way are quite similar to those of chemically synthesized NPs, and microorganisms perform their synthesis by bioextraction and enzyme-mediated reduction of minerals [31]. Proteins, carbohydrates and biomembranes are involved in biological reduction. Reductases in microorganisms, such as sulfate reductase, play an important role in many biological reduction processes in the synthesis of NPs [32]. Compared to other natural resources, bacteria have a wide field of research because they

are relatively easily manipulated for green synthesis. Many bacteria have the potential to produce NPs with various morphologies at room temperature and mild culture conditions [33]. The places where NPs are formed vary according to the reducing species of bacteria. Reducing enzymes or functional groups located inside the cell or in the cell wall are involved in the intracellular formation. Therefore, the NPs formed are in limited space and sometimes difficult to remove from the cell. NPs are formed extracellularly, usually when reducing enzymes dissolve in solvent or when bacteria release their enzymes out of the cell [34]. It is known that even dead/inactive bacterial biomass show the potential to reduce metal ions to NPs due to the presence of certain organic functional groups in the cell wall. As with other green methods, algae and NP production are environmentally friendly practices. Algae have an important place in applications because they are resistant to harsh environmental conditions and contain phenolic compounds and organic substances, which are reducing agents in NP synthesis [2]. The literature reveals that microalgae have been widely used for the biosynthesis of AgNPs in recent years. It is reported the biosynthesis of AgNPs using the aqueous extract of *Neochloris oleoabundans* [35]. In studies, it is stated that AgNPs synthesized by microalgae are effective in controlling pathogens in agricultural applications [36].

NP production by fungi can be intracellular or extracellular. The extracellular route is very fast compared to the intracellular route, but larger size NPs can be synthesized by the extracellular route. It is reported that this difference in size is likely due to nucleation of particles within the fungus [37]. Among the important advantages of fungi are easy production, biomass formation, extracellular enzymes released during the production process, and easy large-scale production. While NPs are formed inside the cell in intracellular production, they are formed on the other surface of the cell by the use of supernatant or filtrate in extracellular production. It is more difficult to obtain intracellularly produced NPs due to the nature of the work [38]. This provides a distinct advantage to extracellular applications. In another study, it is successfully synthesized spherical, 17.5 nm-sized NPs with anticancer activity by extracellular production using *Pleurotus Ostreatus* [39]. There are studies on the biogenic synthesis of metal NPs from actinomyces and their biomedical and therapeutic applications. Enzymes secreted from the cell wall and cell membrane in actinomyces culture help to reduce silver and gold ions, and proteins help stabilize NP formation [40].

The use of plant biomass/extracts from the biomaterials used in the biosynthesis of NPs has been accepted as a more reliable and environmentally friendly method. Plant mediated biosynthesis compared to other biomaterials; It has advantages such as safe use, cost-effectiveness, simple

process, elimination of elaborate maintenance of cell cultures, rapid synthesis, environmentally sensitive, more stable NPs, better control over NP size and shape, and more suitable for large-scale synthesis. The biocompatibility of phytonanotechnology and the use of water as a solvent increase the use of the synthesized NPs in the biomedical and environmental fields by providing a non-toxic structure [38]. Different plant parts such as stem, leaf, flower, fruit, root, latex, seed and seed coat can be used for NP synthesis. However, it is an important advantage that the synthesis processes using plant extracts are easier and less costly compared to methods based on microbial processes or using the whole plant. It is studied the synthesis of AuNPs using rose petals and determined that the flower extract contains abundant sugar and protein, therefore, tetrachloroaurate salt is responsible for the reduction of AuNPs [41]. In traditional chemical and physical methods; Reducing agents involved in the reduction of metal ions and stabilizing agents added to prevent unwanted agglomeration of synthesized NPs involve toxicity risk for the environment and the cell. In the production of NPs with biocompatibility by the green synthesis method, these agents are naturally present in the biological organisms [42].

### ***Advantages of Green Synthesis***

Although green synthesis is less efficient than other methods under current conditions, it is widely preferred because it does not require energy and does not use toxic chemicals and solvents in environmentally friendly conditions, making the process safer [43]. In addition, green synthesized NPs have higher antimicrobial activity compared to NPs synthesized by other methods. This antimicrobial activity is thought to occur as a result of the synergistic effect of several proteins that function in capping and subsequently stabilizing biosynthesized NPs [44]. Fundamental properties of NPs such as electronic, optical, magnetic and catalytic properties are controlled by NP size and shape. Due to the ease of controllability of biological systems, green synthesis of NPs is a more suitable method than chemical synthesis [45].

### ***Critical Parameters for Green Synthesis of Nanoparticles***

In recent studies, it has been tried to establish a rationally stable system to produce NPs with homogeneous size and morphology [46]. Reaction temperature, pH, incubation time and concentration can cause significant changes in the shape, size, stability and nucleation process of synthesized NPs. The highest temperature required for optimal growth of the microorganism is preferred in the studies. Because the enzyme responsible for NP synthesis is more active at high temperature. At the same time, pH is one of the most influential factors in this technique, and different NPs can be synthesized at different pH values. In plants, pH changes cause differences

in the load of natural phytochemicals. This may affect the morphology and yield of NPs by reducing their binding ability and metal ions during NP synthesis. For example, in *Avena sativa* extract, many small-sized AuNPs were formed at pH 3 and 4, while NP aggregation was observed at pH 2. Therefore, it has been suggested that at very low pH values, NP aggregation dominates during reduction [38]. The reaction time also plays an important role in controlling the size and shape for the synthesis of metallic NPs. It is showed that the extracellular synthesis of AgNPs using *Vibrio alginolyticus* supernatant increased the yield with increasing reaction time and did not cause a significant shift in the UV-visible spectroscopy (UV-Vis) peak. Conversely, they concluded that intracellular synthesis produced a shift towards higher wavelength in the UV-Vis peak and time-dependent efficiency was observed in extracellular AgNP synthesis without affecting the size of NPs [47]. The incubation period of NPs synthesized using plant extract was investigated to observe the morphological characteristics and changes in the qualities of the NPs [48]. Other factors such as storage conditions and exposure to light also affect the reaction time of copper oxide Np (CuONP). It has been stated that a long incubation period causes agglomeration and shrinkage of the particles. The reactant concentration (biomolecules or metal salts) significantly affects the formation of metallic NPs. In a study, it was observed that the size and shape of AuNPs were significantly affected by the change of *Penicillium brevicompactum* supernatant and gold salt concentration in the reaction medium.

### ***Nanoparticle Enhanced Materials***

Recent advances in nanoscience have made naturally occurring nanomaterials qualify and use; as well as providing various possibilities to produce and market the designed nanoparticles (eg metal oxides, carbon nanotubes and bukminsterfullerene). It is now possible to control the chemical and physical properties of nanoparticles and thus to see nanotechnologies in green building applications. New generation materials reinforced with nanoparticles are used for clean energy, national security and economic development. The superior mechanical, thermal, electrical, magnetic and electromagnetic properties of these materials have been proven.

### ***Applications of Nanoparticles***

Particles produced in nano size have many uses. There are different methods of obtaining these particles. Methods using biological systems as environmentally friendly reducing agents are of great interest. Being biocompatible and low cytotoxicity is a must for nanoparticles involved in biomedical processes. When nanoparticles produced by biogenic techniques are compared with physicochemically produced nanoparticles, the toxic structures of undesired formations attached to nanostructures during

physicochemical formation constitute a limitation for biomedical processes. The fact that they have practical and environmentally friendly production techniques and the economical and biocompatible contents of the particles obtained bring many advantages in the synthesis of nanoparticles with green nanotechnology.

Metal NPs are widely used in biomedical, pharmaceutical, medicine, agriculture, environment, energy, etc. Its use in fields is increasing day by day [49]. AuNPs have been applied for the specific release of drugs such as paclitaxel, methotrexate and doxorubicin [50]. In addition, AgNPs are among the most attractive nanomaterials. It is widely used in many biomedical applications, including diagnosis, treatment, drug delivery, medical device coating, and personal health care. Zinc and titanium NPs with biocompatible, non-toxic, self-cleaning, skin-compatible, antimicrobial and dermatological properties are used in biomedical, cosmetic, ultraviolet blocking agents [51].

Dose optimization is necessary for drugs to reach the level of bioavailability, and the drug taken must have a specific target. That is, theoretically high doses of the drug should be taken to achieve proper bioavailability, but this will cause more side effects. Region-specific drug distribution can be achieved with NPs [52]. Thanks to this approach, appropriate drug dosage will be used and side effects will be significantly reduced. The use of small amounts of drugs for specific targets both reduces drug costs and increases patient comfort.

### ***Environmental nanotechnology***

How will nanotechnology affect our lives? In this section, nanotechnology is discussed not in terms of technology, but in terms of its very important health and environmental effects, which must be taken into account. People are very excited and enthusiastic about the visions of nanotechnology; however, there is also a natural concern about the environmental problems that the developing technologies may create. This concern is increasingly being focused on to ensure a healthy development.

The environmental impact of nanotechnology has become an increasingly active area of research. As with many other technologies, a large gap still remains, from research laboratories to the use of nanotechnological products and the manufacture of solutions. However, the focus here will be on potential health and environmental impacts.

Until recently, the possible adverse effects of nanomaterials on human health and the environment were highly speculative and unproven. However, in the last few years, some studies on the subject have shown that some specific nanomaterials can cause adverse effects in humans and

animals, with special associations with small particles in the past negative experiences of some people.

Some types of nanoparticles are benign and FDA-approved, such as paints and sunscreen lotion, etc. it is known to be used for. But there are also dangerous nanosized particles and chemicals known for many years to accumulate in the food chain: such as asbestos, diesel particulate matter, ultrafine particles, DDT and lead.

How do nanotechnological studies and applications help to treat, for example, cancer, and under what conditions does it cause cancer? When we consider the ecological footprints of the life cycle of nanoparticles, is there an apparent ecological benefit of a nanoparticle that enhances catalytic reactions or not? it is these and many other questions that researchers are beginning to seek answers to.

*Table 1. Ways nanoparticles can escape to the environment*

<b>Product</b>	<b>Samples</b>	<b>Potential release and exposure</b>
cosmetics	absorbs TiO <sub>2</sub> and ZnO in sunlight	applied directly to the skin and washed off late.
fuel additives	cerium oxide additives	exhaust emission
paints and coatings	antibacterial silver nanoparticle coatings and hydrophobic nano coatings.	abrasion and washing releases particles or components such as Ag. <sup>+</sup>
clothes	antibacterial silver nanoparticle coatings and hydrophobic nano coatings.	skin absorption; abrasion and washing releases particles or components such as Ag. <sup>+</sup>
electronics	Carbon nanotubes are recommended for use in commercial electronics.	disposal can cause emissions.
toys, miscellaneous materials and kitchen utensils	sporting goods such as golf clubs can be made from carbon nanotubes.	disposal can cause emissions.
combustion processes	diesel combustion and many processes can create nanometric particles.	exhaust emission
soil regeneration	nanoparticles for soil regeneration.	high local emission and exposure at the place of use.
nanoparticle production	production is usually produced with unused products.	A large amount of nanoparticles can diffuse locally in wastewater and exhaust gases.

It has been suggested that nanotechnology has a wide variety of potential positive effects on the environment, either directly or indirectly. Special topics of environmental importance include potentially improved efficiency of energy generation, reduction of energy use of products (e.g., functionalization of surfaces), improvement of soil pollution, better perception of the functionality of materials, monitoring and improvement of the environment. In addition, green engineering and chemistry principles have begun to integrate into the development of nanomaterials; which means that nanotechnology could lead to more environmentally friendly production methods.

Some situations that cause human and environmental exposure to nanoparticles are shown in the table. The main problem is that experience with nanoparticles and bulk materials is not comparable; their chemical properties can be quite different. For example, anti-bacterial silver nanoparticles dissolve in acids (which gives it high reactivity), whereas bulk silver is insoluble.

## CONCLUSION

The size, shape and composition of NPs affect the physical, chemical, bioactive, optical, electrical, catalytic and toxicity properties of the particles. Therefore, new research is needed to fully understand their synthesis, characterization and possible toxicity. Green synthesis using plant extracts; It is the most practical method used to obtain NPs easily, economically and environmentally friendly without the use of high pressure, temperature, energy and toxic chemicals. We expect that with ongoing and newly planned studies, the synthesis of new generation NP-based drugs will be realized, thus contributing to the development of new targeted treatment protocols.

How we manufacture, design, use and reuse products and materials requires rethinking. If the world is to prosper, wealth sharing must be achieved through a new consumption model without waste, pollution and social and environmental costs. Beyond the applications in materials science, there is also a serious issue for the interaction between nanoscience and energy. However, it still takes a long time for newly discovered materials to move from the laboratory to the market.

For the evaluation of a material, what it contains, how it is made; It is necessary to know the amount of resources used during production and transportation, the emissions that occur, what type of energy is used and what the residues are. This means that access to product information documentation is required. Product information documentation is a difficult activity to achieve and is not always a smooth process.

## REFERENCES

- [1] Ahmed, S., Chaudhry, S. A., Ikram, S. 2017. A review on biogenic synthesis of ZnO nanoparticles using plant extracts and microbes: a prospect towards green chemistry. *J Photochem Photobiol B*, 166: 272-284.
- [2] Khan, A. U., Khan, M., Malik, N., Cho, M. H., Khan, M. M. 2019. Recent progress of algae and blue-green algae-assisted synthesis of gold nanoparticles for various applications. *Bioprocess Biosyst Eng*, 42: 1-15.
- [3] Jeevanandam, J., Chan, Y. S., Danquah, M. K. 2016. Biosynthesis of metal and metal oxide nanoparticles. *Chem Bio Eng Rev*, 3 (2): 55-67.
- [4] Irvani, S. 2011. Green synthesis of metal nanoparticles using plants. *Green Chem*, 13: 2638-2650.
- [5] Manivasagan, P., Venkatesan, J., Sivakumar, K., Kim, S. K. 2016. Actinobacteria mediated synthesis of nanoparticles and their biological properties: A review. *Crit Rev in Microbiol*, 42 (2): 209-221.
- [6] Bogunia-Kubik, K., Sugisaka, M. 2002. From molecular biology to nanotechnology and nanomedicine. *Biosystems*, 65 (2-3): 123-138.
- [7] <http://sciencegeist.net/the-shape-of-things/>
- [8] Shin, S. W., Song, I. H., Um, S. H. 2015. Role of physicochemical properties in nanoparticle toxicity. *Nanomaterials*, 5 (3): 1351-1365.
- [9] Sneed, B. T., Young, A. P., Tsung, C. K. 2015. Building up strain in colloidal metal nanoparticle catalysts. *Nanoscale*, 7: 12248-12265.
- [10] <http://substance-en.etsmti.ca/nanoscience-nanotechnology/>
- [11] Kim, J. S., Kuk, E., Yu, K. N., Kim, J. H., Park, S. J., Lee, H. J. 2007. Antimicrobial effects of silver nanoparticles. *Nanomed NBM*, 3 (1): 95-101.
- [12] Tan, Y., Dai, Y., Li, Y., Zhua, D. 2003. Preparation of gold platinum, palladium and silver nanoparticles by the reduction of their salts with a weak reductant-potassium bitartrate. *J Mater Chem*, 13: 1069-1075.
- [13] Rivas, L., Sanchez-Cortes, S., Garcia-Ramos, J. V., Morcillo, G. 2001. Growth of silver colloidal particles obtained by citrate reduction to increase the raman enhancement factor. *Langmuir*, 17 (3): 574-577.
- [14] Brust, M., Walker, M., Bethell, D., Schiffrin, J., Whyman, R. 1994. Synthesis of thiol derivatised gold nanoparticles in a two-phase liquid/liquid system. *J Chem Soc Chem Comm*, 7 (7): 789-912.
- [15] Ramimoghadam, D., Bagheri, S., Hamid, SBA. 2014. Progress in electrochemical synthesis of magnetic iron oxide nanoparticles. *J Magn Magn Mater*, 368: 207-229.
- [16] Sharma, A., Goyal, A. K., Rath, G. 2018. Recent advances in metal nanoparticles in cancer therapy. *J Drug Target*, 26 (8): 617-32.
- [17] Kefeni, K. K., Msagati, TAM., Mamba, B. B. 2017. Ferrite nanoparticles:



Synthesis, characterisation and applications in electronic device. *Mat Sci Eng B-Solid*, 215: 37–55.

- [18] Narayanan, K. B., Sakthivel, N. 2010. Biological synthesis of metal nanoparticles by microbes. *Adv Coll Interf Sci*, 156 (1-2): 1-13.
- [19] Dauthal, P., Mukhopadhyay, M. 2016. Noble metal nanoparticles: plant-mediated synthesis, mechanistic aspects of synthesis, and applications. *Ind Eng Chem Res*, 55 (36): 9557-9577.
- [20] Kumar, A., Chisti, Y., and Chand, U. 2013. Synthesis of metallic nanoparticles using plant extracts. *Biotechnology Advances*, 31 (2), 346-356.
- [21] Autodesk, 2014. Cradle to Cradle Product Design: Designing for a Circular Economy. *Course material of Autodesk Design Academy*.
- [22] Sunderem, V., Thiagarajan, D., Lawrence, A. V., Mohammed, S. S. S., and Selvaraj, A. 2019. In-vitro antimicrobial and anticancer properties of green synthesized gold nanoparticles using *Anacardium occidentale* leaves extract. *Saudi Journal of Biological Sciences*, 26 (3), 455-459.
- [23] Shankar, P. D., Shobana, S., Karuppusamy, I., Pugazhendhi, A., Ramkumar, V. S., Arvindnarayan, S., and Kumar, G. 2016. A review on the biosynthesis of metallic nanoparticles (gold and silver) using bio-components of microalgae: Formation mechanism and applications. *Enzyme and Microbial Technology*, 95, 28-44.
- [24] Hulkoti, N. I., Taranath, T. C. 2014. Biosynthesis of nanoparticles using microbes-a review *Colloids Surf B: Biointerfaces*, 121: 474-483.
- [25] Dujardin, E., Peet, C., Stubbs, G., Culver, J. N., Mann, S. 2003. Organization of metallic nanoparticles using tobacco mosaic virus templates. *Nano Lett*, 3: 413-417.
- [26] Schrofel, A., Kratosova, G., Krautova, M., Dobrocka, E., Vavra, I. 2011. Biosynthesis of gold nanoparticles using diatoms–silica-gold and EPS-gold bionanocomposite formation. *J Nanoparticle Res*, 13: 3207-3216.
- [27] Mittal, A. K., Chisti, Y., Banerjee, U. C. 2013. Synthesis of metallic nanoparticles using plant extracts. *Biotechnol Adv*, 31: 346-356.
- [28] Parveen, K., Banse, V., Ledwani, L. 2016. Green synthesis of nanoparticles: Their Advantages and Disadvantages. 2nd International Conference on Emerging Technologies: Micro to Nano, India.
- [29] Bäuerlein, E. 2003. Biomineralization of unicellular organisms: An unusual membrane biochemistry for the production of inorganic nano- and microstructures. *Angew Chem*, 42: 614-641.
- [30] Han, G., Ghosh, P., Rotello, V. M. 2007. Multi-functional gold nanoparticles for drug delivery. *Adv Exp Med Biol*, 620: 48-56.
- [31] Thakkar, K. N., Mhatre, S. S., Parikh, R. Y. 2010. Biological synthesis of metallic nanoparticles. *Nanomedicine: NBM*, 6: 257-262.

- [32] Nath, D., Banerjee, P. 2013. Green nanotechnology - a new hope for medical biology. *Environ Toxicol Pharmacol*, 36 (3): 997-1014.
- [33] Bao, Z., Lan, CQJ., Biointerfaces, S. B. 2018. Mechanism of light-dependent biosynthesis of silver nanoparticles mediated by cell extract of *Neochloris oleoabundans*. *Colloids Surf B Biointerfaces*, 170: 251-257.
- [34] Terra, ALM., Kosinski, RDC., Moreira, J. B., Costa, JAV., Morais, MGD. 2019. Microalgae biosynthesis of silver nanoparticles for application in the control of agricultural pathogens. *J Environ Sci Health, Part B*, 54 (8): 709-716.
- [35] Yadav, A., Kon, K., Kratosova, G., Duran, N., Ingle, A. P., Rai, M. 2015. Fungi as an efficient mycosystem for the synthesis of metal nanoparticles: progress and key aspects of research. *Biotechnol Lett*, 37 (11): 2099-2120.
- [36] Singh, P., Kim, Y. J., Zhang, D., Yang, D. C. 2016. Biological synthesis of nanoparticles from plants and microorganisms. *Trends in Biotechnol*, 34 (7): 588- 599.
- [37] Ismail, A. F. M., Ahmed, M. M., Salem, A. A. M. 2015. Biosynthesis of silver nanoparticles using mushroom extracts: induction of apoptosis in HepG2 and MCF-7 cells via caspases stimulation and regulation of BAX and Bcl-2 gene expressions. *J Pharm Biomed Sci*, 5 (1): 1-9.
- [38] Sukanya, M. K., Saju, K. A., Praseetha, P. K., Sakthivel, G. 2013. Therapeutic potential of biologically reduced silver nanoparticles from Actinomycete cultures. *J Nanosci*, 2013: 1-8.
- [39] Noruzi M, Zare D, Khoshnevisan K, Davoodi D. 2011. Rapid green synthesis of gold nanoparticles using *Rosa hybrida* petal extract at room temperature. *Spectrochim Acta Part A*, 79 (5): 1461-1465.
- [40] Hussain, I., Singh, N. B., Singh, A., Singh, H., Singh, S. C. 2016. Green synthesis of nanoparticles and its potential application. *Biotechnol Lett*, 38 (4): 545-560.
- [41] Mohanpuria, P., Rana, N., Yadav, S. 2008. Biosynthesis of nanoparticles: technological concepts and future applications. *J Nanopart Res*, 10 (3): 507-517.
- [42] Roy, A., Bulut, O., Some, S., Mandal, A. K., Yilmaz, M. D. 2019. Green synthesis of silver nanoparticles: biomolecule-nanoparticle organizations targeting antimicrobial activity. *RSC Adv*, 9: 2673-2702.
- [43] Ghorbani, H. R., Safekordi, A. A., Attar, H., Rezayat, M. 2011. Biological and non-biological methods for silver nanoparticles synthesis. *Chem Biochem Eng Q*, 25 (3): 317-326.
- [44] Kathiresan, K., Manivannan, S., Nabeel, M.A., Dhivya, B. 2009. Studies on silver nanoparticles synthesised by a marine fungus, *Penicillium fellutanum* isolated from coastal mangrove sediment. *Colloids Surf B Biointerfaces*, 71 (1): 133-137.

- [45] Rajeshkumar, S., Malarkodi, C., Paulkumar, K., Vanaja, M., Gnanajobitha, G., Annadurai, G. 2013. Intracellular and extracellular biosynthesis of silver nanoparticles by using marine bacteria *Vibrio alginolyticus*. *Nanosci Nanotechnol Int J*, 3: 21-25.
- [46] Rajendran, K., Sen, S. 2016. Optimization of process parameters for the rapid biosynthesis of hematite nanoparticles. *J Photochem Photobiol B Biol*, 159: 82-87.
- [47] Pereira, L., Mehboob, F., Stams, A. J., Mota, M. M., Rijnaarts, H. H., Alves, M. M. 2015. Metallic nanoparticles: microbial synthesis and unique properties for biotechnological applications, bioavailability and biotransformation. *Crit Rev Biotechnol*, 35 (1): 114-128.
- [48] Rai, M., Ingle, A. P., Birla, S., Yadav, A. Santos, C. A. 2015. Strategic role of selected noble metal nanoparticles in medicine. *Crit Rev Microbiol*, 42 (5): 696-719.
- [49] Zahir, A. A., Chauhan, I. S., Bagavan, A., Kamaraj, C., Elango, G., Shankar, J., Arjaria, N., Roopan, S. M., Rahuman, A. A., Singh, N. 2015. Green synthesis of silver and titanium dioxide nanoparticles using *Euphorbia prostrata* extract shows shift from apoptosis to G0/G1 arrest followed by necrotic cell death in *Leishmania donovani*. *Antimicrob Agents Chemother*, 59 (8): 4782-4799.
- [50] Hanafy, N. A., Leporatti, S., El-Kemary, M. A. 2019. Mucoadhesive hydrogel nanoparticles as smart biomedical drug delivery system. *Appl Sci*, 9 (5): 825.





## ***CHAPTER 4***

### **TYPES OF HYPERPIGMENTATIONS AND TREATMENT OPTIONS**

*Tunahan Mustafa CEYLAN<sup>1</sup>, Abdulsamet TANIK<sup>2</sup>*

---

1 DDS, Research Assistant ,Adıyaman University Faculty of Dentistry Department of Periodontology , Adıyaman, Türkiye Orcid: 0000-0003-0861-9185  
2 DDS , Assoc. Professor, Assistant ,Adıyaman University Faculty of Dentistry Department of Periodontology , Adıyaman, Türkiye , Orcid: 0000-0002-4430-2196

## What is the hyperpigmentation?

Hyperpigmentation is caused by an increase in the amount of melanin, hemosiderin and hemoglobin and its derivatives and lipochromes in soft tissues. Melanin is the pigment that is produced by melanocytes that differentiate embryonically from neural crest cells and gives the skin its color. These cells are located in the basal layer at the dermal-epidermal junction (Duval et al., 2014). As a result of this situation, spots or surfaces on the skin surface appear darker than their neighboring tissues. Hyperpigmentation is very common in society, it can be seen in all skin types. Types of hyperpigmentation such as melasma and sunspots; It can be seen in areas with higher exposure to sunlight. Examples of these areas are the face, arms, and legs. (Katsambas & Antoniou, 1995; Victor et al., 2004). Other types of pigmentation can be caused by injury or skin inflammation. Examples of these are cuts, burns, acne or lupus. These can happen anywhere on the body (Pérez-Bernal et al., 2000). Hyperpigmentation may also occur if some exogenous materials are accidentally invaded into the tissue (*Greenberg: Burket's Oral Medicine: Diagnosis and Treatment - Google Akademik*, n.d.; *Oral Melanin Pigmentation in Smoked and Smokeless Tobacco Users in India. Clinico-Pathological Study - PubMed*, n.d.; Hatch, 2005).

Limited hyperpigmented areas on certain areas of the skin are usually harmless; however, it may be a sign of a different medical condition.

**Most Common Types of Hyperpigmentation:**(*Hyperpigmentation: Types, Treatment, and Causes*, n.d.)

Type	Symptoms	Region	Reasons
Age spots	Black, brown, tan spots caused by overexposure to the sun	Commonly sun-exposed areas (face, arms and legs)	It usually occurs in older adults who are exposed to the sun.
Melasma	Large dark skin surfaces	Large dark skin surfaces	It occurs in women with dark skin who are pregnant or taking birth control pills.
Post-inflammatory hyperpigmentation	Spots or patches of dark skin are often seen after inflammatory events such as acne and eczema.	Face and neck areas	Occurs in people who have had a skin infection or injury

## **Causes of Hyperpigmentation:**

The causes of hyperpigmentation vary according to the type (pharmacological, thermal, chemical, surgical, idiopathic, physiological, etc.). Color changes can also be seen with the course of some diseases, systemic conditions or the penetration of colored foreign bodies in the oral mucosa. The most common types are:

### **A) Types of Extraoral Hyperpigmentation:**

#### **1) Sun Exposure**

As the body's exposure to the sun increases, the synthesis of melanin increases in order to protect the skin. As a result of this, dark spots or patchy areas called age spots or sunspots appear on the skin. Hyperpigmentation due to sun exposure is clinically very similar to post-inflammatory hyperpigmentation of the skin. The skin is affected by the ultraviolet (UV) rays of the sun (and & 1998, n.d.; Nordlund et al., 2007).

#### **2) Skin Inflammation**

After skin infections, dark areas may appear on the skin.. Conditions such as acne, eczema, skin injuries or lupus are examples of these infections. Individuals with dark skin are more prone to this type of hyperpigmentation. (Halder & Nordlund, 2007; Hexsel et al., 2006; Pandya et al., n.d.; Stratigos & Katsambas, 2004).

Inflammation can cause hyperpigmentation as a result of different mechanisms. However, inflammatory cytokines such as IL-1 $\alpha$ , endothelin 1 (ET-1) can directly stimulate melanocytes and cause hyperpigmentation. (Freyschmidt-Paul et al., 2006; Sriwiriyanont et al., n.d.). When these hyperpigmented areas were examined microscopically, it was determined that melanocytes produced increased melanin and melanin-loaded macrophages were outnumbered (Hatch, 2005).

#### **3) Melasma**

They are dark patch-shaped areas on the skin. This condition, which is caused by hormonal changes, is common during pregnancy. It is usually seen on the face and in a wide area. It is 10 times more common in women than men.

Other hyperpigmentations affect men and women equally. Melasma is more common in dark-skinned individuals and is inherited within families. There is limited information on the clinical manifestation of melasma: however, hormonal changes are thought to trigger melasma (*Melasma: Causes, Symptoms, Pictures & Treatment*, n.d.).

#### **4) Conditions Related to Drug Use**

Oral contraceptives, hormones, chemotherapeutic agents such as cyclophosphamide, bisulfan, bleomycin, fluorouracil, anti-malarial drugs, anti-viral agents such as zidovudine, anti-fungal drugs such as ketconazole may cause discoloration. There may be a colored area on the palate and gingiva. Colored area may turn gray. In the pathogenesis of drug-induced discoloration, accumulation of drug or drug metabolite in the dermis or epidermis layer is observed. Topical chemical applications can also cause discoloration.

#### **5) Medical Conditions**

Addison's disease is one of the most serious medical causes of hyperpigmentation. In this disease in which the adrenal glands are affected, hyperpigmentation can be seen in different areas of the skin. These areas are; folds of skin, lips, elbows and knees, knuckles, feet, and intraoral mucosa on the inside of the cheek.

#### **6) Hemochromatosis**

It is an inherited condition first described by Von Recklinghausen in 1889. In this disease, the amount of iron stored in the body is high. As a result, the skin may appear darker or tanner. There are 4 different types of hemochromatosis. Treatment is by phlebotomy, removal of iron or chelation.

#### **7) Thyrotoxicosis**

Thyroid hormone affects the normal pigmentation of the skin. Vitiligo and hyperpigmentation have been associated with thyrotoxicosis. Vitiligo-like depigmentation seen in thyrotoxicosis may precede thyroid symptoms. Hyperpigmentation cases are seen in 7% of individuals with thyrotoxicosis. Coloration is diffusely brown. These discolorations on the face, neck and palmar folds; They are not seen in the mucosa and genital area. However, there are two different views on this issue. The first of these is thought to be of thyroid hormone and autoimmune origin. According to another view; hyperpigmentation can result from hyperactivity in the sympathetic nervous system (Amos et al., 2004a; Wayli et al., n.d.).

#### **8) Polyostotic Fibrous Dysplasia**

In fibrous dysplasia, which is a tumor-like lesion; The interior of the bone consists of irregular bone trabeculae mixed with a dysplastic fibrous tissue. The cause of this condition is a mutation in the GNAS-1 gene. Fibrous dysplasia is divided into monostotic and polyostotic.

Polyostotic type can be McCune Albright or Jaffe-Lichtenstein type. In these cases, Café au lait spots are seen on the skin. Endocrinopathies



such as sexual precocious development, pituitary adenomas or hyperthyroidism may be seen in McCune Albright (Neville et al., 2015).

### **9) Neurofibromatosis**

Neurofibromatosis (NF) is a highly penetrating autosomal dominant disorder. There are two different types, NF-1 and NF-2. Cafe au lait spots on the skin are more common in NF-1. Colored areas in the form of pale brown patches larger than 5 cm can be seen. It is also known as Von Recklinghausen's disease of the skin (Neville et al., 2015).

### **10) Peutz-Jeghers Syndrome**

It is a rare genetic syndrome characterized by gastrointestinal polyps and mucocutaneous pigmentations. In patients with syndrome; mucocutaneous macules, intestinal polyps, increased risk of pancreatic, thyroid and breast cancer. Macular melanin deposits; It can be seen on the lip, buccal mucosa and fingers. In addition, these pigmented lesions can be seen on the tongue, palate and gingiva. When the oral lesions were examined histologically, an increased amount of melanin was detected in the basal layer independent of the amount of melanocytes (Amos et al., 2004b; Clinics & 2005, n.d.). Hyperpigmented areas fade or disappear after 70 years of age.

### **11) Lamb and Leopard Syndrome**

Lamb syndrome; It is a symptom characterized by atrial and mucocutaneous myxomas and blue moles, together with freckles on the skin and mucous membranes. In Leopard syndrome, with freckles; ocular hypertelorism, pulmonary stenosis, electrocardiogram (ECG) abnormalities, sexual abnormalities, deafness and growth retardation (Bauer et al., n.d.).

### **12) Post Inflammatory Hyperpigmentation**

The accumulation of hemosiderin in the tissues is responsible for the secondary discoloration due to hematoma. These colorations can vary from red to blue-violet. Color depends on how long the lesion lasts and the rate of destruction of extravasated blood. These discolorations are often confused with hematogenous discolorations. These trauma-induced discolorations in the soft tissue can be seen in the buccal mucosa, lateral surface of the tongue, lips, and the hard-soft palate transition line, which are generally prone to trauma.

### **13) Labial Melanotic Macule**

They are flat, oval-shaped, well-circumscribed black-brown pigmented lesions. Its dimensions are 1-8 mm. varies between. These lesions commonly appear on the lower lip and are mostly seen in women (Barrett & Scully, 1994). Exposure to UV light has an important place in the etiology of this lesion.

## **B) Intraoral Hyperpigmentation**

In humans, healthy gingiva is tightly attached to the tooth, coral pink in color. Unhealthy gingiva is seen as edematous, red and painful. It is possible to stretch the unhealthy gingiva with hand manipulation. Because it is not firmly attached to the tooth like a healthy gingiva.

The color of healthy gingiva is one of the most diverse conditions in the mouth. Color changes in the gingiva due to various physiological or pathological reasons occur due to various local or systemic reasons. In gingival pigmentation, melanin deposition is often observed in the basal and suprabasal layers. (Gaeta et al., 2002).

Depending on its depth in the epithelium, melanin gives a brown color to the mucosa and reflects from the mucosa as blue, green or black(Gaeta et al., 2002).

Physiological melanin pigmentations in the oral cavity have been evaluated in some populations. Melanin pigmentation is a benign change known in some races as ‘racial pigmentation’ or ‘physiological pigmentation’. Although there is no clinical pigmentation in the gingiva, melanocytes are present in all regions. Physiological pigmentation of the gingiva has been characterized with new immunohistochemical markers. Coloration due to increased melanoblastic activity and melanin production is independent of melanocyte number.

Coloration due to increased melanoblastic activity and melanin production is independent of melanocyte number. In this type of pigmentation, the main complaint of the patient is aesthetic. According to the case report of Başkent University Faculty of Dentistry, patients returned to their pre-treatment clinical appearance in the long term after treatment. In this long-term study, melanin pigmentation is the main cause of pigmentation rather than systemic and local causes (DiŞ Hk Fak Dü et al., n.d.).

Different diseases can cause different coloration of the mucosa. The causes of pigmentations in the oral cavity are as follows;

- Increase in melanin production
- Increase in the number of melanocytes (melanocytosis)
- Accumulation of exogenous materials

Oral pigmentations can be pathological or physiological. Pathological pigmentations; It can be divided into exogenous or endogenous origin. Exogenous pigmentations can be caused by drug use, tobacco use, amalgam tattooing or heavy metals. Endogenous discoloration may be caused by

endocrine disorders, syndromes, chronic irritation, infection, neoplastic or reactive origin.

**(Table 1 endogenous Table 2 exogenous pigmentations)** (Sreeja et al., 2015)

<b>Pigment</b>	<b>Color</b>	<b>Disease Process</b>
Hemoglobin	Blue,red,purple	Varix, hemangioma,kaposi's sarcoma, angiosarcoma, hereditary hemorrhagic telangiectasia
Hemosiderin	Brown	Ecchymosis, petechia, thrombosedvarix, hemorrhagic mucocele, hemochromatosis
Melanin	Brown,black org ray	Melanotic macule, nevus, melanoma, basilar melanosis with incontinence

*Table 1*

<b>Source</b>	<b>Color</b>	<b>Disease Process</b>
Silver amalgam	Gray,black	Tattoo, iatrogenic trauma
Graphite	Gray, black	Tattoo, iatrogenic trauma
Lead, mercury, bismuth	Gray	Ingestion of paint or medicinals
Chromogenic bacteria	Brown, green, black	Superficial colonization

*Table 2*

### 1) Melanin

The most important of the four pigments found in humans is melanin. Melanin is an endogenous non-blood-derived pigment. Melanin produced by melanocytes in the basal layer of the epithelium is transferred to neighboring keratinocytes through the organelle attached to the membrane called the 'melanosome'. Nevus cells with remnants of the neural crest in the oral mucosa or skin can also synthesize melanin. Depending on the amount of accumulation and in which tissue; pigmentation induced by melanin can be colored black, gray, blue or brown (Eisen, 2000). Changes in oral pigmentation are related to the amount of melanin produced, the localization and depth of the pigment. Physiological pigmentation of the gingiva is observed in almost every person of the white and black race, except for albinism. Although gender and race are not the determining factors in the amount of melanocytes, melanosomes in dark-skinned individuals have large and high cellular activity. Oral melanin pigmentations originating from melanin; It can be seen in 100% of healthy African dark-colored individuals, while it can be seen in 30% to 98% of healthy Asian individuals (Nagarajappa et al., n.d.). Increase in melanin pigmentation may herald a mucosal lesion or systemic disease. The different types of melanin are:

-Eumelanin: Together with another pigment, pheomelanin, it determines hair color.

-Feomelanin: Ömelaninle birlikte saç rengindedir.

-Miks melanin: Feomelanin ve ömelanin karışımıdır.

-Neuromelanin: Determines the color of neurons.

-Oxymelanin: colorless melanin that has been oxygenated. (hair whitening)

## 2) Medicines

Pigmentations can be caused by different types of drugs. These; hormones, oral contraceptives, cyclophosphamide, busulfan, bleomycin, fluorouracil such as chemotherapeutic agents; sedatives can also be caused by anti-malarial drugs. In addition, drugs such as minocycline, zidovudine and ketoconazole can also cause discoloration.

In addition, drugs such as minocycline, zidovudine and ketoconazole can also cause discoloration.. In addition to mucosal changes, bluish-gray discoloration may be seen in the teeth of adult or young patients due to minocycline/tetracycline discoloration. Colorations, which are the source of drugs in its pathogenesis; It can be divided into two as directly drug-induced or drug metabolite-derived. In pigmentations originating from drug metabolites, metabolite accumulation is observed in the dermis or epidermis. In this case, it is seen with an increase in melanin, with or without melanocyte accumulation. Apart from this, discoloration can also be seen as a result of drug-induced post-inflammatory changes. An example of this is discoloration as a result of metabolite-induced oral lichenoid lesion. This reaction can also be seen with bacterial attachments.(Eisen, 2000)

## 3) Smoking

One of the common abnormalities in smokers is melanin pigmentation. It is accepted that pigmented lesions may be caused by chemicals such as nicotine in cigarettes rather than the temperature factor. Cigarette addictions can be seen in different types. The vast majority of these different types of usage can be found in India. This habit can be classified as smoky tobacco or smokeless tobacco. One out of every five women who use tobacco takes birth control pills, while men take hormone supplements. Gingival pigmentation in children is caused by second-hand smoke(Reichart & Philipsen, 1998). Saraswathi et al. (*Oral Melanin Pigmentation in Smoked and Smokeless Tobacco Users in India. Clinico-Pathological Study - PubMed*, n.d.)According to the results of his clinical pathological study; More extensive pigmentation is seen in the labial mucosa than in the buccal mucosa. Also, according to this study; Although the pigmentation

is not very intense in smokeless tobacco users, it is due to the increase in the number and activity of melanocytes. Melanin lesions associated with tobacco use are related to pigmentation intensity, duration of use, and dose.

#### **4) Human Immunodeficiency Virus (HIV)**

The immune system is suppressed in HIV. As a result, inflammatory mediators such as IL-1, IL-6 and tumor necrosis factor alpha (TNF- $\alpha$ ) increase. Apart from these, alpha melanocyte stimulating hormone MSH (MSH- $\alpha$ ) is released from the anterior pituitary. MSH resists fever due to IL1,6 and TNF alpha. Alpha MSH is a potent melanocyte stimulator and IL-1 regulates MSH. As a result, the body's natural mechanism; releases MSH- $\alpha$  (SANFORD & FAVOUR, 1956) to control fever and inflammation . As a result of this situation, pigmented lesions occur in HIV-positive individuals(Regezi et al., 2016a).

HIV-positive individuals can be infected with mycobacterium avium. This bacteria can settle in the adrenal cortex and cause destruction. As a result of adrenal gland failure, the amount of adrenocorticotrophic hormone (ACTH) increases; this increases the amount of MSH. In this case, patients may experience hyperpigmentation. In addition, drugs such as ketoconazole and zidovidine given to treat the patient may also cause oral pigmentation; but these drugs need to be used for a long time (Regezi et al., 2016a; Smith et al., 1994). In HIV-positive individuals, the buccal mucosa is the most frequently affected area after the gingiva, palate and tongue.

#### **5) Tuberculosis**

Tuberculosis infection can cause destruction of the adrenal gland. As a result, 20% of individuals have Addison's disease. Oral pigmentation as a result of tuberculosis is similar to Addison's Disease (SANFORD & FAVOUR, 1956). Nowadays, as tuberculosis treatment has been developed, adrenal gland insufficiency due to tuberculosis has decreased.

#### **6) Candidiasis**

The first association between candida and hypoparathyroidism was described in 1929. Both of these conditions were associated with idiopathic adrenal gland insufficiency in 1946. The clinical picture is again the same as in Addison's disease.

#### **7) Heavy metals**

Arsenic, mercury, lead and silver salts enter the systemic circulation and cause discoloration in the oral mucosa as a result of increased levels of heavy metals in the blood. Mucosal staining of metals or their salts is often observed along the gingival margin. It is in the form of a bluish, gray-black stripe. Different metals cause different types of discoloration in

the oral mucosa. For example; As a result of lead poisoning, a blue-black line occurs along the marginal gingiva. These are called ‘Burton lines’. The common cause of heavy metal poisoning in adults is usually occupational. One of the most common causes of heavy metal discoloration in the past was heavy metals, such as arsenic, used to treat syphilis (Neville et al., 2015; Regezi et al., 2016b). Lesions due to metal deposition in the oral mucosa have no clinical significance other than aesthetics; however, it is important to evaluate metal toxicity in terms of systemic effects.

### **8) Amalgam tattoo**

Mercury in the composition of amalgam fillings causes soft tissue pigmentations. The galvanic current created by saliva, which is a good electrolyte, between the amalgam fillings used in dentistry and the oral mucosa, causes the release of mercury. Amalgam tattooing occurs as a result of the accumulation of released mercury, especially in the oral tissues adjacent to the amalgam-filled tooth. Amalgam tattooing is the most common cause of intraoral pigmentation and is 2 times more common than melanotic macules and 10 times more common than oral nevi (Regezi et al., 2016b) .

The most common location of the blue-gray lesions is the gingiva and alveolar mucosa. Pigmented lesions have no signs of inflammation; however, histopathologically, pieces of material embedded in the connective tissue are detected. A biopsy should be performed when this condition is suspected. In the biopsy, amalgam particles are detected in the connective tissue.

#### **Reasons;**

- 1) Amalgam powder can be infiltrated through oral fluids from mucosal abrasion.
- 2) Broken pieces of amalgam may fall into the extraction socket.
- 3) It may be contaminated with amalgam particles of dental floss and cause streak-like discoloration at the interface.
- 4) Amalgam particles may remain in the flap during endodontic retrograde filling.
- 5) With the high pressure of the aerator, amalgam particles may invade into the soft tissue (Buchner et al., n.d.; Neville et al., 2015).

### **9) Grafit:**

Pigmentation can be seen in the related area due to the fact that primary school children accidentally dip the tip of the pencil into the oral mucosa. In this condition, which is usually seen in children, irregular

gray-black lesions are seen on the palatal of the anterior region. Malignant lesions such as melanoma should also be differentiated because they appear similar in the same region (Regezi et al., 2016b).

### **10) Addison disease:**

Autoimmune destruction of the adrenal glands is called autoimmune adrenalitis. This condition is the most common cause of Addison's disease in children and adults. discoloration of the skin and mucous membranes; It is the most specific manifestation of Addison's disease and is seen in 92% of patients. In advanced Addison's disease, the skin takes on a bronze color. This pigmentation disorder can be seen 10 years before other symptoms of Addison's disease (Neville et al., 2015; Regezi et al., 2016b).

Pigmentation of the oral mucosa is considered pathognomonic for Addison's disease. Hyperpigmented lesions due to Addison's defect may appear as a splash of bright purple ink on the gingiva, buccal mucosa, hard palate, and tongue. The color of these lesions may be blue-black or brown. However, the type of coloration can be mottled or striped. Oral mucosa pigmentations may not go away after treatment of the disease.

### **11) Pregnancy**

Due to the increase in estrogen hormone during pregnancy, some changes occur in the skin and body. These changes often become more sensitive to MSH and tyrosinase enzymes in the tissues around the mouth and nipples in the third trimester of pregnancy, and hyperpigmentation may develop. Pigmentations can be seen on the face, cheeks and upper lip, which are seen after pregnancy. This is called melasma. Sunlight can also affect the formation of pigmented lesions.

### **12) Laugier-Hunziker Syndrome**

With longitudinal pigmentation involvement on the nails; It is an acquired pigmentation disorder characterized by macular hyperpigmentation, which is also common in the oral mucosa and lips. Its cause is not known exactly. Some studies have revealed that the number and size of melanosomes in the basal layer are increased in these individuals (Reichart & Philipsen, 1998). According to some studies, it is thought that hyperpigmented areas are seen due to the increase in the amount of melanosomes in the basal layer due to the increase in melanocyte activity (Sciences & 2011, n.d.).

### **13) Pigmented Cell Nevus**

Pigmented cell nevi; It occurs as a result of benign hamartomatous proliferation of nevus cells within the epithelium and connective tissue. It is simply divided into congenital and acquired. Congenital ones are divid-

ed into two as small and giant according to their size. The most common location of acquired nevus that develops is the hard palate. Its color also depends on the location of the nevus cells. The ones close to the surface are dark brown, while the ones that are deep have a light brown. The reason for the color in blue nevi can be shown as the proliferation of spindle-shaped cells in the deeper part of the connective tissue of melanocytes, further away from the epithelium. This is called the Tyndal effect (Neville et al., 2015; Regezi et al., 2016a) Although nevi are common on the skin, they are very rare in the mouth. In addition, nevi can be classified according to their location.

#### **14) Oral Melanotic Macule**

Oral melanotic macula is flat, oval, brown, and may be single or multiple. In its etiology, there is an increased accumulation of melanin with the number of melanocytes. As a result, focal hyperpigmented foci are seen. The most affected areas are the lips, buccal mucosa, gingiva and palate. Melanin deposition is usually close to the basal layer, and this situation is similarly observed in microscopic examinations. Differential diagnosis should be made with amalgam tattoo and blue nevus. These lesions usually do not require any treatment.

#### **15) Oral Melanoacanthoma**

It is a very rare benign tumor of the oral mucosa. It was first reported in 1978. It is more common in younger age groups and female patients. The most common site is the buccal mucosa. Its clinical appearance varies from brown to black. When the lesion is examined microscopically, melanocyte proliferation is seen along the acanthotic hyperkeratotic epithelium (Lakshminarayanan & Ranganathan, 2009).

#### **C) Treatment of Hyperpigmentation:**

One of the important issues in the treatment of hyperpigmentations is to take a good anamnesis to reveal the type of hyperpigmentation and the cause. Although many pigmentation disorders are not clinically significant, they can be treated with aesthetic concerns. In the treatment of pigmentation, the expectation and compliance of the patients should be evaluated.

In exogenous hyperpigmentations, improvement can be observed if the factor is removed. For example; In order to remove the causative factor in oral mucosal pigmentations due to smoking, smoking should be abandoned. Endogenous hyperpigmentations may be caused by hormonal, systemic diseases or syndromes. In such cases, it is useful to evaluate the patient together with a medical doctor. Pigmentation caused by hormonal and systemic disease, a regression can be seen in the pigmented areas with the treatment of the systemic condition.



Hyperpigmentations are generally harmless; however, individuals want to get rid of pigmented lesions due to cosmetic concerns. There are different options for hyperpigmentation treatment.

### **1) Treatment of Extraoral Hyperpigmentation**

Surgical interventions are rarely used in the treatment of extraoral hyperpigmentation. To prevent the formation of such pigmented areas or to prevent their further increase, the following can be done:

- **Sun protection**
- **Not to tear the crusts formed on the skin**
- **Regular use of recommended drugs in systemic diseases.**
- **Staying away from stressful environments or situations**

### **2) Treatment of Intraoral Hyperpigmentations**

Oral hyperpigmentations have many different causes. If the patient has hyperpigmentation due to drug use, the doctor should be consulted first and the drug should be changed if possible. It should be kept in mind that hyperpigmentation will recur after treatment if tobacco use continues in patients who use tobacco. In clinical situations such as amalgam tattoo and graphite discoloration, the coloration may improve after the agent is removed. In some cases, hyperpigmented areas can be treated with soft tissue surgical interventions. These treatment options are: There are many different causes of oral hyperpigmentations. If the patient has hyperpigmentation due to drug use, the doctor should be consulted first and the drug should be changed if possible. It should be kept in mind that hyperpigmentation will recur after treatment if tobacco use continues in patients who use tobacco. In clinical situations such as amalgam tattoo and graphite discoloration, the coloration may improve after the agent is removed. In some cases, hyperpigmented areas can be treated with soft tissue surgical interventions. These treatment options are:

- 1) Surgical intervention with a scalpel
- 2) Intervention with a diamond bur
- 3) Electrosurgery
- 4) Cryosurgery
- 5) Lasers
- 6) Radiosurgery
- 7) Masking gingival pigmentation by chemical methods
- 8) Free gingival graft

## 9) Acellular dermal matrix

### 1) Surgical intervention with scalpel

In this technique, the pigmented gingival epithelium is separated from the connective tissue on the forehead with a knife. The point to be noted is that any pigmented areas or spots are not left behind (*Scopus - Document Details - Null | Signed In*, n.d.)

Scalpel technique; It is the most economical technique and does not require any extra equipment in the clinic (Sanjeevini et al., 2012). The materials used in this technique are widely recommended as they are readily available in every clinic. In addition, faster wound healing is observed compared to other techniques (Javali et al., 2011a).

Depigmentation with a scalpel causes bleeding. Therefore, after the treatment, the surgical area should be protected with a periodontal dressing for 7-10 days. Although the initial results of this technique are quite positive, it is also possible to see recoloration. This can be explained by the migration of melanocytes (Sanjeevini et al., 2012).

### 2) Intervention with a diamond bur

In this technique, a diamond bur resembling a soccer ball with medium-sized particles is used at high speed. In this way, the epithelium is removed from the surface (AlQahtani, 2015).

This technique is simple to use, safe and non-aggressive. In addition, loss of aesthetics and comfort acceptable to the patient is seen (Gupta et al., 2014). Since advanced devices are not required in this technique, its application is economical.

The biggest difficulty of this method is to determine the depth of the area to be deepitized. Bleeding and post-operative pain are expected outcomes (Javali et al., 2011b).

### 3) Intervention with electrosurgery

Electro surgery; Healing in tissues is high-frequency electrical energy in the radio frequency band applied directly to the tissue to induce regeneration. The electric current passing through this tissue; produces heat that evaporates the fluid in the tissue and helps to cut the tissue. The reason for the emergence of this heat is due to the resistance of the tissue to the current. With this procedure, both coagulation and cutting effect in tissue are achieved (Prasad et al., n.d.).

This method; good bleeding control helps to achieve a good shaping of the tissues. In addition, the time in the patient's chair is shortened and the post-op comfort of the patient increases (Kaushik & Gaurav, 2013).

Electrosurgery should be performed more carefully than procedures with a scalpel. Prolonged application of electricity to the tissue causes undesirable results as a result of heat increase in the tissue. Avoid contact with alveolar bone, periosteum and vital teeth (Javali et al., 2011b).

#### **4) Cryosurgery**

Cryosurgery; It is the freezing of the gingiva with the help of liquid nitrogen or different materials. In this technique, tissue deterioration occurs as a result of rapid freezing and slow melting of the water in the cell. Cryotherapy has some direct effects such as cell dehydration, enzyme inhibition, protein denaturation and cell death due to thermal shock. In addition, it has indirect effects such as changes in vascular structure and cell death as a result of the immune response of the tissue (*Treatment of Gingival Physiologic Pigmentation in Adolescents by Liquid Nitrogen Cryosurgery: 24-Month Follow-up - PubMed, n.d.*).

In addition to its fast and easy application, this technique does not require anesthesia, does not require sutures, and does not result in bleeding or scarring as a result of the operation (Kumar et al., 2012).

Apart from these, swelling is a common consequence in cryosurgery. This condition is also accompanied by increased soft tissue destruction. There is no definite information about depth control and ideal application time in this method. Prolonged freezing increases tissue destruction (Javali et al., 2011c)

#### **5) Laser Intervention**

Laser ablation of hyperpigmented areas of the gingiva is an effective and safe technique. It is usually sufficient to remove the pigmented area and periodontal dressing is not required. Pain and discomfort are very minimal. Bleeding control during the study is very good and treatment results are very stable (Kaya et al., 2012). The disadvantages of this method include delayed wound healing, thermal damage, deep penetration, and high cost of the procedure.

Different types of lasers are used for gingival depigmentation. As an example of these; Carbon dioxide, diode, Nd Yag and Erbium YAG laser can be used.

Diode laser has recently found a place in dentistry. The energy absorbed by the pigmented area in the soft tissue also helps to provide good hemostasis. In this way, a good view is provided in the surgical field. Diode laser post-op is superior to scalpel in comfort (Raghavendra et al., 2016).

Carbon dioxide lasers are also quite harmless to the periosteum and alvolar bone below the gingiva. Thanks to the characteristic features of

these lasers, the epithelium can be peeled off as a thin layer (Prasad et al., n.d.). Nd and Erbium YAG lasers are the type of laser that cause the least thermal damage.

### **6) Radiosurgery**

The main advantage of this method is to provide a good coagulation in the operation area (*Radiosurgery for Gingival Melanin Depigmentation - PubMed*, n.d.). According to the results of some studies, better healing and less thermal damage are obtained in the treatment with 4MHz radio wave compared to laser and scalpel (*Radiosurgery for Gingival Melanin Depigmentation - PubMed*, n.d.).

The biggest disadvantage of this system is that the treatment requires at least two sessions and is completed within two weeks (Hirschfeld & Hirschfeld, 1951).

### **7) Masking gingival pigmentation with chemical methods**

Chemical agents containing 90% phenol or 95% alcohol show the property of burning and dissolving the gingiva. These mixtures are found to be very harmful to the gingiva and cause pain and necrosis. This type of chemical mixture dissolves the mucosa up to the basement membrane and removes the pigmented gingiva (Pontes et al., 2006).

### **8) Free Gingival Graft**

Free gingival graft is used in attached gingival augmentation and root surface closure procedures. In 2012 Kumar et al. treatment of common physiological melanin pigmentations with free gingival graft was introduced by Re-pigmentation was not detected in nine of ten patients in the 5-year follow-up of treatments performed with this method. Only one patient had recurrence within one year (AlQahtani, 2015).

As the disadvantages of this method; It is an invasive procedure, requires a second surgical site, and discoloration of the tissue after healing.

### **9) Acellular Dermal Matrix Allograft**

After local anesthesia is applied, two vertical incisions are made over the non-pigmented area, distal and mesial to the pigmented area. After that, a horizontal sulcular incision is made and the pigmented area is lifted in half thickness. The allograft adjusted in accordance with this area is placed in the area and fixed to the adjacent attached gingiva with sutures(Prasad et al., n.d.).

This method is more successful in eliminating gingival melanin pigmentation than epithelial abrasion (Pontes et al., 2006).

## REFERENCES

- AlQahtani, S. M. (2015). Management of gingival hyperpigmentation by the surgical abrasion: A case report. *Undefined*, 2, 1–3. <https://doi.org/10.15713/INS.IJMDCR.45>
- Amos, C. I., Keitheri-Cheteri, B., Sabripour, M., Wei, C., McGarrity, J., Seldin, M. F., Nations, L., Lynch, P. M., Fidler, H. H., & Friedman, E. (2004a). Genotype–phenotype correlations in Peutz-Jeghers syndrome. *Jmg.Bmj.Com*, 41, 327–333. <https://doi.org/10.1136/jmg.2003.010900>
- Amos, C. I., Keitheri-Cheteri, B., Sabripour, M., Wei, C., McGarrity, J., Seldin, M. F., Nations, L., Lynch, P. M., Fidler, H. H., & Friedman, E. (2004b). Genotype–phenotype correlations in Peutz-Jeghers syndrome. *Jmg.Bmj.Com*, 41, 327–333. <https://doi.org/10.1136/jmg.2003.010900>
- and, B. G.-T. pigmentary system physiology, & 1998, undefined. (n.d.). The photobiology of the tanning response. *Ci.Nii.Ac.Jp*. Retrieved August 5, 2022, from <https://ci.nii.ac.jp/naid/10027474037/>
- Barrett, A. W., & Scully, C. (1994). Human oral mucosal melanocytes: a review. *Journal of Oral Pathology & Medicine : Official Publication of the International Association of Oral Pathologists and the American Academy of Oral Pathology*, 23(3), 97–103. <https://doi.org/10.1111/J.1600-0714.1994.TB01095.X>
- Bauer, A., genetics, C. S.-J. of medical, & 2005, undefined. (n.d.). The lentiginoses: cutaneous markers of systemic disease and a window to new aspects of tumorigenesis. *Jmg.Bmj.Com*. <https://doi.org/10.1136/jmg.2003.017806>
- Buchner, A., Surgery, L. H.-O., Medicine, O., Pathology, O., & 1980, undefined. (n.d.). Amalgam pigmentation (amalgam tattoo) of the oral mucosa: a clinicopathologic study of 268 cases. *Elsevier*. Retrieved August 23, 2022, from <https://www.sciencedirect.com/science/article/pii/0030422080903060>
- Clinics, C. H.-D., & 2005, undefined. (n.d.). Pigmented lesions of the oral cavity. *Dental.Theclinics.Com*. Retrieved August 23, 2022, from [https://www.dental.theclinics.com/article/S0011-8532\(04\)00098-9/abstract](https://www.dental.theclinics.com/article/S0011-8532(04)00098-9/abstract)
- DiŞ Hk Fak Dü, A., Doç Hilal USLU TOYGARı Prıf, Y., & ARPAKt, N. (n.d.). *Long- Term Evaluation of Treatment for Gingival Pigmentation: 15 Years Follow Case Report*.
- Duval, C., Cohen, C., Chagnoleau, C., Flouret, V., Bourreau, E., & Bernerd, F. (2014). Key regulatory role of dermal fibroblasts in pigmentation as demonstrated using a reconstructed skin model: Impact of photo-aging. *PLoS ONE*, 9(12). <https://doi.org/10.1371/JOURNAL.PONE.0114182>
- Eisen, D. (2000). Disorders of pigmentation in the oral cavity. *Clinics in Dermatology*, 18(5), 579–587. [https://doi.org/10.1016/S0738-081X\(00\)00148-6](https://doi.org/10.1016/S0738-081X(00)00148-6)
- Freyschmidt-Paul, P., Hörster, S., Wenck, H., Stäb, F., Blatt, T., & Elsässer, H.-P. (2006). Alterations in the epidermal–dermal melanin axis and factor XII-

- Ia melanophages in senile lentigo and ageing skin. *Wiley Online Library*, 155(1), 119–128. <https://doi.org/10.1111/j.1365-2133.2006.07210.x>
- Gaeta, G. M., Satriano, R. A., & Baroni, A. (2002). Oral pigmented lesions. *Clinics in Dermatology*, 20(3), 286–288. [https://doi.org/10.1016/S0738-081X\(02\)00225-0](https://doi.org/10.1016/S0738-081X(02)00225-0)
- Greenberg: Burket's oral medicine: diagnosis and treatment - Google Akademik.* (n.d.). Retrieved August 22, 2022, from [https://scholar.google.com/scholar\\_lookup?title=Burkets+oral+medicine+diagnosis+and+treatment&author=M+Greenberg&author=M+Glick&publication\\_year=2003&](https://scholar.google.com/scholar_lookup?title=Burkets+oral+medicine+diagnosis+and+treatment&author=M+Greenberg&author=M+Glick&publication_year=2003&)
- Gupta, G., Kumar, A., Khatri, M., Puri, K., Jain, D., & Bansal, M. (2014). Comparison of two different depigmentation techniques for treatment of hyperpigmented gingiva. *Journal of Indian Society of Periodontology*, 18(6), 705. <https://doi.org/10.4103/0972-124X.147404>
- Halder, R. M., & Nordlund, J. J. (2007). Topical Treatment of Pigmentary Disorders. *The Pigmentary System: Physiology and Pathophysiology: Second Edition*, 1163–1174. <https://doi.org/10.1002/9780470987100.CH59>
- Hatch, C. L. (2005). Pigmented lesions of the oral cavity. *Dental Clinics of North America*, 49(1), 185–201, ix–x. <https://doi.org/10.1016/j.cden.2004.07.013>
- Hexsel, D., Arellano, I., & Rendon, M. (2006). Ethnic considerations in the treatment of Hispanic and Latin-American patients with hyperpigmentation. *British Journal of Dermatology*, 156(SUPPLE. 1), 7–12. <https://doi.org/10.1111/J.1365-2133.2006.07589.X>
- Hirschfeld, I., & Hirschfeld, L. (1951). Oral pigmentation and a method of removing it. *Oral Surgery, Oral Medicine, and Oral Pathology*, 4(8), 1012–1016. [https://doi.org/10.1016/0030-4220\(51\)90448-3](https://doi.org/10.1016/0030-4220(51)90448-3)
- Hyperpigmentation: Types, treatment, and causes.* (n.d.). Retrieved August 2, 2022, from <https://www.medicalnewstoday.com/articles/323808>
- Javali, M., Tapashetti, R. P., & Deshmukh, J. (2011a). Esthetic Management of Gingival Hyperpigmentation: Report of Two Cases. *Undefined*.
- Javali, M., Tapashetti, R. P., & Deshmukh, J. (2011b). Esthetic Management of Gingival Hyperpigmentation: Report of Two Cases. *Undefined*.
- Javali, M., Tapashetti, R. P., & Deshmukh, J. (2011c). Esthetic Management of Gingival Hyperpigmentation: Report of Two Cases. *Undefined*.
- Katsambas, A., & Antoniou, Ch. (1995). Melasma. Classification and treatment. *Journal of the European Academy of Dermatology and Venereology*, 4(3), 217–223. <https://doi.org/10.1111/J.1468-3083.1995.TB00341.X>
- Kaushik, M., & Gaurav, V. (2013). Efficacy of Different Techniques of Gingival Depigmentation: A Comparative Evaluation with a Case Report. *International Journal of Laser Dentistry*, 3(2), 68–72. <https://doi.org/10.5005/JP-JOURNALS-10022-1040>
- Kaya, G. Ş., Yavuz, G. Y., Sümbüllü, M. A., & Day, E. (2012). A comparison of

- diode laser and Er:YAG lasers in the treatment of gingival melanin pigmentation. *Oral Surgery, Oral Medicine, Oral Pathology and Oral Radiology*, 113(3), 293–299. <https://doi.org/10.1016/J.TRIPLEO.2011.03.005>
- Kumar, S., Bhat, G. S., & Bhat, K. M. (2012). Development in techniques for gingival depigmentation – An update. *Indian Journal of Dentistry*, 3(4), 213–221. [https://www.academia.edu/2333693/Development\\_in\\_techniques\\_for\\_gingival\\_depigmentation\\_an\\_update](https://www.academia.edu/2333693/Development_in_techniques_for_gingival_depigmentation_an_update)
- Lakshminarayanan, V., & Ranganathan, K. (2009). Oral melanoacanthoma: A case report and review of the literature. *Journal of Medical Case Reports*, 3. <https://doi.org/10.1186/1752-1947-3-11>
- Melasma: Causes, symptoms, pictures & treatment*. (n.d.). Retrieved August 19, 2022, from <https://www.medicalnewstoday.com/articles/323715>
- Nagarajappa, A., Sci, D. P.-I. J. M. A., & 2015, undefined. (n.d.). Adverse drug effects in mouth. *Researchgate.Net*. Retrieved August 22, 2022, from [https://www.researchgate.net/profile/Anil-Kumar-Nagarajappa/publication/306492638\\_ADVERSE\\_DRUG\\_EFFECTS\\_IN\\_MOUTH/links/57be914a08ae2f5eb32e0c0c/ADVERSE-DRUG-EFFECTS-IN-MOUTH.pdf](https://www.researchgate.net/profile/Anil-Kumar-Nagarajappa/publication/306492638_ADVERSE_DRUG_EFFECTS_IN_MOUTH/links/57be914a08ae2f5eb32e0c0c/ADVERSE-DRUG-EFFECTS-IN-MOUTH.pdf)
- Neville, B., Damm, D., Allen, C., & Chi, A. (2015). *Oral and maxillofacial pathology*. <https://books.google.com/books?hl=tr&lr=&id=Qs-JCgAAQBAJ&oi=fnd&pg=PP1&ots=mqW4yKrz-m&sig=JpIhApKt7J9bMQEUM-86D78rDz1A>
- Nordlund, J. J., Boissy, R. E., Hearing, V. J., King, R. A., Oetting, W. S., & Ortonne, J. P. (2007). The Pigmentary System: Physiology and Pathophysiology: Second Edition. *The Pigmentary System: Physiology and Pathophysiology: Second Edition*, 1–1229. <https://doi.org/10.1002/9780470987100>
- Oral melanin pigmentation in smoked and smokeless tobacco users in India. Clinico-pathological study - PubMed*. (n.d.). Retrieved August 22, 2022, from <https://pubmed.ncbi.nlm.nih.gov/14705454/>
- Pandya, A., clinics, I. G.-D., & 2000, undefined. (n.d.). Disorders of hyperpigmentation. *Elsevier*. Retrieved August 5, 2022, from <https://www.sciencedirect.com/science/article/pii/S0733863505701509>
- Pérez-Bernal, A., Muñoz-Pérez, M. A., & Camacho, F. (2000). Management of facial hyperpigmentation. *American Journal of Clinical Dermatology*, 1(5), 261–268. <https://doi.org/10.2165/00128071-200001050-00001/FIGURES/TAB1>
- Pontes, A. E. F., Pontes, C. C., Souza, S. L. S., Novaes, A. B., Grisi, M. F. M., & Taba, M. (2006). Evaluation of the efficacy of the acellular dermal matrix allograft with partial thickness flap in the elimination of gingival melanin pigmentation. A comparative clinical study with 12 months of follow-up. *Journal of Esthetic and Restorative Dentistry : Official Publication of the American Academy of Esthetic Dentistry ... [et Al.]*, 18(3), 135–143. <https://>

[doi.org/10.1111/J.1708-8240.2006.00004\\_1.X](https://doi.org/10.1111/J.1708-8240.2006.00004_1.X)

Prasad, S., Agrawal, N., & Reddy, N. R. (n.d.). *Gingival Depigmentation: A Case Report*.

*Radiosurgery for gingival melanin depigmentation - PubMed*. (n.d.). Retrieved October 17, 2022, from <https://pubmed.ncbi.nlm.nih.gov/19323336/>

Raghavendra, R. N., Ragul, M., Nabeeh, A.-Q., Ravi, K. S., Tikare, S., & Pasupuleti, M. K. (2016). Clinical Effectiveness of Gingival Depigmentation Using Conventional Surgical Scrapping and Diode Laser Technique: A Quasi Experimental Study. *Global Journal of Health Science*, 9(3), 296. <https://doi.org/10.5539/GJHS.V9N3P296>

Regezi, J., Sciubba, J., & Jordan, R. (2016a). *Oral pathology: clinical pathologic correlations*. <https://books.google.com/books?hl=tr&lr=&id=Lj3d-CwAAQBAJ&oi=fnd&pg=PP1&ots=Eua7mX3XZf&sig=mTLrYTTIJX-M7vU--un1Px15gPpw>

Regezi, J., Sciubba, J., & Jordan, R. (2016b). *Oral pathology: clinical pathologic correlations*. [https://books.google.com/books?hl=tr&lr=&id=Lj3d-CwAAQBAJ&oi=fnd&pg=PP1&ots=Eua7nS4O\\_9&sig=8panL3m3w-MTcfEDaVGLybp4dsR0](https://books.google.com/books?hl=tr&lr=&id=Lj3d-CwAAQBAJ&oi=fnd&pg=PP1&ots=Eua7nS4O_9&sig=8panL3m3w-MTcfEDaVGLybp4dsR0)

Reichart, P. A., & Philipsen, H. P. (1998). Betel chewer's mucosa--a review. *Journal of Oral Pathology & Medicine : Official Publication of the International Association of Oral Pathologists and the American Academy of Oral Pathology*, 27(6), 239–242. <https://doi.org/10.1111/J.1600-0714.1998.TB01949.X>

SANFORD, J. P., & FAVOUR, C. B. (1956). The interrelationships between Addison's disease and active tuberculosis: a review of 125 cases of Addison's disease. *Annals of Internal Medicine*, 45(1), 56–72. <https://doi.org/10.7326/0003-4819-45-1-56>

Sanjeevini, H., Pudukalkatti, P., SoumyaB, G., & Nayak, A. (2012). GINGIVAL DE-PIGMENTATION: 2 CASE REPORTS. *Undefined*.

Sciences, S. S.-I. J. of D., & 2011, undefined. (n.d.). Laugier-hunziker Syndrome: A Review. *Archieve.Ijds.In*. Retrieved August 24, 2022, from [http://archieve.ijds.in/issue-pdf-Vol\\_3\\_Issue:4\\_October\\_2011\\_Supplementary\\_Issue-12.pdf#page=43](http://archieve.ijds.in/issue-pdf-Vol_3_Issue:4_October_2011_Supplementary_Issue-12.pdf#page=43)

*Scopus - Document details - null | Signed in*. (n.d.). Retrieved October 13, 2022, from <https://www.scopus.com/record/display.uri?eid=2-s2.0-84865509999&origin=inward>

Smith, K. J., Skelton, H. G., Yeager, J., Ledsky, R., McCarthy, W., Baxter, D., & Wagner, K. F. (1994). Cutaneous findings in HIV-1-positive patients: a 42-month prospective study. Military Medical Consortium for the Advancement of Retroviral Research (MMCARR). *Journal of the American Academy of Dermatology*, 31(5 Pt 1), 746–754. [https://doi.org/10.1016/S0190-9622\(94\)70236-5](https://doi.org/10.1016/S0190-9622(94)70236-5)



- Sreeja, C., Ramakrishnan, K., Vijayalakshmi, D., Devi, M., Aesha, I., & Vijayabanu, B. (2015). Oral pigmentation: A review. *Journal of Pharmacy & Bioallied Sciences*, 7(Suppl 2), S403. <https://doi.org/10.4103/0975-7406.163471>
- Sriwiriyant, P., Ohuchi, A., ... A. H.-L., & 2006, undefined. (n.d.). Interaction between stem cell factor and endothelin-1: effects on melanogenesis in human skin xenografts. *Nature.Com*. Retrieved August 5, 2022, from <https://www.nature.com/articles/3700469>
- Stratigos, A. J., & Katsambas, A. D. (2004). Optimal management of recalcitrant disorders of hyperpigmentation in dark-skinned patients. *American Journal of Clinical Dermatology*, 5(3), 161–168. <https://doi.org/10.2165/00128071-200405030-00004>
- Treatment of gingival physiologic pigmentation in adolescents by liquid nitrogen cryosurgery: 24-month follow-up - PubMed*. (n.d.). Retrieved October 14, 2022, from <https://pubmed.ncbi.nlm.nih.gov/22577644/>
- Victor, F. C., Gelber, J., & Rao, B. (2004). Melasma: A review. *Journal of Cutaneous Medicine and Surgery*, 8(2), 97–102. <https://doi.org/10.1177/120347540400800204>
- Wayli, H. al, Rastogi, S., Surgery, N. V.-O., Medicine, O., Oral, undefined, & 2011, undefined. (n.d.). Hereditary hemochromatosis of tongue. *Elsevier*. Retrieved August 23, 2022, from <https://www.sciencedirect.com/science/article/pii/S1079210410006049>





## **CHAPTER 5**

### **DIABETES MELLITUS AND CYTOKINES**

*Dilek Nur BESTIL<sup>1</sup>,  
Burcu Menekşe BALKAN<sup>2</sup>,  
Tevhide SEL<sup>3</sup>*

---

1 Ankara University, Faculty of Veterinary Medicine, Dept. of Biochemistry, Ankara, Turkey 0000-0003-1565-1466

2 Mehmet Akif Ersoy University, Faculty of Veterinary Medicine, Dept. of Biochemistry, Burdur, Turkey 0000-0002-0206-6455

3 Ankara University, Faculty of Veterinary Medicine, Dept. of Biochemistry, Ankara, Turkey <https://orcid.org/0000-0002-9753-0779>

## INTRODUCTION

Diabetes is a heterogeneous group of diseases that cause glucose elevation in the blood. Chronic hyperglycemia and the risk of developing complications are the two unifying features that hold the concept of diabetes together. Diabetes mellitus (DM), characterized by the absence of insulin or increase in peripheral insulin insensitivity, is a multisystem disease with humoral and textural consequences, including disorders of carbohydrate, protein and lipid metabolism (Denyer et al., 2021). Type 1 Diabetes mellitus (T1DM) and Type 2 Diabetes mellitus (T2DM) are histologically different. Apart from this, it also differs genetically. T1DM is insulin dependent whereas T2DM is insulin independent (Denyer et al., 2021).

It has been revealed that cytokines are associated with many diseases and each cytokine has different roles in individual diseases. Many diseases in which abnormal or excessive secretion of cytokines contribute to the pathogenesis have been reported. For example, in chronic inflammatory and autoimmune disorders such as type I diabetes, overexpression of IL-1 and IL-6 has been reported. It is well known that TNF $\alpha$  may play direct role in the pathology of diverse systemic diseases and affects the localization of the disease (Boarescu et al., 2022).

Interest in cytokine antagonist therapy in clinical practice is growing and advancing field, with major drug impact in clinical practice, as in every important biological process comprise cytokines involvement. They are excellent targets for the pharmaceutical industry as monoclonal antibodies and biotechnology products such as antibody-like receptor, fusion proteins because they are potential limiting molecules in various diseases (Ateş, 2018; Moneima et al., 2018). Inflammation, immune cells and interleukins may involve in the pathogenesis of T2DM (Kammoun et al., 2018).

## DIABETES MELLITUS

DM is a chronic and multisystem metabolic disease occurs as a result of insulin deficiency or receptor resistance. DM characterized by hyperglycemia, in which the organism cannot adequately benefit from carbohydrates, fats and proteins, and is caused by genetic and environmental factors that require regular medical care (Dinççağ, 2011). Its incidence is increasing all over the World and in our country, and it negatively affects the quality of life due to the complications it causes (Eser et al., 2016). Diabetes is classified in four clinical types according to laboratory and clinical findings, and the prevalence of forms.

### Type-1 Diabetes Mellitus (T1DM)

T1DM is insulin dependent and may occur due to idiopathic or immune-mediated causes. The number and size of the islets of Langerhans in

the pancreas decreases, especially in severe cases, the islets are destroyed in a way that cannot be determined. In mild cases, degranulation is observed in  $\beta$ -cells and the damage in  $\beta$ -cells is progressive (Şimşek and İcen, 2008).

### **Type-2 Diabetes Mellitus (T2 DM)**

T2 DM is a form of diabetes that is not dependent on insulin. It is characterized by insulin resistance and abnormal insulin secretion. In the early stages of the disease, the glucose concentration is normal despite excessive insulin secretion. In the following period, insulin secretion is not adequate to regulate the glucose concentration and blood glucose level increases (hyperglycemia), and accordingly, it causes loss of function due to severe stimulus in  $\beta$ -cells and sufficient insulin cannot be secreted (Şimşek and İcen, 2008).

### **Gestational Diabetes Mellitus**

DM is defined as any glucose intolerance disorder that starts during pregnancy or is first diagnosed during pregnancy (ADA, 2012). Increased levels of estrogen and progesterone hormones in the blood during the first trimester of pregnancy stimulate hyperplasia of beta cells in the maternal pancreas. As a result of hyperplasia, insulin secretion increases and susceptibility to hypoglycemia develops. During this period, nausea and vomiting in pregnant women increase the susceptibility to hypoglycemia by reducing food intake. In the second trimester, insulin insensitivity develops as a result of increased secretion of HPL (Human Placental Lactogen) hormone especially between 20-30 weeks. Increased amino acids and glucose in the maternal blood passes to the fetus. Insulin balance is disturbed by the growing fetus. The maternal pancreas becomes unable to meet the insulin demand and GDM develops (Çoban 2015; Taşkın 2016).

### **Diabetes Due to Other Disorders (Secondary Diabetes)**

Hyperadrenocorticism and progesterone plays role in the mechanism of this type. Since these hormones have an antagonistic effect with insulin, they cause insulin resistance. The disease is asymptomatic when it first appears, but becomes chronic over time. It is characterized by polydipsia, polyuria, polyphagia, weight loss, cataracts, and weakness. Resistance to bacterial and fungal infections is reduced. Dehydration, depression, vomiting, tachypnea, and acetone odor in respiration are seen in diabetic ketoacidosis (Dinççağ, 2011; Şimşek and İcen, 2008).

Hyperglycemia, glycosuria, increased liver enzyme activities, hypercholesterolemia and hyperproteinemia are common laboratory findings. While blood glucose level is usually above 200 mg/dl, glucose level is 125-180 mg/dl in asymptomatic diabetes. While the serum insulin level is

<20  $\mu\text{U/ml}$  in Type 1 DM patients, the serum insulin level is >26  $\mu\text{U/ml}$  in Type 2 DM patients. The determination of glucose in the blood may not always be sufficient. In this case, an oral or intravenous glucose tolerance test is performed (Dinççağ, 2011).

## CYTOKINES

Cytokines are glycoproteins secreted by immune cells that affect the function of the cell that carries the appropriate receptor for it and provide intercellular communication. The diverse and often conflicting multiple biological activities of these small, nonstructural proteins are implicated in inflammation and immunology. Currently, the term of “cytokine” includes interferons, tumor necrosis factor family, chemokine family, interleukins, mesenchymal growth factors, and adipokines. Cytokines are involved in biological processes such as embryonic development, pathogenesis of disease. Antigen-specific and non-specific infection response, alterations in cognitive functions, and progression of degenerative processes of aging are main events that cytokines may get involved. In addition to these events, cytokines are also part of vaccine efficacy, stem cell differentiation, and allograft rejection (Diker, 2005).

For regulation and coordination of an effective immune response, a mechanism by which cooperation of lymphocytes, inflammatory cells, and hematopoietic cells is required. Cytokines perform this function. Although originally described for its immunomodulatory abilities, other properties apart from the immune system, such as cell differentiation and directed migration have also been reported in developmental processes (Diker, 2005).

Cytokines exert their main effects by high-affinity binding to its receptor expressed on the surface of a target cell. These receptors have three main domains namely; a cytoplasmic, an extracellular, and a single membrane spanning domain. The extracellular domain has conserved amino acid sequence motifs which contain four conserved cysteine residues. Cytokine-specific  $\alpha$  subunit and the signal transduction subunit are the two polypeptide chains of cytokines (Diker, 2005). In target cell, receptor interaction triggers intracellular signaling cascades that lead to altered gene expression and exert a variety of biological effects. It occurs in three ways, depending on the cell they affect and its distance. The first, effect of cytokine secreted from cells between different cell types on cells close to it or in physical contact is called paracrine effect. The second is the autocrine effect by binding the cytokines to the cell receptor from which they are produced, and the third is the endocrine effect when the secreted cytokine disperses throughout the body and affects the cells in distant tissues ((Diker, 2005).

Cytokines play a role in many cellular responses such as regulation of immunity, formation of immune response and regulation of inflammation. Regulation of natural immunity against viral and bacterial infections (IFN-beta, TNF, IL-1, IL-6, IL-8),

**b)** Regulate the lymphocyte activation, proliferation and change by helping formation of cellular and humoral immune response (IL-2, IL-4, TGF-beta),

**c)** Regulation of immune-based inflammatory reactions and cellular immunity (IFN-gamma, TNF-beta, IL-5, IL-10, IL-12)

**d)** Regeneration of cells outside the immune system with immune modulator cytokines on the nervous and endocrine system. (IL-1, IL-2, IL-4, IFN-gamma)

**e)** Stimulates leukocyte chemotaxis. It is produced in T cells and macrophages. It provides the formation and continuation of the inflammation (CXC (alpha) and CC (beta) chemokines (Diker, 2005).

### **The Relationship of Diabetes Mellitus and Cytokines**

An inflammatory mechanism has been proposed to explain the pathogenetic mechanism of DM (Rasier et al., 2011). In case of progression of diabetes, different disorders such as Diabetic Retinopathy may occur together. Diabetic retinopathy is a microvascular complication that is frequently encountered in patients with DM and causes sudden and severe loss of visual acuity (Goldberg, 2009). DM is a very complex and multifaceted inflammatory disease. Its most important feature is low-grade chronic inflammation accompanied by irregular inflammatory biomarkers (Goldberg, 2009). The formation of complications, development and effects of cytokines, which are important in DM, are explained. It is accepted that chronic low-grade inflammation and activation of the innate immune system play an important role in the pathogenesis of DM (Crook, 2004; Pickup, 2004; Pickup and Crook, 1998). In fact, it is reported that inflammation features are seen in individuals with DM years before they get the disease (Bloomgarden, 2003; Dandona et al., 2004) In addition, population-based studies show that inflammatory parameters, including inflammatory cytokines, are strong markers of diabetes development (Pradhan et al., 2001; Spranger et al., 2003). In the pathogenesis of DM, cytokines namely TNF- $\alpha$ , IL-1, and IL-6 play an important role (Alexandraki et al., 2006).

### **CXCR4**

CXCR4, which is in the group of alpha chemokines, is a G protein-linked specific receptor for chemokine in the hematopoietic and immune systems. Painful Diabetic Neuropathy (ADN) is the most common chronic complication of diabetes. CXCR4 plays an important role in the

development of ADN. In the study conducted to determine the effect of CXCR4 in rats, N-acetylcysteine (NAC), antioxidant, was used in Streptozotocin-induced experimental diabetic rats, and it was determined that CXCR4 increased in a significant number in the spinal cord and prefrontal cortex by Western blot. The use of NAC and the induction of CXCR4 have been shown to reduce the effect of ADN, but this mechanism has not been fully determined. Another complication in diabetic patients is foot deformity. According to the results of the research, SDF-1, the specific ligand of CXCR4, reduced foot deformity by protecting blood vessels with the increase of CXCR4 in the early stages of DM (Sisi et al., 2021).

### **Interleukin-1 (IL-1)**

IL-1 is a very potent cytokine that is stimulated by TNF or IL-1 that affects all immune system cells (especially Th2 cells, B cells) and is produced by macrophages that come into contact with CD4+T cells. It regulates local inflammatory reactions at low concentrations and when it reaches high concentrations, it enters the blood circulation and exerts an endocrine effect (Diker, 2005). Its systemic effects are the release of acute phase proteins from the liver, increase in body temperature and cachexia (Diker, 2005; Orlenko and Kravchuk 2020). It is also associated with joint damage in patients with DM (Orlenko and Kravchuk, 2020).

T2DM is characterized by insulin resistance and chronic sub-clinical inflammation. Interleukin 1 $\beta$  (IL1 $\beta$ ), a proinflammatory cytokine, is associated with  $\beta$ -cell damage and modulates insulin secretion and  $\beta$ -cell apoptosis. IL-1 $\beta$  which is a potent pro-inflammatory driving cytokine produced mainly by  $\beta$ -cell macrophages. IL-1 $\beta$  regulated by IL-1 receptor antagonist (IL-1Ra). In case of inflammation, macrophages produce IL-1 $\beta$ /IL-1Ra (Margaryan et al., 2020). Compared with other cells,  $\beta$  cells express greater amounts of interleukin 1 receptor (IL-1R) compared to other cells. Therefore, the balance in IL-1 $\beta$ /IL-1Ra levels is very important in monitoring the progression. IL-1 $\beta$  regulates the inflammatory response and metabolism. It can lead to T2DM by regulating insulin secretion and promoting  $\beta$ -cell apoptosis (Margaryan et al., 2020; Sepehri et al., 2017). Chronically high levels of IL-1 $\beta$  have been shown to cause  $\beta$ -cell dysfunction in obese and T2DM individuals (Tong et al., 2017).

Diabetic arthropathy is characterized by synovial inflammation that occurs with the emergence of degenerative-dystrophic changes in vessels, bone tissue, and joint structure, increased expression of proinflammatory mediators and accelerated catabolism of the articular cartilage matrix. IL-1 functions are effective on plasminogen. The catabolic effect of IL-1 manifests itself by stimulating chondrocytes and synoviocytes to secrete nitrogen oxide (NO), which damages the extracellular matrix. IL-1 $\beta$  de-



creases osteocalcin concentration and causes destruction of subchondral bone (Orlenko and Kravchuk 2020).

### **Interleukin-8 (IL-8)**

IL8 is a member of the C-X-C motif (CXC) subfamily of chemokines. It activates human neutrophils by interacting with two receptors CXCR1 and CXCR2 (Wuyts, et al., 1998) IL-8 is secreted by many cell types in response to inflammatory stimuli and is involved in the acute inflammatory reaction by initiation and amplification the process (Harada et al., 1994). Studies have reported that chemokines and neutrophils play a role in the pathogenesis of T1DM (Ahmadi et al, 2013, Harsunen et al, 2013; Ismail et al, 2016; Valle et al, 2013).

Its role in diabetes also promotes the infiltration of macrophages within adipose tissue, which induces local and systemic inflammation and, in turn, represents a potential link between adipose tissue dysfunction and conditions associated with insulin resistance. Insulin resistance and Type 2 Diabetes are associated with higher circulating levels of C-reactive protein (CRP), IL-6 and TNF- $\alpha$ ; more recently, the chemokine system has come into the focus of metabolic inflammation research, and IL-8 levels in particular have been associated. (Farhan et al., 2018; Goldberg, 2009;).

After examining the vitreous samples of patients with Diabetic Retinopathy, higher levels of IL-8 and TNF- $\alpha$  were found in patients with retinopathy compared to the others. It has been shown that some serum components that pass into the vitreous as a result of disruption of the blood-retina barrier also contribute to the formation of fibrovascular membranes (Rasier et al., 2011).

IL-18, a potent inflammatory cytokine (Okamura et al., 1995), induces IFN- $\gamma$  and functional chemokine receptor expression in human mesangial cells (Schwartz, 2002). Furthermore, IL-18 leads to the production of other inflammatory cytokines, including IL-1 and TNF- $\alpha$ , and induce apoptosis of endothelial cells. IL-18 is expressed in the renal tubular epithelium (Dai et al, 2004; Fantuzzi et al, 1999; Stuyt et al, 2003)

In patients with diabetic nephropathy, an increase in serum and urinary IL-18 levels have been reported. This increase was independent with urinary albumin excretion, (Moriwaki et al., 2003; Nakamura et al., 2005). Contrary to this findings Nakamura et al., (2005) found that serum and urine concentrations of IL-18 were directly related to the rate of albumin excretion (Nakamura et al., 2005). Urinary excretion of  $\beta$ -2 microglobulin is a marker of tubulointerstitial damage. A positive correlation between urinary excretion of  $\beta$ -2 microglobulin and serum IL-18 levels was reported (Wong et al., 2007).

### **Interleukin-10 (IL-10)**

It is an anti-inflammatory cytokine and its level has been observed to increase in patients with T2DM. Although IL-10 is known as an anti-inflammatory cytokine, the increase of IL-10 in T2DM samples and the interaction between molecules is quite complex. In cardiovascular cases, IL-10 concentration is positively correlated with pro-inflammatory mediators including CRP and IL-6. The physiological role of IL-10 limits the pro-inflammatory cytokine production of the inflammatory response and suppresses macrophage activity. Thus, it takes a regulatory role against inflammatory stimuli (Shehan et al., 2019).

### **Interleukin-17(IL-17)**

It is produced by T cells (Diker, 2005) and plays an important role in the pathogenesis of many autoimmune and inflammatory diseases including DM. IL-17 expression in the islets of Langerhans in non-obese type-1 diabetic mice is associated with insulinitis. With the development of diabetes, the level of IL-17 gets higher in the plasma. The anti-IL-17 antibody used in the experimental model showed a positive effect in T1DM and decreased IL-17 producing T cells and protected against the development of diabetes. IL-17 increases the level of pro-inflammatory cytokines and initiates inflammation. IL-17 also plays an important role in the initiation of inflammation in the adipose tissue of obese individuals. It is directly proportional to the increase in IL-17 level with the experimental obesity. Therefore, IL-17 is presented as a marker for inflammation accompanying obesity (Moneima et al., 2018).

In T2DM, IL-17 activates Nuclear factor-kappa B (NF- $\kappa$ B), which regulates inflammatory cytokine gene expression, and stimulates secretion of pro-inflammatory cytokine (IL-1, IL-6, TNF- $\alpha$ ) that causes the formation of insulin resistance. Due to the effect of TNF- $\alpha$  that inhibits insulin stimulation, insulin resistance occurs and T2DM development is observed (Moneima et al., 2018).

### **TNF- $\alpha$ and IL-6**

TNF has two forms, alpha and beta. TNF-alpha is secreted from active macrophages, TNF-beta is secreted from T cells. Its function is to stimulate and activate the development of the immune system cell. It ensures the death of susceptible tumor cells and virus-infected cells by apoptosis. Overstimulation by these cytokines may cause tissue destruction or shock (Diker, 2005). The imbalance of TNF- $\alpha$  and IL-6 cytokines plays an important role in the development of chronic inflammatory diseases (Goldberg, 2009).

IL-6 is secreted from Th2 cells (Ateş, 2018). The pathology of joint

diseases is associated with DM, especially with obesity. IL-6 affects the resorption of bone tissue in diabetic arthropathy and inhibits collagen synthesis by chondrocytes. TNF- $\alpha$  has receptors on chondrocytes. It activates the synthesis of pro-inflammatory cytokines (IL-1, IL-6, IL-8) in joint diseases. TNF- $\alpha$  stimulates fibroblast proliferation and inhibits collagen synthesis. The effect of TNF- $\alpha$  as an inflammatory cytokine depends on its concentration in the tissues. According to the findings determined by ELISA, TNF- $\alpha$  and IL-6 levels were found to be significantly higher in arthropathy (Orlenko and Kravchuk, 2020).

Genetic factors can increase fat accumulation similar to environmental factors, and this fat accumulation causes chronic or local inflammation, and abnormal proinflammatory production causes an increase in acute phase reactants such as CRP (Ateş, 2018).

The most important role of IL-6 in endothelial dysfunction seen in T1DM and T2DM is related to CRP production and clinical marker of inflammation. Adipose tissue is important in vascular and non-vascular tissues in the inflammatory process in obese subjects because it contains active macrophages together with adipocytes and produces adipokines such as IL-6 and TNF- $\alpha$  (Goldberg, 2009).

TNF- $\alpha$  partially causes decrease adiponectin level in obese individuals in T2DM, and it is suggested that this decrease may cause metabolic and vascular abnormalities. IL-6 is high in normoglycemic obese individuals. Insulin resistance has a great effect on these abnormalities. IL-6 and TNF- $\alpha$  values in T2DM subjects have been associated with insulin resistance independently of obesity and hyperglycemia. It is not clear whether IL-6 level is related with exercise, but TNF- $\alpha$  and IL-6 levels decreased with weight loss (Goldberg, 2009).

Thiazolidinediones, an anti-hyperglycemic agent used in the treatment of T2DM, decreased TNF- $\alpha$  and IL-6 levels within a few days of treatment (Goldberg, 2009). IL-6 and TNF- $\alpha$  are critical pathogenic cytokines involved in the cytokine storm in patients infected with SARS-CoV or MERS-CoV. Considering the pleiotropic effect of IL-6, anti-inflammatory cytokines (such as IL-10) at blood-glucose level when infected with coronavirus may be beneficial and it is predicted that the hospitalization time of DM patients will decrease. Low-grade chronic inflammation is defined as an important feature of T2DM. Pro-inflammatory cytokines (IL-6, TNF- $\alpha$ ) act as an aid to the development of insulin resistance. In COVID-19 patients with T2DM, IL-6 and TNF- $\alpha$  levels were found to be quite high in plasma. The reason for the increase in IL-6 level is due to viral hyperinflammation. It may be associated with mortality because of this (Zheng et al., 2021). Type 1 diabetes is a cardiovascular risk factor that

changes oxidative stress parameters, increases the level of proinflammatory cytokines in the aorta, and causes irreversible proatherogenic changes in the aortic wall (Boarescu, 2022).

TNF- $\alpha$  activates the transcription of NF- $\kappa$ B by regulating the expression of related genes. It plays a role in oxidative stress, inflammation, and endothelial dysfunction. In the experimental model, the value of TNF- $\alpha$  and IL-6 was significantly increased in the DM group. It has been observed that the increased production of these proinflammatory cytokines supports atherosclerosis (Boarescu, 2022).

When TNF- $\alpha$  and IL-1 levels were compared with macrophages in peritoneum cultured with glomerular basement membranes obtained from diabetic rats and non-diabetic rats, it was found that levels were higher in diabetic rats. Based on this result, Hasegawa et al. suggested that in the pathogenesis of diabetic nephropathy inflammatory cytokines may participate (Hasegawa et al., 1991). Inflammatory cytokines such as IL-1, IL-6, IL-18 and TNF- $\alpha$  have been reported to be related to the development of diabetic nephropathy and may potentially play a role in the development of complications.

As a result, DM is a chronic and multisystem metabolic disease caused by insulin deficiency or insulin receptor resistance. DM characterized by hyperglycemia, in which the organism cannot adequately benefit from carbohydrates, fats and proteins, and is caused by genetic and environmental factors that require regular medical care. T1DM and T2DM differ from each other histologically and genetically. T1DM is insulin dependent while T2 DM is insulin independent.

Cytokines are glycoproteins secreted by immune cells that affect the function of the cell that carries the appropriate receptor for it and provide intercellular communication. The diverse and often conflicting multiple biological activities of these small, nonstructural proteins are implicated in inflammation and immunology. It is known that cytokines are associated with many diseases. It has been revealed that each cytokine has different roles in individual diseases. Many diseases in which abnormal or excessive secretion of cytokines contribute to the pathogenesis have been reported. Diabetes Mellitus is also a complex and multifaceted inflammatory disease. Its most important feature is low-grade chronic inflammation accompanied by irregular inflammatory biomarkers.

## REFERENCES

- Ahmadi, Z., Arababadi, M. K., & Hassanshahi, G. (2013). CXCL10 activities, biological structure, and source along with its significant role played in pathophysiology of type I diabetes mellitus. *Inflammation*, 36(2), 364–371.
- Alexandraki, K., Piperi, C., Kalofoutis, C., Singh, J., Alaveras, A., & Kalofoutis, A. (2006). Inflammatory process in type 2 diabetes: The role of cytokines. *Annals of the New York Academy of Sciences*, 1084, 89–117.
- American Diabetes Association (ADA) (2002). Gestational diabetes mellitus. *Diabetes Care*, 25 (Supplement-1), 94-96. Eriřim tarihi: 25.12.2019, [https://care.diabetesjournals.org/content/25/suppl\\_1/s94](https://care.diabetesjournals.org/content/25/suppl_1/s94)
- Ateř İ. (2018). Type 2 Diabetes Mechanisms, Role of Cytokines and Their Variations in Disease Development. *FABAD J. Pharm. Sci.*, 43(1), 31-40.
- Bloomgarden Z. T. (2003). Inflammation and insulin resistance. *Diabetes care*, 26(5), 1619–1623.
- Boarescu, P. M., Boarescu, I., Pop, R. M., Rořian, ř. H., Bocřan, I. C., Rus, V., Mada, R. O., Popa, I. D., Neagu, N., Bulboacă, A. E., Buzoianu, A. D., & Bolboacă, S. D. (2022). Evaluation of Oxidative Stress Biomarkers, Pro-Inflammatory Cytokines, and Histological Changes in Experimental Hypertension, Dyslipidemia, and Type 1 Diabetes Mellitus. *International journal of molecular sciences*, 23(3), 1438
- Çoban A. (2015). Riskli Gebelikler, řirin A & Kavlak O, Kadın Saęlıęı, Geniřletilmiş 2. Baskı, Ankara, Nobel Tıp Kitabevleri, s.324.
- Crook M. (2004). Type 2 diabetes mellitus: a disease of the innate immune system? An update. *Diabetic medicine : a journal of the British Diabetic Association*, 21(3), 203–207.
- Dai, S. M., Matsuno, H., Nakamura, H., Nishioka, K., & Yudoh, K. (2004). Interleukin-18 enhances monocyte tumor necrosis factor alpha and interleukin-1beta production induced by direct contact with T lymphocytes: implications in rheumatoid arthritis. *Arthritis and rheumatism*, 50(2), 432–443.
- Dandona, P., Aljada, A., & Bandyopadhyay, A. (2004). Inflammation: the link between insulin resistance, obesity and diabetes. *Trends in immunology*, 25(1), 4–7.
- Denyer, A. L., Catchpole, B., Davison, L. J., & Canine Diabetes Genetics Partnership (2021). Genetics of canine diabetes mellitus part 1: Phenotypes of disease. *Veterinary journal (London, England: 270, 105611.*
- Diker, S. (2005). *İmmunoloji* (s.85-93). Medisan Yayınevi.
- Dinççaę N. (2011). Diabetes Mellitus Tanı ve Tedavisinde Güncel Durum, İç Hastalıkları Dergisi, 18,181-223.
- Eser, B. E., Yazgan, Ü. C., Gürses, S. A., & Aydın, M. (2016). Diabetes mellitus ve epigenetik Mekanizmalar/Diabetes mellitus and epigenetic mechanisms. *Dicle Tıp Dergisi*, 43(2), 375-382.

- Fantuzzi, G., Reed, D. A., & Dinarello, C. A. (1999). IL-12-induced IFN-gamma is dependent on caspase-1 processing of the IL-18 precursor. *The Journal of clinical investigation*, 104(6), 761–767.
- Goldberg R. B. (2009). Cytokine and cytokine-like inflammation markers, endothelial dysfunction, and imbalanced coagulation in development of diabetes and its complications. *The Journal of clinical endocrinology and metabolism*, 94(9), 3171–3182.
- Harada, A., Sekido, N., Akahoshi, T., Wada, T., Mukaida, N., & Matsushima, K. (1994). Essential involvement of interleukin-8 (IL-8) in acute inflammation. *Journal of leukocyte biology*, 56(5), 559–564.
- Harsunen, M. H., Puff, R., D’Orlando, O., Giannopoulou, E., Lachmann, L., Beylerlein, A., von Meyer, A., & Ziegler, A. G. (2013). Reduced blood leukocyte and neutrophil numbers in the pathogenesis of type 1 diabetes. *Hormone and metabolic research = Hormon- und Stoffwechselforschung = Hormones et metabolisme*, 45(6), 467–470.
- Hasegawa, G., Nakano, K., Sawada, M., Uno, K., Shibayama, Y., Ienaga, K., & Kondo, M. (1991). Possible role of tumor necrosis factor and interleukin-1 in the development of diabetic nephropathy. *Kidney international*, 40(6), 1007–1012.
- Ismail, N. A., Abd El Baky, A. N., Ragab, S., Hamed, M., Hashish, M. A., & Shehata, A. (2016). Monocyte chemoattractant protein 1 and macrophage migration inhibitory factor in children with type 1 diabetes. *Journal of pediatric endocrinology & metabolism: JPEM*, 29(6), 641–645.
- Kammoun, H. L., Allen, T. L., Henstridge, D. C., Barre, S., Coll, R. C., Lancaster, G. I., Cron, L., Reibe, S., Chan, J. Y., Bensellam, M., Laybutt, D. R., Butler, M. S., Robertson, A. A. B., O’Neill, L. A., Cooper, M. A., & Febbraio, M. A. (2018). Evidence against a role for NLRP3-driven islet inflammation in db/db mice. *Molecular metabolism*, 10, 66–73.
- Margaryan S, Kriegova E, Fillerova R, Smotkova Kraiczova V, Manukyan G. (2020) Hypomethylation of IL1RN and NFKB1 genes is linked to the dysbalance in IL1beta/IL-1Ra axis in female patients with type 2 diabetes mellitus. *PloS One* 15:e0233737. doi: 10.1371/journal.pone.0233737.
- Moneima A.A., Bakerya H.H., Allam G, (2018). The potential pathogenic role of IL-17/Th17 cells in both type 1 and type 2 diabetes mellitus, *Biomedicine & Pharmacotherapy* 101 287–292.
- Moriwaki, Y., Yamamoto, T., Shibutani, Y., Aoki, E., Tsutsumi, Z., Takahashi, S., Okamura, H., Koga, M., Fukuchi, M., & Hada, T. (2003). Elevated levels of interleukin-18 and tumor necrosis factor-alpha in serum of patients with type 2 diabetes mellitus: relationship with diabetic nephropathy. *Metabolism: clinical and experimental*, 52(5), 605–608.
- Nakamura, A., Shikata, K., Hiramatsu, M., Nakatou, T., Kitamura, T., Wada, J., Itoshima, T., & Makino, H. (2005). Serum interleukin-18 levels are associ-

ated with nephropathy and atherosclerosis in Japanese patients with type 2 diabetes. *Diabetes care*, 28(12), 2890–2895.

- Okamura, H., Tsutsui, H., Komatsu, T., Yutsudo, M., Hakura, A., Tanimoto, T., Torigoe, K., Okura, T., Nukada, Y., Hattori, K., Akita, K., Namba, M., Tanabe, F., Konishi, K., Fukuda, S., and Kurimoto, M. (1995). Cloning of a new cytokine that induces IFN-g production by T cells. *Nature* 378, 88–91,
- Orlenko, V. L., & Kravchuk, M. H. (2020). Role of Proinflammatory Cytokines in Pathogenesis of Arthropathies In Patients with Diabetes Mellitus. *Wiadomości lekarskie (Warsaw, Poland : 1960)*, 73(11), 2476–2481.
- Pickup J. C. (2004). Inflammation and activated innate immunity in the pathogenesis of type 2 diabetes. *Diabetes care*, 27(3), 813–823.
- Pickup, J. C., & Crook, M. A. (1998). Is type II diabetes mellitus a disease of the innate immune system?. *Diabetologia*, 41(10), 1241–1248.
- Pradhan, A. D., Manson, J. E., Rifai, N., Buring, J. E., & Ridker, P. M. (2001). C-reactive protein, interleukin 6, and risk of developing type 2 diabetes mellitus. *JAMA*, 286(3), 327–334.
- Rasier R, Artunay Ö, Yüzbaşıoğlu E, Şengül E, Görmüş U, Öncel M, Bahçecioglu H (2011). Diabetik retinopatili hastaların vitreus örneklerinde IL-8 ve TNF-A seviyeleri. *Retina-Vitreus*, 19(3), 190 - 193.
- Sepehri Z, Kiani Z, Afshari M, Kohan F, Dalvand A, Ghavami S. (2017). Inflammation and type 2 diabetes: An updated systematic review. *Immunol Lett* 192:97–103.
- Shehan N. R., Greig J. A. Thomson, Theo A. N., Timothy R. and Ethersia P. (2019). Inflammatory cytokines in type 2 diabetes mellitus as facilitators of hypercoagulation and abnormal clot formation, *Cardiovascular Diabetology*, 18:72
- Şimşek, A. & İçen, H. (2008). Kedi ve Köpeklerde Diabetes Mellitus. *Dicle Üniversitesi Veteriner Fakültesi Dergisi*, (1), 23-28 . Retrieved from <https://dergipark.org.tr/pub/duvetfd/issue/29536/317024>
- Sisi Li, Xuying Li, Xiangbin Xie, Xiao Wei, Cong Yu, Chi Wai Cheung, Zhengyuan Xia, Guogang Tian, “N-Acetylcysteine Attenuates Hyperalgesia in Rats with Diabetic Neuropathic Pain: Role of Oxidative Stress and Inflammatory Mediators and CXCR4”, *Journal of Diabetes Research*, vol. 2021, Article ID 8862910, 10 pages, 2021.
- Spranger, J., Kroke, A., Möhlig, M., Hoffmann, K., Bergmann, M. M., Ristow, M., Boeing, H., & Pfeiffer, A. F. (2003). Inflammatory cytokines and the risk to develop type 2 diabetes: results of the prospective population-based European Prospective Investigation into Cancer and Nutrition (EPIC)-Potsdam Study. *Diabetes*, 52(3), 812–817.
- Stuyt, R. J., Netea, M. G., Geijtenbeek, T. B., Kullberg, B. J., Dinarello, C. A., & van der Meer, J. W. (2003). Selective regulation of intercellular adhe-

sion molecule-1 expression by interleukin-18 and interleukin-12 on human monocytes. *Immunology*, 110(3), 329–334.

- Taşkın L. (2016). Doğum ve Kadın Sağlığı Hemşireliği. 15.baskı, Ankara, Akademisyen Kitapevi, s.259.
- Tong HV, Luu NK, Son HA, Hoan NV, Hung TT, Velavan TP, et al. (2017). Adiponectin and pro-inflammatory cytokines are modulated in Vietnamese patients with type 2 diabetes mellitus. *J Diabetes Investig* 8:295–305.
- Valle, A., Giamporcaro, G. M., Scavini, M., Stabilini, A., Grogan, P., Bianconi, E., Sebastiani, G., Masini, M., Maugeri, N., Porretti, L., Bonfanti, R., Meschi, F., De Pellegrin, M., Lesma, A., Rossini, S., Piemonti, L., Marchetti, P., Dotta, F., Bosi, E., & Battaglia, M. (2013). Reduction of circulating neutrophils precedes and accompanies type 1 diabetes. *Diabetes*, 62(6), 2072–2077.
- Wong, C. K., Ho, A. W., Tong, P. C., Yeung, C. Y., Kong, A. P., Lun, S. W., Chan, J. C., Lam, C. W. (2007). Aberrant activation profile of cytokines and mitogen-activated protein kinases in type 2 diabetic patients with nephropathy. *Clinical and experimental immunology*, 149(1), 123–131.
- Wuyts, A., Proost, P., Lenaerts, J. P., Ben-Baruch, A., Van Damme, J., & Wang, J. M. (1998). Differential usage of the CXC chemokine receptors 1 and 2 by interleukin-8, granulocyte chemotactic protein-2 and epithelial-cell-derived neutrophil attractant-78. *European journal of biochemistry*, 255(1), 67–73.
- Zheng, M., Wang, X., Guo, H., Fan, Y., Song, Z., Lu, Z., Wang, J., Zheng, C., Dong, L., Ma, Y., Zhu, Y., Fang, H., & Ye, S. (2021). The Cytokine Profiles and Immune Response Are Increased in COVID-19 Patients with Type 2 Diabetes Mellitus. *Journal of diabetes research*, 2021, 9526701.





## **CHAPTER 6**

### **IATROGENIC FACTORS THAT NEGATIVELY AFFECT THE PERIODONTIUM CAUSED BY ENDODONTIC TREATMENTS: AN OVERVIEW**

*Raif ALAN<sup>1</sup>, Arslan TERLEMEZ<sup>2</sup>*

---

1 Asst. Prof., DDS, PhD, Department of Periodontology, Faculty of Dentistry, Çanakkale Onsekiz Mart University, Çanakkale, Turkey. ORCID ID: 0000-0003-2602-3481

2 Assoc. Prof., DDS, PhD, Department of Endodontics, Faculty of Dentistry, Necmettin Erbakan University, Konya, Turkey. ORCID ID: 0000-0002-6092-4817

## INTRODUCTION

A healthy or stable periodontium, which is an essential requirement for a functional dentition and the long-term maintenance of the success of dental treatments (Shenoy & Rodrigues, 2007; Sirajuddin et al., 2015), has anatomical and functional relationships with the dental pulp. Therefore, it can be thought that a disease occurring in one structure may be the result or cause of the disease in another structure or vice versa (Dejean et al., 2009).

Pathways for the transition of infectious agents and irritants from the pulp to the periodontium or vice versa lead to the development of endodontic periodontal lesions (Simring & Goldberg, 1964). Infection can spread between the pulp and periodontal ligament over the apical foramen, accessory canals, and dentinal tubules. In addition, iatrogenic factors may play an important role in the above-mentioned relationship (Zehnder et al., 2002).

The purpose of the root canal treatment is to eliminate infected pulp tissue, to provide an environment that supports healing and to stop the progression of periapical pathology. Since periapical healing is important for the longevity of treated teeth (Fleming et al., 2010; Kebke et al., 2021; Riis et al., 2018; Zahran et al., 2021), endodontic treatment is an important component of dental applications (Chueh et al., 2003; Fong et al., 2018). In addition, it is important that clinicians perform high-quality procedure in line with all this information (Fong et al., 2018). Otherwise, endodontic treatment has the potential to be iatrogenic if the procedure is not performed properly (Adriaens et al., 1988).

Therefore, the aim of this article is to provide an overview of the most common types of iatrogenic factors that occur during endodontic treatment procedures and can affect the periodontium.

### Perforations

The mechanical or pathological linkage that combines the root canal to the external tooth surface is known as root perforation (American Association of Endodontists [AAE], 2003). Pathological root perforation is observed as a result of root resorption and/or caries, while iatrogenic perforations can happen at any stage during endodontic treatment. Procedural errors during or after access cavity and root canal preparation may lead to treatment failure and even an inflammatory response related with periodontal tissue and alveolar bone destruction (Estrela et al., 2018; Siew et al., 2019). Moreover, lack of knowledge about perforations and their effects can delay diagnosis and treatment. This, in turn, can cause problems leading to tooth loss (Estrela et al., 2018).

The incidence of perforation is reported between 0.7% and 10% in the literature (Eleftheriadis & Lambrianidis 2005; Fuss & Tropel 1996; Olcay et al., 2018). Kvinnsland et al. (1989) reported that 47% of all iatrogenic perforations occur during root canal cleaning and shaping, and 53% during root canal preparation for a post. The percentage of teeth extracted due to perforated endodontic failure is defined as 2.9% to 4.2% (Olcay et al., 2018; Toure et al., 2011).

As a result of perforations, infections spreading from the root canal system or periodontal tissues, or both, can inhibit healing and cause inflammation (Tsesis et al., 2006). In a study, it was shown that teeth with periodontal pocket formation adjacent to perforation have a 21 times higher risk of failure and ongoing inflammation compared to teeth with perforation but no periodontal pocket (Gorni et al., 2016). Therefore, it is essential to evaluate the periodontal condition of the tooth in question in all perforations (Krupp et al., 2013; Main et al., 2004).

Specific factors such as experience, place of the perforation, the duration from diagnosis to treatment, the material used for sealing, and presence of connection between perforation and oral cavity are important factors to be considered in the treatment of perforations (Fuss & Trope, 1996; Siew et al., 2015; Torabinejad et al., 2018). In addition, it is important to evaluate access to the canal and the possibility of closure of the defect (Kakani et al., 2015). Various materials have been proposed for use in root perforations: cavite, glass ionomer cements, super EBA, composite, and amalgam etc. (Dazey & Senia, 1990; Jew et al., 1982; Lee et al., 1993; Oynick & Oynick, 1985; Roane & Benenati, 1987). Today, the most preferred material is mineral trioxide aggregate (Rotstein, 2017). Other bioactive endodontic cements can achieve similar results, but there is a lack of clinical data available to date. Besides biological aspects, research should also focus on stabilizing the remaining tooth structure (Clauder, 2022).

### **Sodium Hypochlorite Accident**

Removal of deposits, bacteria and toxins in the cleaning and shaping of the root canal is generally considered an important factor in the success of the treatment. Since mechanical interventions alone are not sufficient for complete canal cleaning, irrigation solutions should be supportive and complementary to the endodontic preparation (Mehdipour et al., 2007).

Sodium hypochlorite (NaOCl) is the most preferred irrigation agent with its concentration ranging from 0.5% to 5.25% (Baumgartner & Cuenin, 1992), due to its excellent and effectual antibacterial property and tissue-dissolving capabilities (Zehnder, 2006). However, it has been reported that NaOCl irreversibly inhibits microbial enzymes and destroys cell membranes, thereby showing broad-spectrum bactericidal, sporicidal

and virucidal activity (McDonnell & Russell 1999). However, this effect is not limited to necrotic tissue; NaOCl is also caustic when in contact with vital tissue, even at low concentration (Barnhart et al., 2005; Chang et al., 2001; Heling et al., 2001; Pashley et al., 1985). Any opening from the root canal structure to the periodontal ligament should be considered as an exit portal through which potentially destructive endodontic products can pass (Ruddle, 2017). Poor isolation may allow extrusion of NaOCl and complications such as necrosis of adjacent bone, paresthesia, hematoma, trismus may occur (Retamozo et al., 2010; Zehnder, 2006). In addition, accidental injection of NaOCl into the periradicular zone leads to sudden intense pain accompanied by a burning sensation, edema and progressive swelling. Skin hematoma and ecchymosis may occur simultaneously (Hales et al., 2001; Motta et al., 2009).

NaOCl accident is very rare (Kleier et al., 2008), considering there are so many endodontic treatments that use NaOCl per year (Zhu et al., 2013). NaOCl accidents are more common in maxillary teeth than mandibular teeth due to less bone thickness and density and thin vestibular cortex (Al-rahabi et al., 2019; Guivarch et al., 2017). In addition, hypotheses including multiple sessions and apical fenestration were formed. (Boutsioukis et al., 2013; Ozdemir et al., 2022).

In hypochlorite injuries that occur during endodontic treatment, the clinician's ability to diagnose the condition early is the key to successful treatment of this condition (Shetty et al., 2020). In case of over-preparation of apical foramens, improper working length, presence of open apex; great care should be taken or an alternative irrigation solution considered to prevent NaOCl accident (Mehdipour et al., 2007; Usmani et al., 2020).

In case of alarming swelling of the affected area, the patient should be relieved. In addition, satisfactory control of the pain can be obtained with narcotic analgesics, but aspirin and NSAIDs should not be preferred in the acute period due to interstitial hemorrhage in soft tissue. On the first day, cold compresses can be helpful in reducing pain and inflammation. Then, a hot compress is preferred to increase the circulation of the affected area and shorten the healing time of massive ecchymosis (Hales et al., 2001; Mehdipour et al., 2007). Antibiotic prophylaxis is also recommended to minimize the risk of any secondary infections (Spencer et al., 2007). In addition, a CBCT scan may be indicated to determine the extent of tissue damage, the anatomy of the periapical region and possible cause, and to provide sufficient information to prevent recurrence (Farook et al., 2014; Psimma et al., 2019). After patients have recovered, endodontic treatments should be performed as soon as possible, respecting the safety conditions and treatment steps (Salvadori et al., 2022).

## **Root Canal Filling**

It has been shown that there is a direct relationship between the condition of the root canal filling and the periradicular health (Moradi & Gharechahi 2014; Román-Richon et al., 2014). Numerous observational studies have revealed the incidence of inadequately obturated root canals in relation to normal periapical tissue, and epidemiological statistics presented a prevalence of inadequate root canal obturation of up to 72.4% in different parts of the world and showed the results of treatment presenting apical periodontitis in 87.0% of these teeth (Berlinck et al., 2015; Nur et al., 2014; Van der Veken et al., 2017). According to the European Association of Endodontists, acceptable endodontic treatment shows a consistent conical form in the canal from the coronal to the apical portion and is densely filled with no gaps between the occlusive material and the canal wall (European Society of Endodontology, 2006).

Inadequate filling of root canals is usually observed as a result of improper instrumentation or the creation of a canal ledge during mechanical instrumentation. Improper instrumentation often occurs due to incorrect determination of working length and repeated canal aperture during inadequate irrigation and instrumentation, thus leading to accumulation of debris, and occlusion (Lin et al., 2005). On the other hand, instrumentation resulting from incorrect measurement of the working length through the apical foramen, incomplete root apex formation or apical root resorption, often results in overfilling of root canals. In such cases, it becomes more difficult to create an apical stop, which leads to overfilling. Numerous studies show that overfilling adversely affects the prognosis of treatment (Kerekes & Tronstad, 1979; Sjögren et al., 1990; Strindberg, 1956), and also that filling materials may be perceived as foreign object and cause irritation in periradicular region (Koppang et al., 1989; Nair et al., 1990; Yusuf, 1982).

To prevent such accidents, roots and surrounding structures must be clearly identified radiographically. It is critical to use obturation materials that are well tolerated by the body after treatment. The clinician should apply multiple validation strategies (electronic, radiographic, tactile, and paper points) in determining the working length. Also, it is important to use a resistance form to control overfillings. In addition, it is important to respect the flow properties of the materials and the heat energy used when using thermoplastic techniques (AAE, 2020).

## **Intra-ligamentary Anesthesia**

It is impossible to reach and treat the pulp without successful anesthesia in endodontic treatment. In some cases, it may not be possible to achieve success in primary anesthesia for inflammatory, anatomical and

patient or physician-related factors. Although successful primary anesthesia has been achieved in the presence of pulpal inflammation, sometimes an effective pulpal anesthesia may not be obtained. In such cases, auxiliary and additional anesthesia techniques are used. Intra-ligamentary anesthesia is among these methods that endodontists apply in such cases.

In intra-ligamentary anesthesia, anesthetic solution is given under pressure with a special compressive injector through the periodontal ligament space. It is aimed to reach the anesthetic solution up to the apical part of the tooth by applying the pressure for a long time and at the same strength, and to provide an optimum effect of anesthesia by giving it from different points of the periodontal space of the tooth. During this procedure, temporary damage occurs in the gingival sulcus, and in some cases, bacterial colonization in the gingival region can be pushed apically with compressed fluid. This may cause temporary or permanent periodontal injury and patient discomfort.

### **Applying the Rubber Dam**

There is evidence that many general dentists unnecessarily put themselves at risk by not using a rubber dam when performing endodontic procedures (Anabtawi et al., 2013). During routine operative procedures, the rubber-dam is extremely beneficial in preserving the surrounding gingival tissue (Sirajuddin et al., 2015). However, to ensure exact sanitization, it is recommended to use a rubber-dam for dental isolation, which reduces the risk of cross-infection, the possibility of aspiration and swallowing of instruments, and protects vital tissues from the cytotoxic effect of irritants (Estrela et al., 2009; Estrela & Estrela, 2009).

Especially when placing the rubber-dam clamp, it should be ensured that it fits tightly to the hard tissues of the tooth. However, it should not remain in place for long periods of time as ischemia will cause tissue sloughing and subsequent recession, and should also not be forced subgingivally in a way that violates the biological width (Shenoy & Rodrigues, 2007). In addition, in dental traumatic injuries where teeth are splinted, care should be taken during rubber-dam application and wedget should be used instead of clamp to fix the rubber-dam (Tapashetti et al., 2018).

### **CONCLUSION**

There is a strong association between periodontal disease and inflammatory and degenerative changes in the pulp, and there are numerous oral conditions in which elective endodontic treatments are required to preserve the integrity of the periodontium, which is the basis of a functional dentition (Khaled & Pahuja, 2019). Since the integrity of the periodontium can be affected by endodontic pathogens and their products, they should be

removed by root canal treatment (Jivoinovici et al., 2014).

Iatrogenic factors play an important role in dental diseases. When treating patients, clinicians must have clear goals to avoid unintended consequences of treatment (Usmani et al., 2020) and consider the consequences of an unplanned treatment, because in the process of rectifying a problem another problem with greater consequences, such as tooth loss, may arise. Therefore, a thorough understanding of the factors and their early correction can help prevent many cases that may become hopeless at a later stage (Bhat et al., 2015; Latheef et al., 2015).

Clinicians' continuous follow-up of technological developments and being professionally up-to-date (Alrahabi et al., 2019) will contribute positively to the diagnosis and decision-making process, and ultimately characterize the awareness recommended for both the prevention and management of iatrogenic factors in order to increase the predictability of treatment outcome (Alves et al., 2021). Moreover, due to the complex nature of these infections, an interdisciplinary approach with good collaboration between Endodontists, Periodontists and Microbiologists is recommended (Al-Fouzan, 2014).

## REFERENCES

- Adriaens, P.A., De Boever, J.A., & Loesche, W.J. (1988), Bacterial invasion in-root cementum and radicular dentin of periodontally diseased teeth in humans. *Journal of Periodontology*, 59,222-230.
- Al-Fouzan, K.S. (2014), A new classification of endodontic-periodontal lesions. *International Journal of Dentistry*, 2014:919173.
- Alrahabi, M., Zafar, M.S., & Adanir, N. (2019), Aspects of Clinical Malpractice in Endodontics. *European Journal of Dentistry*, 13, 450–458.
- Alves, R.A.A., Morais, A.L.G., Izelli, T.F., Estrela, C.R.A., & Estrela, C.A. (2021), Conservative Approach to Surgical Management of Root Canal Perforation. *Case Reports in Dentistry*, 6633617.
- American Association of Endodontists. (2003), Glossary of Endodontic terms. 7th ed. American Association of Endodontists, Chicago.
- American Association of Endodontists. (2020), Treatment Standards. available from: [https://www.aae.org/specialty/wp-content/uploads/sites/2/2018/04/TreatmentStandards\\_Whitepaper.pdf](https://www.aae.org/specialty/wp-content/uploads/sites/2/2018/04/TreatmentStandards_Whitepaper.pdf)
- Anabtawi, M.F., Gilbert, G.H., Bauer, M.R., Reams, G., Makhija, S.K., Benjamin, P.L., & Williams, O.D.; National Dental Practice-Based Research Network Collaborative Group. (2013), Rubber dam use during root canal treatment: findings from The Dental Practice-Based Research Network. *The Journal of the American Dental Association*, 144(2), 179-186.
- Barnhart, B.D., Chuang, A., Lucca, J.J., Roberts, S., Liewehr, F., & Joyce, A.P. (2005), An in vitro evaluation of the cytotoxicity of various endodontic irrigants on human gingival fibroblasts. *Journal of Endodontics*, 31, 613-615.
- Baumgartner, J.C., & Cuenin, P.R. (1992), Efficacy of several concentrations of sodium hypochlorite for root canal irrigation. *Journal of Endodontics*, 18, 605–612.
- Berlinck, T., Tinoco, J.M., Carvalho, F.L., Sassone, L.M., & Tinoco, E.M. (2015), Epidemiological evaluation of apical periodontitis prevalence in an urban Brazilian population. *Brazilian Oral Research*, 29(1), 1-7.
- Bhat, A., Sirajuddin, S., Prabhu, S.S., Chungkham, S., & Bilichodmath, C. (2015), Iatrogenic Damage to the Periodontium Caused by Endodontic Treatment Procedures: An Overview. *The Open Dentistry Journal*, 9, 214-216.
- Boutsioukis, C., Psimma, Z., & van der Sluis, L.W. (2013), Factors affecting irrigant extrusion during root canal irrigation: A systematic review. *International Endodontic Journal*, 46, 599–618.
- Chang, Y.C., Huang, F.M., Tai, K.W., & Chou, M.Y. (2001), The effect of sodium hypochlorite and chlorhexidine on cultured human periodontal ligament cells. *Oral Surgery, Oral Medicine, Oral Pathology, Oral Radiology, and Endodontics*, 92, 446-450.



- Chueh, L.H., Chen, S.C., Lee, C.M., Hsu, Y.Y., Pai, S.F., Kuo, M.L., Chen, C.S., Duh, B.R., Yang, S.F., Tung, Y.L., & Hsiao, C.K. (2003), Technical quality of root canal treatment in Taiwan. *International Endodontic Journal*, 36(6), 416-422.
- Clauder, T. (2022), Present status and future directions –Managing perforations. *International Endodontic Journal*, 55, 872–891.
- Dazey, S., & Senia, E.S. (1990), An in vitro comparison of the sealing ability of materials placed in lateral root perforations. *Journal of Endodontics*, 16, 19–23.
- Dejean, K.S., Reinheimer, D.M., Piva, M.R., Silva, L.C.F., & Martins Filho, P.R.S. (2009), Disseminação de infecção odontogênica originada de uma lesão endoperiodontal - relato de caso. *Academia Tiradentes de Odontologia. Revista Online de Odontologia*, 10, 861-866.
- Eleftheriadis, G.I. & Lambrianidis, T.P. (2005), Technical quality of root canal treatment and detection of iatrogenic errors in an undergraduate dental clinic. *International Endodontic Journal*, 38, 725–734.
- Estrela, C., Alencar, A.H.G., Silva, J.A., & Estrela, C.R.A. (2009), Endodontic treatment planning. In: Estrela C. *Endodontic Science*. 2 ed. São Paulo-SP, Brazil: *Artes Médicas*, 1, p49-80.
- Estrela, C., Decurcio, D.A., Rossi-Fedele, G., Silva, J.A., Guedes, O.A., & Borges, A.H. (2018), Root perforations: a review of diagnosis, prognosis and materials. *Brazilian Oral Research*, 32, e73(133-146).
- Estrela, C.R.A., & Estrela, C. (2009), Endodontic infection control. In: Estrela C. *Endodontic Science*. 2 ed. São Paulo-SP, Brasil: *Artes Médicas*, 1, p497-530.
- European Society of Endodontology. (2006), Quality guidelines for endodontic treatment: consensus report of the European Society of Endodontology. *International Endodontic Journal*, 39(12), 921–930.
- Farook, S.A., Shah, V., Lenouvel, D., Sheikh, O., Sadiq, Z., Cascarini, L., & Webb, R. (2014), Guidelines for management of sodium hypochlorite extrusion injuries. *British Dental Journal*, 217(12), 679-684.
- Fleming, C.H., Litaker, M.S., Alley, L.W., & Eleazer, P.D. (2010), Comparison of classic endodontic techniques versus contemporary techniques on endodontic treatment success. *Journal of Endodontics*, 36(3), 414-418.
- Fong, W., Heidarifar, O., Killough, S., Lappin, M.J., & El Karim, I.A. (2018), An audit on technical quality of root fillings performed by undergraduate students. *International Endodontic Journal*, 51, e197-203.
- Fuss, Z. & Trope, M. (1996), Root perforations: classification and treatment choices based on prognostic factors. *Endodontics & Dental Traumatology*, 12, 255–264.
- Gorni, F.G., Andreano, A., Ambrogi, F., Brambilla, E., & Gagliani, M. (2016), Pa-

- tient and clinical characteristics associated with primary healing of iatrogenic perforations after root canal treatment: results of a long term Italian study. *Journal of Endodontics*, 42, 211-215.
- Guivarc'h, M., Ordioni, U., Ahmed, H.M., Cohen, S., Catherine, J.H., & Bukiet, F. (2017), Sodium Hypochlorite Accident: A Systematic Review. *Journal of Endodontics*, 43, 16–24.
- Hales, J.J., Jackson, C.R., Everett, A.P., & Moore, S.H. (2001), Treatment protocol for the management of a sodium hypochlorite accident during endodontic therapy. *General Dentistry*, 49(3), 278-281.
- Heling, I., Rotstein, I., Dinur, T., Szwec-Levine, Y., & Steinberg, D. (2001), Bactericidal and cytotoxic effects of sodium hypochlorite and sodium dichloroisocyanurate solutions in vitro. *Journal of Endodontics*, 27, 278-280.
- Jew, R.C., Weine, F.S., Keene, J.J., & Smulson, M.H. (1982), A histologic evaluation of periodontal tissues adjacent to root perforations filled with Cavit. *Oral Surgery, Oral Medicine, Oral Pathology and Oral Radiology*, 54, 124–135.
- Jivoinovici, R., Suci, I., Dimitriu, B., Perlea, P., Bartok, R., Malita, M., & Ionescu, C. (2014), Endo-periodontal lesion--endodontic approach. *Journal of Medicine and Life*, 7(4), 542-544.
- Kakani, A.K., Veeramachaneni, C., Majeti, C., Tummala, M., & Khiyani, L. (2015), A review on perforation repair materials. *Journal of Clinical and Diagnostic Research*, 9(9), ZE09-13.
- Kebke, S., Fransson, H., Brundin, M., & Mota de Almeida, F.J. (2021), Tooth survival following root canal treatment by general dental practitioners in a Swedish county - a 10-year follow-up study of a historical cohort. *International Endodontic Journal*, 54(1), 5-14.
- Kerekes, K., & Tronstad, L. (1979), Long-term results of endodontic treatment performed with a standardized technique. *Journal of Endodontics*, 5(3), 83-90.
- Khaled, Y., & Pahuja, B.K. (2019), Condition requiring endodontic treatment to maintain the integrity of periodontium. *Journal of Dental and Maxillofacial Research*, 2(3), 54-58.
- Kleier, D.J., Averbach, R.E., & Mehdipour, O. (2008), The sodium hypochlorite accident: Experience of diplomates of the American Board of Endodontics. *Journal of Endodontics*, 34, 1346–1350.
- Koppang, H.S., Koppang, R., Solheim, T., Aarnes, H., & Stolen, S.O. (1989), Cellulose fibers from endodontic paper points as etiologic factor in post-endodontic periapical granulomas and cysts. *Journal of Endodontics*, 15, 369-372.
- Krupp, C., Bargholz, C., Brüsehaber, M. & Hülsmann, M. (2013), Treatment outcome after repair of root perforations with mineral trioxide aggregate: a

- retrospective evaluation of 90 teeth. *Journal of Endodontics*, 39, 1364–1368.
- Kvinnslund, I., Oswald, R.J., Halse, A., & Grønningsaeter, A.G. (1989), A clinical and roentgenological study of 55 cases of root perforation. *International Endodontic Journal*, 22, 75-84.
- Latheef, P., Sirajuddin, S., Gundapaneni, V., Mn, K., & Apine, A. (2015), Iatrogenic Damage to the Periodontium Caused by Periodontal Treatment Procedures. *The Open Dentistry Journal*, 9, 203-207.
- Lee, S.J., Monsef, M., & Torabinejad, M. (1993), Sealing ability of a mineral trioxide aggregate for repair of lateral root perforations. *Journal of Endodontics*, 19, 541–544.
- Lin, L.M., Rosenberg, P.A., & Lin, J. (2005), Do procedural errors cause endodontic treatment failure? *The Journal of the American Dental Association*, 136(2), 187-193.
- Main, C., Mirzayan, N., Shabahang, S. & Torabinejad, M. (2004), Repair of root perforations using mineral trioxide aggregate: a long-term study. *Journal of Endodontics*, 30, 80–83.
- McDonnell, G., & Russell, A.D. (1999), Antiseptics and disinfectants: activity, action, and resistance. *Clinical Microbiology Reviews*, 12(1), 147-179.
- Mehdipour, O., Kleier, D.J., & Averbach, R.E. (2007), Anatomy of sodium hypochlorite accidents. *Compendium of Continuing Education in Dentistry*, 28(10), 544-546.
- Moradi, S., & Gharechahi, M. (2014), Quality of root canal obturation performed by senior undergraduate dental students. *Iranian Endodontic Journal*, 9(1), 66–70.
- Motta, M.V., Chaves-Mendonca, M.A., Stirton, C.G., & Cardozo, H.F. (2009), Accidental injection with sodium hypochlorite: report of a case. *International Endodontic Journal*, 42(2), 175-182.
- Nair, P.N., Sjögren, U., Krey, G., & Sundqvist, G. (1990), Therapy-resistant foreign body giant cell granuloma at the periapex of a root-filled human tooth. *Journal of Endodontics*, 16, 589-595.
- Nur, B.G., Ok, E., Altunsoy, M., Aglarci, O.S., Colak, M., & Gungor, E. (2014), Evaluation of technical quality and periapical health of root-filled teeth by using cone-beam CT. *Journal of Applied Oral Science*, 22, 502-508.
- Olcay, K., Ataoglu, H. & Sema Belli, S. (2018), Evaluation of related factors in the failure of endodontically treated teeth: a cross sectional study. *Journal of Endodontics*, 44, 38–45.
- Oynick, J., & Oynick, T. (1985), Treatment of endodontic perforations. *Journal of Endodontics*, 11, 191-192.
- Ozdemir, O., Hazar, E., Kocak, S., Saglam, B.C., & Kocak, M.M. (2022), The frequency of sodium hypochlorite extrusion during root canal treatment:

- An observational clinical study. *Australian Dental Journal*, 67, S57-S64.
- Pashley, E.L., Birdsong, N.L., Bowman, K., & Pashley, D.H. (1985), Cytotoxic effects of NaOCl on vital tissue. *Journal of Endodontics*, 11, 525-528.
- Psimma, Z., & Boutsoukis, C. (2019), A critical view on sodium hypochlorite accidents. *ENDO Endodontic Practice Today*, 13(2), 165-175.
- Retamozo, B., Shabahang, S., Johnson, N., Aprecio, R.M., & Torabinejad, M. (2010), Minimum contact time and concentration of sodium hypochlorite required to eliminate *Enterococcus faecalis*. *Journal of Endodontics*, 36, 520-523.
- Riis, A., Taschieri, S., Del Fabbro, M., & Kvist T. (2018), Tooth Survival after Surgical or Nonsurgical Endodontic Retreatment: Long-term Follow-up of a Randomized Clinical Trial. *Journal of Endodontics*, 44(10), 1480-1486.
- Roane, J.B., & Benenati, F.W. (1987), Successful management of a perforated mandibular molar using amalgam and hydroxylapatite. *Journal of Endodontics*, 13, 400-404.
- Román-Richon, S., Faus-Matoses, V., Alegre-Domingo, T., & Faus-Llácer, V.J. (2014), Radiographic technical quality of root canal treatment performed ex vivo by dental students at Valencia University Medical and Dental School, Spain. *Medicina Oral, Patología Oral, Cirugía Bucal*, 19(1), e93-97.
- Rotstein, I. (2017), Interaction between endodontics and periodontics. *Periodontology 2000*, 74(1), 11-39.
- Ruddle, C.J. (2017), Endodontic Disinfection: The Sonic Advantage. *Dentistry Today*, 36(6), 84, 86-87.
- Salvadori, M., Venturi, G., Bertoletti, P., Francinelli, J., Tonini, R., Garo, M.L., & Salgarello, S. (2022), Sodium Hypochlorite Accident during Canal Treatment: Report of Four Cases Documented According to New Standards. *Applied Sciences*, 12(17), 8525.
- Shenoy, V.K., & Rodrigues, S. (2007), Iatrogenic dentistry and the periodontium. *The Journal of Indian Prosthodontic Society*, 7, 17-20.
- Shetty, S.R., Al-Bayati, S.A.A.F., Narayanan, A., Hamed, M.S., Abdemagy, H.A.E., & Shetty, P. (2020), Sodium hypochlorite accidents in dentistry. A systematic review of published case reports. *Stomatologija*, 22(1), 17-22.
- Siew, K., Lee, A.H., & Cheung, G.S. (2015), Treatment outcome of repaired root perforation: a systematic review and meta-analysis. *Journal of Endodontics*, 41(11), 1795-1804.
- Siew, K.L., Goh, V., Goo, C.L., Corbet, E.F., & Leung, W.K. (2019), The Periodontal-Endodontic Relationship, What Do We Know?. In Jane Manakil (Ed.), *Periodontology and Dental Implantology*. London: *IntechOpen*, 229-252.
- Simring, M., & Goldberg, M. (1964), The Pulpal Pocket Approach: Retrograde

- Periodontitis. *Journal of Periodontology*, 35(1), 22–48.
- Sirajuddin, S., Narasappa, K.M., Gundapaneni, V., Chungkham, S., & Walikar, A.S. (2015), Iatrogenic Damage to Periodontium by Restorative Treatment Procedures: An Overview. *The Open Dentistry Journal*, 9, 217-222.
- Sjögren, U., Hagglund, B., Sundqvist, G., & Wing, K. (1990), Factors affecting the long-term results of endodontic treatment. *Journal of Endodontics*, 16, 498-504.
- Spencer, H.R., Ike, V., & Brennan, P.A. (2007), Review: the use of sodium hypochlorite in endodontics—potential complications and their management. *British Dental Journal*, 202(9), 555-559.
- Strindberg, L.Z. (1956), The dependence of the results of pulp therapy on certain factors: an analytic study based on radiographic and clinical follow-up examination. *Acta Odontologica Scandinavica*, 14, 1-175.
- Tapashetti, S., S, A., Mahale, P., & Sattur, A. (2018), Iatrogenic avulsion of a tooth - an endodontic mishap caused by rubber dam clamp - a case report. *International Journal of Science and Research*, 7(2), 460-461.
- Torabinejad, M., Parirokh, M., & Dummer, P.M. (2018), Mineral trioxide aggregate and other bioactive endodontic cements: an updated overview - part II: other clinical applications and complications. *International Endodontic Journal*, 51(3), 284-317.
- Toure, B., Faye, B., Kane, A.W., Lo, C.M., Niang, B. & Boucher, Y. (2011), Analysis of reasons for extraction of endodontically treated teeth: a prospective study. *Journal of Endodontics*, 37, 1512–1515.
- Tsesis, I., Rosen, E., Schwartz-Arad, D., & Fuss, Z. (2006), Retrospective evaluation of surgical endodontic treatment: Traditional versus modern technique. *Journal of Endodontics*, 32(5), 412-416.
- Usmani, A., Bhati, C., Kaushik, M., & Ahmad, A. (2020), Iatrogenic Factors and Oral Health. *Medico Legal Update*, 20(1), 180-186.
- Van der Veken, D., Curvers, F., Fieuws, S., & Lambrechts, P. (2017), Prevalence of apical periodontitis and root filled teeth in a Belgian subpopulation found on CBCT images. *International Endodontic Journal*, 50, 317–329.
- Yusuf, H. (1982), The significance of presence of foreign material periapically as a cause of failure of root canal treatment. *Oral surgery, oral medicine, oral pathology, oral radiology, and endodontics*, 54, 566-574.
- Zahrán, S., Patel, S., Koller, G., & Mannocci, F. (2021), The impact of an enhanced infection control protocol on molar root canal treatment outcome - a randomized clinical trial. *International Endodontic Journal*. 54(11), 1993-2005.
- Zehnder, M. (2006), Root canal irrigants. *Journal of Endodontics*, 32, 389-398.
- Zehnder, M., Gold, S.I., & Hasselgren, G. (2002), Pathologic interactions in pulpal and periodontal tissues. *Journal of Clinical Periodontology*, 29(8),

663-671.

Zhu, W.C., Gyamfi, J., Niu, L.N., Schoeffel, G.J., Liu, S.Y., Santarcangelo, F., Khan, S. Tay, K.C., Pashley, D.H., & Tay, F.R. (2013), Anatomy of sodium hypochlorite accidents involving facial ecchymosis-A review. *Journal of Dentistry*, 41, 935–948.



## **CHAPTER 7**

# **CURRENT REHABILITATION APPROACH IN PERIPHERAL VESTIBULAR DISORDERS: A REVIEW ON TASK- ORIENTED TRAINING**

*Yasemin APAYDIN<sup>1</sup>, Umut APAYDIN<sup>2</sup>*

---

1 Arş. Gör. Dr. Recep Tayyip Erdoğan Üniversitesi Güneysu Fizik Tedavi ve Rehabilitasyon Yüksekokulu ORCID: 0000-0001-6630-2632

2 Dr. Öğr. Üyesi Karadeniz Teknik Üniversitesi Sağlık Bilimleri Fakültesi, Fizyoterapi ve Rehabilitasyon Bölümü ORCID: 0000-0002-0866-5870

## INTRODUCTION:

Peripheral vestibular disorder is a heterogeneous disorder that occurs due to unilateral or bilateral involvement of the peripheral vestibular organs in the inner ear, characterized by dizziness, balance disorder, visual blurring with head movements, postural instability and gait problems (Hall et al., 2016). In peripheral vestibular disorder, which is an important cause of dizziness, failure to receive appropriate treatment after the onset of the disease may cause dizziness to become chronic. Chronic dizziness, balance and gait problems increase the risk of falling, and decrease the individual's independence in daily living activities. Thus, these problems lead to restrictions on the quality of life (Lee & Choi-Kwon, 2009). Therefore, treatment plays an important role in peripheral vestibular disorders.

In the treatment of vestibular disorders, medical and surgical approaches, as well as vestibular rehabilitation plays an important role (Yığider & Ayaz, 2018). Medications are usually aimed at suppressing the vestibular system, controlling symptoms such as nausea, or specific disease processes such as infection control. Surgery may be required in cases such as perilymphatic fistula repair or acoustic neuroma removal (Rossi-Izquierdo, Santos-Pérez, & Soto-Varela, 2011). Vestibular rehabilitation, which is widely used in vestibular disorders, is a method of exercise and behavior change that was founded by Cawthorne and Cooksey in the 1940s (Arnold, Stewart, Moor, Karl, & Reneker, 2017). In Cawthorne and Cooksey's original vestibular rehabilitation protocol, a set of exercises of increasing difficulty level was used to achieve adaptation in the vestibular system. The purpose of these exercises are; to improve the coordination between eye and head movements, to enable the eyes to move independently of head movements, and to improve the adaptation of the vestibular system by applying head movements that cause dizziness. Thus, it is aimed to reduce vestibular symptoms that occur in daily life activities (Hillier & McDonnell, 2016; McDonnell & Hillier, 2015).

The primary treatment approach in individuals with peripheral vestibular disorders is based on exercise (Hall et al., 2016). A Cochrane review published in 2015 presented moderate-to-strong evidence that vestibular rehabilitation is a safe and effective treatment for people with peripheral vestibular dysfunction (McDonnell & Hillier, 2015).

Vestibular rehabilitation aims to reduce dizziness, improve gaze stabilization and postural control, and increase participation in functional activities and quality of life (Whitney, Alghwiri, & Alghadir, 2016). Traditional vestibular rehabilitation approaches includes gaze stabilization exercises, balance and gait training, familiarization exercises, and general conditioning exercises (Whitney et al., 2016).



Nowadays, vestibular rehabilitation approaches are mostly based on the systems model of motor control, plasticity, the principle of motor learning, and the fundamentals of functional movement. Rehabilitation approaches based on motor learning are body weight supported treadmill training, virtual reality therapy, robotic rehabilitation, restrictive compulsive motion therapy, repetitive station training and task-oriented training (Elbeltagy & Abd El-Hafeez, 2018; Rosiak, Szczepanik, Woszczak, Lucas-Grzelczyk, & Józefowicz-Korczyńska, 2019; Sestak, Maslovara, Zubcic, & Vceva, 2020; Smółka et al., 2020).

### **Task-Oriented Training**

The task-oriented approach is based on the systems model of motor control and the recent motor development and motor learning literature (I. J. Hubbard, Parsons, Neilson, & Carey, 2009; Schmidt, Lee, Winstein, Wulf, & Zelaznik, 2018). It is based on “the best way to learn a task is to train specifically for that task” (Bayona, Bitensky, Salter, & Teasell, 2005).

Task-oriented training focuses on improving performance on functional tasks via purposeful repetition and practise. Task-oriented training provides maximum learning by providing plastic changes in the neural pathway and focusing on the training of functional tasks rather than impairment such as muscle weakness (Richards, Stewart, Woodbury, Senesac, & Cauraugh, 2008).

With task-oriented training, “real world” or everyday tasks are often used as a therapy tool in functional recovery. It aims to achieve optimal function by ensuring that the patient performs daily activities adequately (I. J. Hubbard et al., 2009).

There are strategies to guide the clinical framework of task-oriented training. Task-oriented training should be context-related, randomly ordered, repeatable, oriented towards whole task reconstruction, and positively reinforced (I. J. Hubbard et al., 2009).

These strategies are described below.

Strategy 1: Task-oriented training have to be related to the patient and the content.

The task must be ‘real life’ or context specific. For example; if a patient is relearning to use fork and spoon, they should do so while seated and, if possible, with “real” food and using normal spoon, fork and plate. This approach promotes the movement to construct the treatment environment in many neurorehabilitation settings to reflect the natural house and/or community context. This can also be called enriching the environment (I. J. Hubbard et al., 2009).

Strategy 2: In task-oriented training, the exercises should be randomly ordered.

Task variability is important to increase ‘generalization of learning to new tasks’. It is also shown that using random sequential training facilitates memory and transfer, thereby increasing the generalizability of the task (Bayona et al., 2005; Davis, 2006; Teasell, Bayona, & Bitensky, 2005). On the other hand, task-oriented training should not be too task-specific and should not be applied in a single order. Therefore, therapists should plan their random therapy programme and task.

Strategy 3: Task-oriented training have to be repeatable.

Task-oriented training have to be repeatable and include back-to-back practice without rest (Schmidt et al., 2018; Winstein & Stewart, 2006). According to this strategy, the saying “practice makes perfect” applies. It is stated that the more a task is practiced, the better the general performance. (Blennerhassett & Dite, 2004; Mathiowetz, Nilsen, & Gillen, 2015). On the other hand, although it is stated that the specificity of the task is more important than the intensity and that high-intensity treatment strategies are not administered by the patients, task-oriented training has a significant importance (Page, 2003).

In addition, it should be considered that patients do very little most of the day and training should be provided with the maximum possible repetition and professionally challenging (Bernhardt, Chan, Nicola, & Collier, 2007; I. Hubbard & Parsons, 2007).

Strategy 4: Task-oriented training should aim at reproducing the entire task.

When creating a plan for treatment, the therapist:

- Separate a task into its components
- Evaluate patient performance in every component of the task
- Determine which skills and/or components are negatively affected and why
- Formulate a treatment plan that targets the mismatch between ‘I can’ and ‘I need/want to’.

Task-oriented training should begin with skill acquisition and clustered practice (shaping) of individual component parts, eventually reassembling some, most, and possibly all of the component parts, and progressing towards their normal ordering. However, in the midst of all the planning, definition, goal setting, documentation, and termination planning, all task attainment in the neurorehabilitation setting can be lost day by day. Howe-

ver, the main goal should be to restructure the entire task to maintain focus and motivation.(Davis, 2006; Kelly, Foxe, & Garavan, 2006; Mathiowetz et al., 2015).

Strategy 5: Task-oriented training have to be positively reinforced.

Task-oriented training should contain timely and positive feedback, but all feedback should disappear over time to avoid unnecessary dependency. Therapists can improve the feedback environment by using commentary and positive encouragement. However, this increased reinforcement and artificial feedback should be lost as it can be maladaptive. Also, the feedback used should always be positive (Davis, 2006; Dobkin & Carmichael, 2005).

### **Task-Oriented Training and Motor Learning**

The foundations of task-oriented training are based on the principle of motor learning. Motor learning refers to the practice or experience-related processes that lead to the acquisition/regaining of relatively permanent mobility (Schmidt et al., 2018). The relatively permanent change in behavior is what separates learning from temporary improvements in performance. For example, after performing a transfer several times, a patient may remember how to do it and thus show an improvement in performance. However, if the patient cannot remember how to transfer the next day, the task is not learned. Therefore, performance must be reassessed later to predict learning or relatively permanent changes (Poole, 1991).

Factors affecting motor learning are learning stages, task type, feedback and practice. All these factors should be considered in the planning of rehabilitation programs. In particular, it is stated that practice and feedback are the two strongest variables of motor learning (Schmidt., 1988).

There are 3 stages of motor learning: cognitive, relational and autonomous stage (Fitts & Posner, 1967). In the first or cognitive stage, the individual tries to understand the requirements of the motor task. He/she has a vague idea of the task but is unsure how to do it. It deals with figuring out what to do and how to do it by getting information and feedback from the trainer (Gentile, 1972). In the second or relational stage, the individual begins to develop his skill. An individual's movements become more consistent and show fewer errors through constant practice and repetition. In the third or autonomous stage, the skill becomes automatic. The individual has learned the motor skill and can perform it with little cognitive effort without considering specific movement features (Poole, 1991).

In task-oriented training, motor learning takes place in a real environment, in random order and with multiple repetitive, positively reinforced strategies based on task reconstruction (I. J. Hubbard et al., 2009). Alt-

though these strategies are aimed at providing recovery, patients with vestibular deficits avoid moving and exercising as much as possible for fear of increasing dizziness complaints (Herdman, Blatt, Schubert, & Tusa, 2000; M. J. Kim, Kim, Joo, Park, & Han, 2012). However, the treatment of the vestibular system is possible with more movement, more repetitions and interventions in the real environment. For example, the symptoms of unilateral vestibular deficit that occur without head movement normally resolve quickly and disappear as vestibular compensation develops. However, permanent loss of vestibular afferent inputs has a long-lasting effect on dynamic reflex functions that occur with head movement. Therefore, with task-oriented training, it is aimed to create a strong synaptic plasticity within the vestibular sensory organs. This synaptic plasticity heals the damaged part of hair cells and vestibular nerve fibers, gradually restoring peripheral sensory inputs (Şahbaz, 2021).

When the literature is examined, it is seen that task-oriented training is widely used to improve balance and gait in neurological patients.

Özkul et al. examined the effects of task-oriented training on cognitive and motor performance in patients with Multiple Sclerosis (MS). The researchers aimed to explore the effects of task-oriented training on walking, balance, manual dexterity, and cognitive performance. While the researchers giving task-oriented training to one group twice a week for 6 weeks, they applied a relaxation program in the form of a home program to the other group. As a result, walking and balance performance improved after task-oriented training, but they could not improve cognitive performance other than manual dexterity and verbal memory. In the control group, they did not find any change in any parameter. Researchers stated that task-oriented training is very effective in improving balance and walking in patients with MS (Ozkul et al., 2020).

In another study, Kim et al. investigated the effects of task-oriented training on balance and walking performance in stroke patients. By dividing the patients into 2 groups, they gave task-oriented training to the 1st group and applied conventional physiotherapy to the 2nd group. As a result, they stated that balance and walking improved after the treatment in both groups, but the task-oriented training group provided more improvement in walking. In conclusion, researchers stated that task-oriented training improves walking performance in subacute stroke patients (K. Kim, Jung, & Lee, 2017).

Söke et al. investigated the effect of task-oriented training combined with aerobic training on balance and motor performance in Parkinson's patients. While they applied aerobic training and task-oriented training to the 1st group 3 times a week for 8 weeks, they applied only aerobic train-

ning to the 2nd group. When groups were compared after treatment, they found that the group that received task-oriented training in addition to aerobic training improved significantly more in all outcomes than the other group. Researchers stated that task-oriented training in addition to aerobic training can improve balance and walking performance, functional mobility, balance confidence, disease severity and quality of life in Parkinson's patients (Soke, Guclu-Gunduz, Kocer, Fidan, & Keskinoglu, 2019).

In summary, task-oriented training is a more effective method in improving balance and walking, reducing dependency on daily living activities and increasing quality of life compared to conventional physiotherapy.

## References

- Arnold, S. A., Stewart, A. M., Moor, H. M., Karl, R. C., & Reneker, J. C. (2017). The effectiveness of vestibular rehabilitation interventions in treating unilateral peripheral vestibular disorders: a systematic review. *Physiotherapy Research International*, 22(3), e1635.
- Bayona, N. A., Bitensky, J., Salter, K., & Teasell, R. (2005). The role of task-specific training in rehabilitation therapies. *Topics in stroke rehabilitation*, 12(3), 58-65.
- Bernhardt, J., Chan, J., Nicola, I., & Collier, J. M. (2007). Little therapy, little physical activity: rehabilitation within the first 14 days of organized stroke unit care. *Journal of rehabilitation medicine*, 39(1), 43-48.
- Blennerhassett, J., & Dite, W. (2004). Additional task-related practice improves mobility and upper limb function early after stroke: a randomised controlled trial. *Australian Journal of Physiotherapy*, 50(4), 219-224.
- Davis, J. Z. (2006). Task selection and enriched environments: a functional upper extremity training program for stroke survivors. *Topics in stroke rehabilitation*, 13(3), 1-11.
- Dobkin, B., & Carmichael, T. (2005). Principles of recovery after stroke. *Recovery after stroke*, 47-66.
- Elbeltagy, R., & Abd El-Hafeez, M. (2018). Efficacy of vestibular rehabilitation on quality of life of patients with unilateral vestibular dysfunction. *Indian Journal of Otolaryngology*, 24(4), 231.
- Fitts, P. M., and Posner, M. I. (1967). Human performance. Harvard, United States, 1-125.
- Gentile, A. M. (1972). A working model of skill acquisition with application to teaching. *Quest*, 17(1), 3-23.
- Hall, C. D., Herdman, S. J., Whitney, S. L., Cass, S. P., Clendaniel, R. A., Fife, T. D., . . . Shepard, N. T. (2016). Vestibular Rehabilitation for Peripheral Vestibular Hypofunction: An Evidence-Based Clinical Practice Guideline: From The American Physical Therapy Association Neurology Section. *Journal of Neurologic Physical Therapy*, 40(2), 124.
- Herdman, S. J., Blatt, P., Schubert, M. C., & Tusa, R. J. (2000). Falls in patients with vestibular deficits. *Otolaryngology & Neurotology*, 21(6), 847-851.
- Hillier, S., & McDonnell, M. (2016). Is vestibular rehabilitation effective in improving dizziness and function after unilateral peripheral vestibular hypofunction? An abridged version of a Cochrane Review. *European Journal of Physical and Rehabilitation Medicine*, 52(4), 541-556.
- Hubbard, I., & Parsons, M. (2007). The conventional care of therapists as acute stroke specialists: a case study. *International Journal of Therapy and Rehabilitation*, 14(8), 357-362.

- Hubbard, I. J., Parsons, M. W., Neilson, C., & Carey, L. M. (2009). Task-specific training: evidence for and translation to clinical practice. *Occupational therapy international*, 16(3-4), 175-189.
- Kelly, C., Foxe, J. J., & Garavan, H. (2006). Patterns of normal human brain plasticity after practice and their implications for neurorehabilitation. *Archives of Physical Medicine and Rehabilitation*, 87(12), 20-29.
- Kim, K., Jung, S. I., & Lee, D. K. (2017). Effects of task-oriented circuit training on balance and gait ability in subacute stroke patients: a randomized controlled trial. *Journal of physical therapy science*, 29(6), 989-992.
- Kim, M. J., Kim, K.-S., Joo, Y. H., Park, S. Y., & Han, G. C. (2012). The dizziness handicap inventory and its relationship with vestibular diseases. *The Journal of International Advanced Otolology*, 8(1), 69-77.
- Lee, H. J., & Choi-Kwon, S. (2009). Quality of life and the related factors in patients with dizziness. *Journal of Korean Academy of Nursing*, 39(5), 751-758.
- Mathiowetz, V., Nilsen, D. M., & Gillen, G. (2015). Task-oriented approach to stroke rehabilitation. *Stroke rehabilitation: A function-based approach*, 1, 59-74.
- McDonnell, M. N., & Hillier, S. L. (2015). Vestibular rehabilitation for unilateral peripheral vestibular dysfunction. *The Cochrane Library*, 1, 1-98.
- Ozkul, C., Guclu-Gunduz, A., Eldemir, K., Apaydin, Y., Gulsen, C., Yazici, G., . . . Irkeç, C. (2020). Effect of task-oriented circuit training on motor and cognitive performance in patients with multiple sclerosis: A single-blinded randomized controlled trial. *NeuroRehabilitation*, 46(3), 343-353.
- Page, S. J. (2003). Intensity versus task-specificity after stroke: how important is intensity? *American journal of physical medicine & rehabilitation*, 82(9), 730-732.
- Poole, J. L. (1991). Application of motor learning principles in occupational therapy. *American Journal of Occupational Therapy*, 45(6), 531-537.
- Richards, L. G., Stewart, K. C., Woodbury, M. L., Senesac, C., & Cauraugh, J. H. (2008). Movement-dependent stroke recovery: a systematic review and meta-analysis of TMS and fMRI evidence. *Neuropsychologia*, 46(1), 3-11.
- Rosiak, O., Szczepanik, M., Woszczak, M., Lucas-Grzelczyk, W., & Józefowicz-Korczyńska, M. (2019). Effectiveness of vestibular rehabilitation in patients with vestibular dysfunction. *Medycyna pracy*, 70(5), 545-553.
- Rossi-Izquierdo, M., Santos-Pérez, S., & Soto-Varela, A. (2011). What is the most effective vestibular rehabilitation technique in patients with unilateral peripheral vestibular disorders? *European Archives of Oto-Rhino-Laryngology*, 268(11), 1569-1574.
- Schmidt, R. A., Lee, T. D., Winstein, C., Wulf, G., & Zelaznik, H. N. (2018). *Motor control and learning: A behavioral emphasis*: Human kinetics, United

States, 1-395

- Schmidt., A. R. (1988). *Motor control and learning: A behavioral emphasis, 2nd ed.* Human kinetics, United States, 283-300.
- Sestak, A., Maslovara, S., Zubcic, Z., & Vceva, A. (2020). Influence of vestibular rehabilitation on the recovery of all vestibular receptor organs in patients with unilateral vestibular hypofunction. *NeuroRehabilitation*, 47(2), 227-235.
- Smółka, W., Smółka, K., Markowski, J., Pilch, J., Piotrowska-Seweryn, A., & Zwierzchowska, A. (2020). The efficacy of vestibular rehabilitation in patients with chronic unilateral vestibular dysfunction. *International journal of occupational medicine and environmental health*, 33(3), 273-282.
- Soke, F., Guclu-Gunduz, A., Kocer, B., Fidan, I., & Keskinoglu, P. (2019). Task-oriented circuit training combined with aerobic training improves motor performance and balance in people with Parkinson' s Disease. *Acta Neurologica Belgica*, 121(2), 535-543.
- Şahbaz, Y. (2021). Vestibüler kompanzasyon. Kara B, editör. Vestibüler Rehabilitasyon, Değerlendirme ve Tedavi Yaklaşımları. 1. Baskı. Ankara. *Türkiye Klinikleri*, 1(1), 34-37.
- Teasell, R., Bayona, N. A., & Bitensky, J. (2005). Plasticity and reorganization of the brain post stroke. *Topics in stroke rehabilitation*, 12(3), 11-26.
- Whitney, S. L., Alghwiri, A. A., & Alghadir, A. (2016). An overview of vestibular rehabilitation. *Handbook of Clinical Neurology*, 137, 187-205.
- Winstein, C., & Stewart, J. C. (2006). Conditions of task practice for individuals with neurologic impairments. *Textbook of Neural Repair and Rehabilitation*, 2, 89-102.
- Yiğider, A. P., & Ayaz, Z. (2018). Tek taraflı periferik vestibüler disfonksiyonda vestibüler rehabilitasyon. *Praxis of Otorhinolaryngology*, 6, 113-119.





## **CHAPTER 8**

### **PREVALENCE OF DIROFILARIASIS AND DIROFILARIA SPP. IN DOGS IN TURKEY**

*Özgür Yaşar ÇELİK<sup>1</sup>, Burçak ASLAN ÇELİK<sup>2</sup>*

---

1 Siirt University, Faculty of Veterinary Medicine, siirt, Turkey. ORCID:0000-0001-6365-2688

2 Siirt University, Faculty of Veterinary Medicine, siirt, Turkey. ORCID: 0000-0002-0130-970X

## Introduction

The companionship between humans and dogs started with the domestication of dogs and has increased until today. In addition to the benefits of this companionship, there are also negative aspects, as there are many diseases transmitted from dogs to humans (Doğanay & Şahal, 1987). Among these diseases, parasitic zoonoses have an important place, and the role of nematodes of the genus *Dirofilaria* is considerable among these parasites. Nematodes of the genus *Dirofilaria* are zoonotic nematodes that are seen almost all over the world and sometimes have a latent course and pose a risk for both humans and dogs (Eroğlu, 2017; Kozan, Sevimli, & Birdane, 2007). More than 40 species of the genus *Dirofilaria* have been identified (Balkaya & Şimşek, 2013; Eroğlu, 2017), and it has been reported that *Dirofilaria immitis* and *Dirofilaria repens* are the most common nematodes in dogs and can also cause disease in humans (Ayvazoğlu, Akyüz, Ögün, Demir, & Kızıltepe, 2022; Doğanay & Şahal, 1987; Genchi, Rinaldi, Mortarino, Genchi, & Cringoli, 2009; Morchón, Carretón, González-Miguel, & Mellado-Hernández, 2012). *Dirofilaria immitis* occurs mostly in tropical, sub-tropical, and temperate regions (Balıkçı & Sevgili, 2005; Sarali, Bilgiç, Bakirci, & Karagenç, 2020), and the incidence of the disease increases in temperate and tropical regions (Sarali et al., 2020; Wang et al., 2016). The intermediate host of the parasite are mosquitoes and its definitive host are dogs, cats, foxes, wolves, other wild carnivores, and humans (Ayvazoğlu et al., 2022; Kozan et al., 2007; Sarali et al., 2020; Taşçı & Kiliç, 2012; Yıldız, 2018). As mosquito-borne zoonotic pathogens, they cause diseases such as heartworms, pulmonary dirofilariasis, and subcutaneous dirofilariasis (Wang et al., 2016). Canine filariasis is becoming increasingly important not only as a disease in dogs but also as a zoonosis (Zeybek, 1989). The most common species in dogs are *D. immitis* and *D. repens* (Kozan et al., 2007). *D. immitis*, *D. repens*, and *Dipetalonema reconditum* are reported to be seen in dogs in Turkey (Cetinkaya, Akyazi, Ozkurt, & Matur, 2016; Sami Simsek & Ciftci, 2016; Toparlak, Gargili, Esatgil, & Cetinkaya, 2005).

## Morphology

*D. immitis* is the longest one of the *Dirofilaria* sp. important for human and veterinary medicine. (Lok, 2018). Morphologically, *D. immitis* is a long, whitish, and thin filiform nematode. Males are 12-16 cm in length and 0.5-1 mm in width. Females are 25-31 cm in length and 1-1.3 mm in width and ovoviviparous (Balkaya & Şimşek, 2013; Doğanay & Bıyıkoğlu, 1992; Lok, 2018; Manfredi, DiCerbo, & Genchi, 2007; Zeybek, 1989). Microfilariae are generally 307-322 microns in length and 6.7-7.1 microns in width (Doğanay & Bıyıkoğlu, 1992). The caudal ends of females are bluntly rounded and the vulvar openings are located just behind the juncti-

on of the esophagus and intestine. The caudal end of males is spirally curved and more conical than that of females. There are 4-6 oval papillae. The spicules are not of equal length in all species of *Dirofilaria*. (Lok, 2018; Manfredi et al., 2007). Females of *D. repens* living in the subcutaneous tissues of dogs and cats are 13-17 cm length and 6-8 microns in diameter. Males are 5-7 cm length, 0.37-0.45 mm width. There are two to six preanal papillae to the right of the anus and four to five to the left. The microfilariae of *D. repens* are unsheathed, 290-360 microns length, 6-8 microns in diameter and are found in subcutaneous lymph spaces and peripheral blood (Doğanay & Bıyıkoğlu, 1992; Doğanay & Şahal, 1987; Lok, 2018).

Adults of *Di.reconditum*, a non-pathogenic filaria of dogs, are usually found in the subcutaneous connective tissues of the final host (Lok, 2018). Adult females are 32 mm in length and 144-157 microns in width. Males are 17 mm in length and 100-106 microns in width (Doğanay & Bıyıkoğlu, 1992; Lok, 2018). The microfilariae are half-moon shaped and wavy along the long axis. The microfilariae are 246-293 microns in length and 4.7-5.8 microns in width (Doğanay & Bıyıkoğlu, 1992).

### Vectors

The intermediate host of the parasite is mosquitoes of the Culicidae family (Genchi et al., 2009). The geographical distribution of dirofilariosis is related to the availability of mosquitoes as intermediate hosts. The mosquito population is affected by environmental factors such as the presence of stable water and favorable temperature (Adanir, Sezer, & Onur, 2013; Kozan et al., 2007). *D.immitis* is vectored by *Aedes* sp., *Culex* sp., *Anopheles* sp., *Armigeres* sp., *Myzorhynchus* sp., and *Taeniorhynchus* species. *D.repens* is vectored by *Aedes* sp. and *Mansonia* spp. *Dipetalonema reconditum* is vectored by *Rhipicephalus* sp., *Pulex* sp., *Ctenocephalides* sp., *Heterodoxus* sp., *Echidnophaga* sp., and *Xenopsylla* species (Ayvazoğlu et al., 2022; Doğanay & Bıyıkoğlu, 1992; Eroğlu, 2017; Hou et al., 2011; Taşçı & Kiliç, 2012). Since the host is a mosquito, the infection can also occur in people who live near rivers or marshes and even in people who have no contact with dogs (Çakıroğlu & Meral, 2007).

### Biology

The development of filarial nematodes is similar. The life cycle of *Dirofilaria* consists of stages that develop both in an intermediate host, which acts as a vector, and in the definitive host vertebrate (Figure 1) (Doğanay & Bıyıkoğlu, 1992; Genchi et al., 2009). Different culicid mosquito species act as intermediate hosts to complete their life cycle (Morchón et al., 2012). The optimum temperature for the transmission of filarial parasites from dogs to flies is 23°C. At temperatures above or below this, the fly's ability to bite decreases (Doğanay & Bıyıkoğlu, 1992; Doğanay & Şahal, 1987).

After mosquitoes suck blood from a microfilaremic host, microfilariae remain in the fly's midgut for an average of 24 hours (Doğanay & Bıyıkoğlu, 1992). Then they migrate to the malpighian tubules and become first-stage larvae. After an average of seven days, they become second-stage larvae (L2), and on the thirteenth day, they become third-stage larvae (L3) (Doğanay & Bıyıkoğlu, 1992; Manfredi et al., 2007; Morchón et al., 2012). The infective L3 migrates from the tubules into the lumen of the labial sheath on the vector mouthparts. When the infected mosquito sucks blood from the definitive host vertebrate, the larvae migrate to the hemolymph in the dog's skin (Doğanay & Bıyıkoğlu, 1992; Manfredi et al., 2007). Larvae initially remain in the bitten area and become fourth-stage larvae (Doğanay & Bıyıkoğlu, 1992). It then enters the bite wound and penetrates the connective tissues, migrating from subcutaneous or subserosal tissues to the muscles (Manfredi et al., 2007). They then settle in the right ventricle via venous circulation. The migration period of microfilariae in the definitive host varies between 70-120 days. Approximately 191 days after infection, the first microfilariae are detected in the blood (Doğanay & Şahal, 1987). Mature male and female *D. immitis* stages are found in the right ventricle and pulmonary arteries, rarely in the vena cava, peritoneal cavity, and camera oculi anterior, while *D. repens* is found mainly in subcutaneous tissues (Doğanay & Şahal, 1987; Eroğlu, 2017; Genchi et al., 2009; Hou et al., 2011; Sarali et al., 2020). *Dirofilaria* microfilariae are found in the peripheral blood of the definitive host (Doğanay & Şahal, 1987; Eroğlu, 2017; Hou et al., 2011). *D. immitis* rarely infects humans, while *D. repens* is the main causative agent of human dirofilariasis (Sarali et al., 2020). Both *Dirofilaria* species are zoonotic and human infections caused by *D. repens* are increasing in Europe (Genchi et al., 2009). Larvae have a life expectancy of 2-3 years (Doğanay & Şahal, 1987).

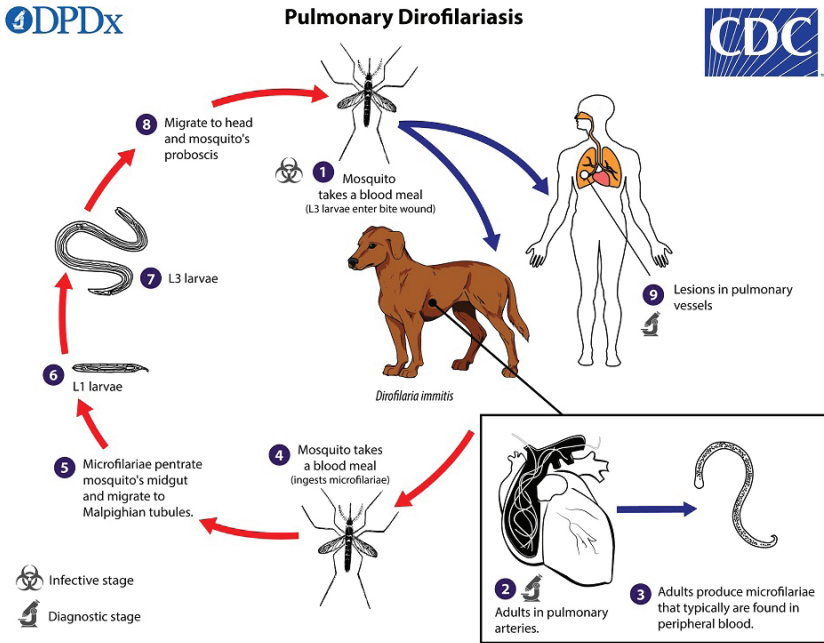


Figure 1. *Dirofilaria immitis* life cycle (CDC, 2019)

## Symptoms

The pathogenicity caused by filarial nematodes, which show an intermediate host development, varies depending on factors such as the type, number, and localization of the parasite and the general condition of the animal (Yıldırım, 2004). *D.immitis* settles in the right ventricle and pulmonary arteries, *D.repens* in the subcutaneous connective tissue, and *Di.reconditum* in the subcutaneous connective tissue and perirenal tissue (Ayvazoğlu et al., 2022; Doğanay & Bıyıkoğlu, 1992; Genchi et al., 2009; Sarali et al., 2020; Yıldırım, 2004). Dogs infected with a few parasites may not show clinical symptoms, but as the disease progresses, symptoms begin to appear (Doğanay & Bıyıkoğlu, 1992). Symptoms include progressive endocarditis, hypertrophy of the heart, dysfunction of the heart valves, congestive heart failure, arrhythmia, pulmonary hypertension, pulmonary edema, difficulty breathing, dry and hoarse cough, congestion in the liver, ascites, cirrhosis and various disorders affecting the kidneys (Adanir et al., 2013; Ayvazoğlu et al., 2022; Doğanay & Bıyıkoğlu, 1992; Doğanay & Şahal, 1987; Eroğlu, 2017; Oge, Doğanay, Oge, & Yıldırım, 2003; Oi et al., 2014; Sarali et al., 2020; Taşçı & Kiliç, 2012; Yıldırım, 2004).

## Diagnosis

Control and treatment of filarial agents in dogs are only possible after the agent has been identified (Yıldırım, 2004). The appearance of clinical signs in areas where filariasis is common in dogs should be suspicious of this disease. This disease should not be ignored, especially in areas with high mosquito populations (Doğanay & Bıyıkoğlu, 1992). Methods such as direct smear, Modified Knott, and Membrane filtration (A. D. Ataş, Altay, Alim, & Özkan, 2018; Balkaya & Şimşek, 2013; Doğanay & Bıyıkoğlu, 1992; Simón et al., 2012), saponin concentration method, micro hematocrit capillary sedimentation method and acid phosphatase histochemical staining technique are used to detect microfilariae in dogs (Balkaya & Şimşek, 2013; Sari, Taşçi, & Kilic, 2013). It is very difficult to make a species-level diagnosis of microfilariae in blood examinations (Yıldırım, 2004). For this, the microfilariae must be specifically identified and stained so that the location of embryological formations in the microfilariae and other morphological features can be determined. (Doğanay & Şahal, 1987). Microfilaria screening in peripheral blood is not a very reliable method (Eroğlu, 2017). ELISA is reported to be the most reliable method among serologic methods in the diagnosis of the disease (Eroğlu, 2017). Recently, a duplex real-time PCR capable of detecting *D. immitis* in dogs and mosquitoes and distinguishing it from *D. repens* and a multiplex PCR for the simultaneous detection of filarioids in dogs have been described (Simón et al., 2012). Thoracic radiographs, Electrocardiography, and Echocardiography are also used in diagnosis (Hoch & Strickland, 2008; Venco, 2007).

## Treatment

Treatment of Dirofilariasis in dogs is complex and often risky due to the side effects of the massive eradication of worms from the bloodstream. It is therefore necessary to choose an appropriate treatment strategy and in some cases, it may be best to stop treatment (Simón et al., 2012). Treatment of dirofilariasis aims to improve the clinical appearance of the dog and to remove all parasitic stages with minimal complications (Doğanay & Bıyıkoğlu, 1992). Exercise restriction during the treatment period is important to minimize cardiopulmonary complications (Yıldız, 2018). Since there is no single drug that works completely on both mature and microfilariae, treatment is based on a drug that kills the mature parasites first and then the microfilariae (Doğanay & Şahal, 1987). Stibofen, filarsen (dichlorfenarsine), diethylcarbamazine, dithiazanine iodide, Na-caparsolate, doramectin, and melarsomine are drugs that can be used to treat this disease (Traş, Yazar, & Elmas, 2007). Thiacetarsamide, previously used for adult parasites, has been reported to cause acute toxicity in dogs (Yıldız, 2018). Levamisole is administered to dogs at a dose of 11mg/kg (Per Os, 6-15 days). It should not be applied for more than fifteen days.

Selamectin 6mg/kg used as a skin drop has close to 100% efficacy against heartworms. Milbemycin D 1mg/kg PO and milbemisin oxime 0.5-1 mg/kg PO are other drugs that can be used (Traş et al., 2007). Melarsomine dihydrochloride acts on adult parasites. It is administered as a deep intramuscular injection into the lumbar muscle of the dog (between L3, and L5). It is recommended to administer the 2nd dose 4-6 weeks after the first dose. (Yıldız, 2018). Ivermectin is highly effective against microfilariae in dogs at a dose of 0.05mg/kg PO. It is not effective on adults of the parasite. For preventive purposes, 0.006-0.012 mg/kg (PO, 1-month interval) can be used (Traş et al., 2007). Following the killing of adults, supportive care is provided to prevent complications such as pulmonary thromboembolism and pneumonia (Aytuğ, 2012).

### **Prophylaxis**

Given the importance of the disease, and the difficulty and risks of treatment in infected dogs, prophylaxis is crucial. The preferred prophylactic treatment in terms of safety and efficacy consists of the administration of macrocyclic lactones such as ivermectin, milbemisin oxime, moxidectin, or selamectin (Simón et al., 2012). All dogs in endemic areas should receive prophylactic treatment throughout the year and especially during seasons when flies are present and active (Aytuğ, 2012).

### **Prevalence of Dirofilariasis Worldwide**

The first reference to the dog filaria was made by Francesco Birago in the 17th century (Simón et al., 2012). *D. immitis* was first described in the world in 1856 by Joseph Leidy in a dog in Alabama (Sari et al., 2013). Dirofilariasis is reported to occur in America, Europe, Africa, Asia, and Australia (Simón et al., 2012).

In studies conducted to determine the prevalence of Dirofilariasis in the world; 24% in China (Hou et al., 2011), 5.4% in the USA (Tzipory, Crawford, & Levy, 2010), 9.9% in Austria (Sonnberger, Fuehrer, Sonnberger, & Leschnik, 2021), 2% in Brazil (Labarthe et al., 2003), 11.4% in Australia (Labarthe et al., 2003), 23% in Japan (Oi et al., 2014), 10.2% in Korea (Byeon et al., 2007), 0.16% in Poland (Krämer et al., 2014), 27.3% in Portugal (Vieira et al., 2014), 8.28% in Mexico (Bolio-Gonzalez et al., 2007), 30.3% in Iran (Anvari, Saadati, Siyadatpanah, & Gholami, 2019), 4.1% in Greece (Diakou, Kapantaidakis, Tamvakis, Giannakis, & Strus, 2016) and 52.18% in Spain (Montoya, Morales, Ferrer, Molina, & Corbera, 1998) prevalence were reported.

### **Prevalence of Dirofilariasis in Turkey**

*Dirofilaria immitis* infections are common in tropical and subtropical regions (A. D. Ataş et al., 2018). It has been reported that Turkey has inter-

mediate hosts and suitable climatic conditions for the development of this parasite (A. D. Ataş et al., 2018; Yıldız, Duru, Yağcı, Öcal, & Gazyağcı, 2008) and that Turkey is an endemic region for Dirofilariasis (Yaman, Guzel, Koltas, Demirkazık, & Aktas, 2009).

Dirofilariasis was first detected in Turkey in 1951 and then in 1959 in dogs of foreign origin. (Doğanay & Şahal, 1987; Zeybek, 1989). Currently, studies investigating the prevalence of Dirofilariasis have been carried out in many provinces of Turkey (Table 1). The number of studies conducted according to years is presented in Figure 2, the number of studies conducted according to cities is presented in Figure 3 and the map of the provinces where the studies were conducted is presented in Figure 4.

In studies conducted to determine the prevalence of Dirofilariasis in Turkey; 3.65%-17.65% in Afyonkarahisar (Kozan et al., 2007; Köse & Erdoğan, 2012), 12% in Aksaray (Köse & Erdoğan, 2012), 0%-14.81% in Ankara (Doğanay, 1983; Köse & Erdoğan, 2012; Oge et al., 2003; S Simsek, Utuk, Koroglu, & Rishniw, 2008; Yıldırım, 2004; Zeybek, 1989), 12% in Ardahan (Ayvazoğlu et al., 2022), 2.52%-17.80% in Aydın (Sarali et al., 2020; Ural, Gultekin, Atasoy, & Ulutas, 2014; Voyvoda, Paşa, Töz, Özbel, & Ertabaklar, 2004), 21.83% in Burdur (Adanir et al., 2013), 0.20%-2.98% in Bursa (Civelek, Yıldırım, & İça, 2006; Coşkun, Tınar, Akyol, Aydın, & Demir, 1992; Tınar et al., 1989; Yalçın, Şenlik, Yılmaz, Alasonyalılar, & Akyol, 2007), 0.63% in Denizli (Ural et al., 2014), 2.44% in Diyarbakır (İçen et al., 2011), 14.71% in Edirne (Cetinkaya et al., 2016), 0%-9.17% in Elazığ (Balıkçı & Sevgili, 2005; Sami Simsek & Ciftci, 2016; S Simsek et al., 2008; Taşan, 1984), 12% in Erzincan (Kose, 2005), 1.50%-8.13% in Erzurum (Demir & Aktaş, 2020; Guven, Avcioglu, Cengiz, & Hayirli, 2017; Sami Simsek, Ozkanlar, Balkaya, & Aktas, 2011), 1.37%-30% in Eskişehir (Kozan et al., 2007; Köse & Erdoğan, 2012; Sarnıç & Alkan, 1986), 26.02% in Hatay (Yaman et al., 2009), 40%-50.83% in Iğdır (Sari et al., 2013; Taşçı & Kiliç, 2012), 0%-1.52% in Istanbul (Cetinkaya et al., 2016; Fırat, Gülçubuk, & Çetinkaya, 2005; Öncel & Vural, 2005; Toparlak et al., 2005), 0%-2.50% in Izmir (Ertekin, 2017; Öncel & Vural, 2005; Sarali et al., 2020; Ural et al., 2014; Voyvoda et al., 2004), 9.52%-14.29% in Kars (Köse & Erdoğan, 2012; Taşçı & Kiliç, 2012; Umur & Arslan, 1998), 9.64%-16% in Kayseri (İ. Şahin, Ekinçi, Şen, Özcan, & Gödekmerdan, 1993; Yildirim, Ica, Atalay, Duzlu, & Inci, 2007), 5.81% in Kırıkkale (Yıldız et al., 2008), 11% in Kırklareli (Cetinkaya et al., 2016), 18.31% in Kocaeli (S Simsek et al., 2008), 1.96%-5% in Konya (Aydenizöz, 1997; Cantoray, Dik, & Gülbahçe, 1990; Köse & Erdoğan, 2012), 8.70% in Malatya (Köse & Erdoğan, 2012), 2.70%-10.53% in Mersin (Köse & Erdoğan, 2012; S Simsek et al., 2008), 2.17%-14.29% in Nevşehir (Köse & Erdoğan, 2012; Yabaneri et al., 2017), 4% in Niğde (Köse & Erdoğan, 2012), 1%



in Osmaniye (Gökmen et al., 2019), 12.31% in Sakarya (S Simsek et al., 2008), 2.94%-6% in Sivas (A. Ataş, Özçelik, & Saygı, 1997; A. D. Ataş et al., 2018), 7.61% in Şanlıurfa (T. Şahin, Sevgili, & Çamkerten, 2004), 1% in Tekirdağ (Cetinkaya et al., 2016), and 17.82%-46.23% in Van (Ağaoğlu, Akgül, Ceylan, & Akkan, 2000; Göz et al., 2007) prevalence were reported.

In addition, it was reported that no positivity was found in studies conducted in Antalya, (Küçükler & Şahinduran, 2018), Samsun (Çakıroğlu & Meral, 2007), and Siirt (Aslan-Çelik et al., 2020).

Table 1. Studies on *Dirofilariasis* in Turkey

Province	Examined	Positive		Method	Species detected	References
	n	n	%			
Afyonkarahisar	137	5	3.65%	Thick drop and modified Knott's technique	<i>Dirofilaria</i> sp.	(Kozan et al., 2007)
Afyonkarahisar	34	6	17.65%	ELISA	<i>D. immitis</i>	(Köse & Erdoğan, 2012)
Aksaray	25	3	12.00%	ELISA	<i>D. immitis</i>	(Köse & Erdoğan, 2012)
Ankara	50	1	2.00%	Modified Knott, May-Grünwald-Giemsa	<i>D. repens</i>	(Doğanay, 1983)
Ankara	280	26	9.29%	PetChek antigen ELISA and polycarbonate filter-acid phosphatase histochemical staining	<i>D. immitis</i>	(Oge et al., 2003)
Ankara	300	19	6.33%	Native, Modified Knott, Membrane filtration, acid phosphatase staining	<i>D. immitis</i>	(Yıldırım, 2004)
Ankara	33	4	12.12%	Giemsa	<i>D. immitis</i>	(Zeybek, 1989)
Ankara	19	0	0.00%	ELISA	<i>D. immitis</i>	(Köse & Erdoğan, 2012)
Ankara	27	4	14.81%	ELISA	<i>D. immitis</i>	(S Simsek et al., 2008)
Antalya	225	0	0.00%	Rapid test	<i>D. immitis</i>	(Küçükler & Şahinduran, 2018)
Ardahan	100	12	12.00%	Immunochromatographic analysis test	<i>D. immitis</i>	(Ayvazoğlu et al., 2022)
Aydın	118	21	17.80%	Modified Knott	<i>D. immitis</i>	(Voyvoda et al., 2004)

Aydın		4	2.52%	Snap 4Dx test	<i>D. immitis</i>	(Ural et al., 2014)
Aydın	122	15	12.30%	Wet smear:%3.28, Modified Knott:%5.74, Membran filtration: %4.92, PCR: %12.30, Serologic kit: %12.30	<i>D. immitis</i>	(Sarali et al., 2020)
Burdur	142	31	21.83%	Modified Knott, ELISA	<i>D. immitis</i>	(Adanir et al., 2013)
Bursa	100	2	2.00%	Modified Knott, ELISA	<i>D. immitis</i>	(Civelek et al., 2006)
Bursa	1000	2	0.20%	Modified Knott	<i>D. immitis</i>	(Yalçın et al., 2007)
Bursa	100	2	2.00%		<i>D. immitis</i>	(Tınar et al., 1989)
Bursa	168	5	2.98%	Blood examination	<i>D. immitis</i>	(Coşkun et al., 1992)
Denizli		1	0.63%	Snap 4Dx test	<i>D. immitis</i>	(Ural et al., 2014)
Diyarbakır	82	2	2.44%	Snap 4Dx test	<i>D. immitis</i>	(İçen et al., 2011)
Edirne	102	15	14.71%	Rapid test: %17.71, PCR: %4.9, Microscopy: %0	<i>D. immitis</i>	(Cetinkaya et al., 2016)
Elâzığ	120	11	9.17%	Nativ ve ELISA	<i>D. immitis</i>	(Balıkçı & Sevgili, 2005)
Elâzığ	161	6	3.73%	ELISA	<i>D.immitis</i> , <i>D.repens</i>	(Sami Simsek & Ciftci, 2016)
Elâzığ	120	6	5.00%	Blood examination, post-mortem examination	<i>D. immitis</i>	(Taşan, 1984)
Elâzığ	29	0	0.00%	ELISA	<i>D. immitis</i>	(S Simsek et al., 2008)
Erzincan	100	12	12.00%	Native, Modified Knott, Serologic	<i>D. immitis</i>	(Kose, 2005)
Erzurum	250	11	4.40%	Immunochromatographic analysis test	<i>D. immitis</i>	(Demir & Aktaş, 2020)
Erzurum	133	2	1.50%	Conventional and nested PCR	<i>D. immitis</i>	(Güven et al., 2017)
Erzurum	123	10	8.13%	PCR:%8.13, Direct Blood Smear:%4.8, ELISA:2.1	<i>D. immitis</i>	(Sami Simsek et al., 2011)
Eskişehir	146	2	1.37%	Thick drop and modified Knott's technique	<i>Dirofilaria</i> sp.	(Kozan et al., 2007)
Eskişehir	20	6	30.00%	Thick drop, Giemsa, Heamatoksin Eosin	<i>D. immitis</i>	(Sarıncı & Alkan, 1986)
Eskişehir	33	5	15.15%	ELISA	<i>D. immitis</i>	(Köse & Erdoğan, 2012)
Hatay	269	70	26.02%	Modified Knott, ELISA	<i>D. immitis</i>	(Yaman et al., 2009)

İğdir	100	40	40.00%	Snap 3dx kit	<i>D. immitis</i>	(Sari et al., 2013)
İğdir	120	61	50.83%	MF-Acid fosfatase %34.17, ELISA:%50.83, PCR: %39.17	<i>D. immitis</i>	(Taşçı & Kiliç, 2012)
İstanbul				D. Immitis cases in 3 dogs	<i>D. immitis</i>	(Fırat et al., 2005)
İstanbul	263	4	1.52%	ELISA	<i>D. immitis</i>	(Öncel & Vural, 2005)
İstanbul	100	0	0.00%	Rapid test: %0, PCR: %0, Microscopy: %0	<i>D. immitis</i>	(Cetinkaya et al., 2016)
İstanbul	286	2	0.70%	Knott technique	<i>Dipetalonema reconditum</i>	(Toparlak et al., 2005)
İzmir	40	1	2.50%	Modified Knott	<i>D. immitis</i>	(Voyvoda et al., 2004)
İzmir		2	1.26%	Snap 4Dx test	<i>D. immitis</i>	(Ural et al., 2014)
İzmir	117	0	0.00%	ELISA	<i>D. immitis</i>	(Öncel & Vural, 2005)
İzmir	100	1	1.00%	Native, Modifiye Knott, Serology	<i>D. immitis</i>	(Ertekin, 2017)
İzmir	28	0	0.00%	Wet smear, Modified Knott, Membran filtration, PCR, Serologic	<i>D. immitis</i>	(Sarali et al., 2020)
Kars	120	13	10.83%	MF-Acid fosfatase %9.17, ELISA:%9.17, PCR: %10.83	<i>D. immitis</i>	(Taşçı & Kiliç, 2012)
Kars	42	6	14.29%		<i>D. immitis</i>	(Umur & Arslan, 1998)
Kars	42	4	9.52%	ELISA	<i>D. immitis</i>	(Köse & Erdoğan, 2012)
Kayseri	280	27	9.64%	Membrane filtration-acid phosphatase histochemical staining and antigen ELISA techniques	<i>D. immitis</i>	(Yildirim et al., 2007)
Kayseri	50	8	16.00%	Post mortem examination	<i>D. immitis</i>	(İ. Şahin et al., 1993)
Kırıkkale	172	10	5.81%	Modified Knott, acid fosfatase	<i>D. immitis</i>	(Yıldız et al., 2008)
Kırklareli	100	11	11.00%	Rapid test: %11, PCR: %6, Microscopy: %3	<i>D. immitis</i>	(Cetinkaya et al., 2016)
Kocaeli	71	13	18.31%	ELISA	<i>D. immitis</i>	(S Simsek et al., 2008)
Konya				D. Immitis cases in 4 dogs	<i>D. immitis</i>	(Cantoray et al., 1990)
Konya	51	1	1.96%	ELISA	<i>D. immitis</i>	(Köse & Erdoğan, 2012)

Konya	60	3	5.00%	Post mortem examination	<i>D. immitis</i>	(Aydenizöz, 1997)
Malatya	23	2	8.70%	ELISA	<i>D. immitis</i>	(Köse & Erdoğan, 2012)
Mersin	37	1	2.70%	ELISA	<i>D. immitis</i>	(Köse & Erdoğan, 2012)
Mersin	19	2	10.53%	ELISA	<i>D. immitis</i>	(S Simsek et al., 2008)
Nevşehir	138	3	2.17%	Nativ, modified Knott ve membrane filtration, acid phosphatase histochemical staining	<i>D. immitis</i>	(Yabaneri et al., 2017)
Nevşehir	28	4	14.29%	ELISA	<i>D. immitis</i>	(Köse & Erdoğan, 2012)
Niğde	25	1	4.00%	ELISA	<i>D. immitis</i>	(Köse & Erdoğan, 2012)
Osmaniye	100	1	1.00%	SNAP 4Dx PLUS testi	<i>D. immitis</i>	(Gökmen et al., 2019)
Sakarya	65	8	12.31%	ELISA	<i>D. immitis</i>	(S Simsek et al., 2008)
Samsun	100	0	0.00%	ELISA	<i>D. immitis</i>	(Çakıroğlu & Meral, 2007)
Siirt	50	0	0.00%	Rapid test	<i>D. immitis</i>	(Aslan-Çelik et al., 2020)
Sivas	306	9	2.94%	PCR and ELISA: %2.94, modified Knott: %1.3	<i>D. immitis</i>	(A. D. Ataş et al., 2018)
Sivas	50	3	6.00%	Necropsy, thin smear and thick drop, May-Grünwald-Giemsa	<i>D. immitis</i>	(A. Ataş et al., 1997)
Şanlıurfa	92	7	7.61%	Thick drop and modified Knott's technique	<i>Dirofilaria</i> sp.	(T. Şahin et al., 2004)
Tekirdağ	100	1	1.00%	Rapid test: %1, PCR: %0, Microscopy: %0	<i>D. immitis</i>	(Cetinkaya et al., 2016)
Van	101	18	17.82%	ELISA	<i>D. immitis</i>	(Göz et al., 2007)
Van	106	49	46.23%	Modified Knott, ELISA	<i>D. immitis</i>	(Ağaoğlu et al., 2000)

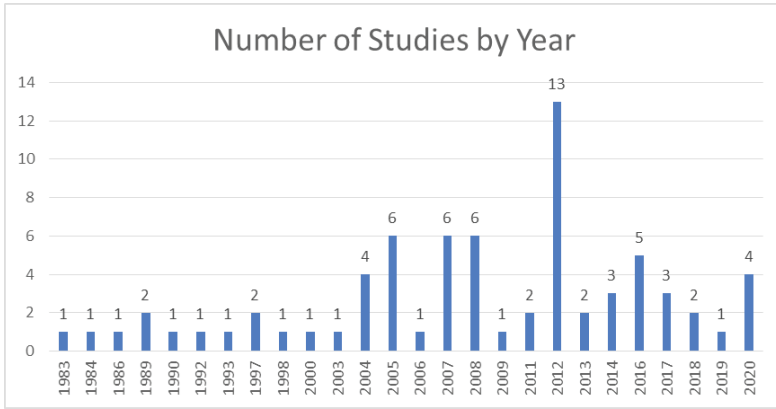


Figure 2. Number of studies conducted in Turkey by years

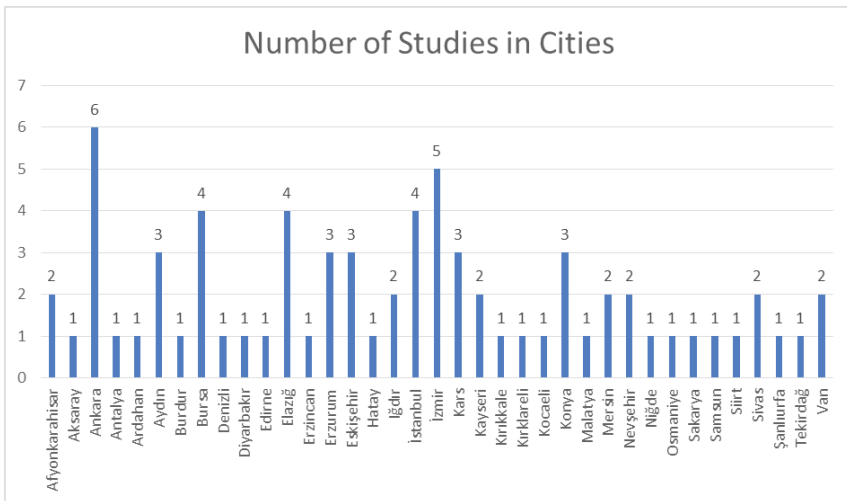


Figure 3. Number of studies conducted in Turkey by province

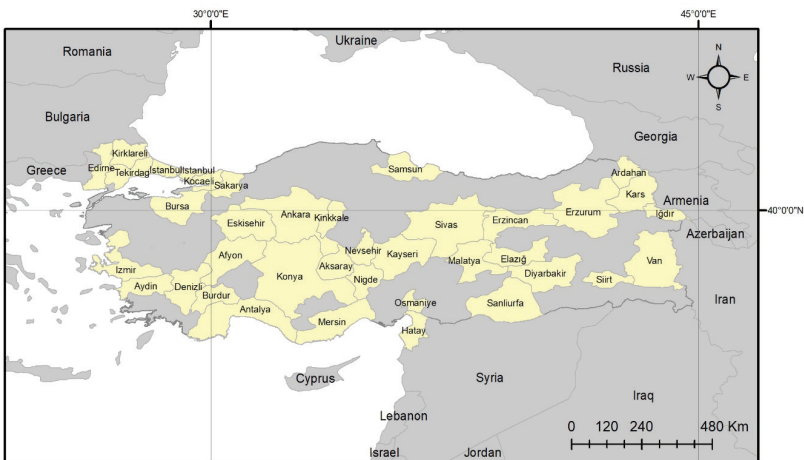


Figure 4. Provinces where the studies were conducted.

## Conclusion and Suggestions

Dogs are important companions in many households around the world, contributing to the physical, social, and emotional development of children and the well-being of their owners. However, they are also often hosted by intestinal parasites that can cause infections in humans. Among these parasites, *Dirofilaria* spp. has been reported to be positive at different rates in studies conducted on dogs in various provinces of Turkey. Canine filariasis is becoming increasingly important in the world not only because it causes disease in dogs but also because it is a zoonosis. These animals roaming the streets are a constant source of infection for their environment due to the zoonotic helminth species they carry. When unhealthy environmental conditions and the lack of adequate knowledge of public are added to this, public health is seriously endangered. In addition to these, the fact that *Culex*, *Aedes*, and *Anopheles* mosquitoes, which are active in the biology of the parasite, are widespread in every region of our country plays an important role in the increase in the spread of this disease. As a result, it is recommended to raise public awareness, treat sick dogs, apply chemoprophylactic drugs every year, especially to dogs living outdoors, and fight against vector mosquitoes to prevent the increase in canine heartworm infections.

## References

- Adanir, R., Sezer, K., & Onur, K. (2013). The prevalence of *Dirofilaria immitis* in dogs with different breed, ages and sex. *AÜ Vet Fak Derg*, 60(4), 241-244.
- Ağaoğlu, Z., Akgül, Y., Ceylan, E., & Akkan, H. (2000). Van yöresi köpeklerinde *Dirofilaria immitis*' in yaygınlığı. *Yüzüncü Yıl Üniversitesi Veteriner Fakültesi Dergisi*, 11(2), 41-43.
- Anvari, D., Saadati, D., Siyadatpanah, A., & Gholami, S. (2019). Prevalence of dirofilariasis in shepherd and stray dogs in Iranshahr, southeast of Iran. *Journal of Parasitic Diseases*, 43(2), 319-323.
- Aslan-Çelik, B., Çelik, Ö. Y., Şahin, T., İrak, K., Bolacali, M., Biçici, Ö., & Bal-daz, V. (2020). A Serologic Survey of *Dirofilariasis*, *Leishmaniasis*, *Ehrlichiosis*, and *Anaplasmosis* in Dogs in Siirt Province. *F.U. Vet. J. Health Sci*, 34(2), 103-108.
- Ataş, A., Özçelik, S., & Saygı, G. (1997). Sivas sokak köpeklerinde görülen helmint türleri bunların yayılışı ve halk sağlığı yönünden önemi. *Türkiye Parazitoloji Dergisi*, 21(3), 305-309.
- Ataş, A. D., Altay, K., Alim, A., & Özkan, E. (2018). Survey of *Dirofilaria immitis* in dogs from Sivas Province in the Central Anatolia Region of Turkey. *Turkish Journal of Veterinary & Animal Sciences*, 42(2), 130-134.
- Aydenizöz, M. (1997). Konya yöresi köpeklerinde helmintolojik araştırmalar. *T Parazitol Derg*, 21, 429-434.
- Aytuğ, N. (2012). *Köpek ve Kedilerin İç Hastalıkları Klinik El Kitabı*. Malatya: Medipress Matbaacılık Yayıncılık Ltd. Şti.
- Ayvazoğlu, C., Akyüz, E., Ögün, M., Demir, P. A., & Kızıltepe, Ş. (2022). Investigation of the Prevalence of *Dirofilaria immitis* in Dogs in Ardahan Region. *International Journal of Veterinary and Animal Research (IJVAR)*, 5(2), 50-53.
- Balıkçı, E., & Sevgili, M. (2005). Elazığ ve Çevresindeki Köpeklerde *Dirofilaria immitis*'in Seroprevalansı. *F.Ü. Sağlık Bil. Dergisi*, 19(2), 103-106.
- Balkaya, İ., & Şimşek, S. (2013). *Dirofilariasis*. In M. Özcel (Ed.), *Veteriner Hekimliğinde Parazit Hastalıkları Cilt 2* (pp. 1128-1136). İzmir: Türkiye Parazitoloji Derneği Yayını.
- Bolio-Gonzalez, M., Rodriguez-Vivas, R., Sauri-Arceo, C., Gutierrez-Blanco, E., Ortega-Pacheco, A., & Colin-Flores, R. (2007). Prevalence of the *Dirofilaria immitis* infection in dogs from Merida, Yucatan, Mexico. *Veterinary parasitology*, 148(2), 166-169.
- Byeon, K. H., Kim, B. J., Kim, S.-M., Yu, H. S., Jeong, H. J., & Ock, M.-S. (2007). A serological survey of *Dirofilaria immitis* infection in pet dogs of Busan, Korea, and effects of chemoprophylaxis. *The Korean Journal of Parasitology*, 45(1), 27-32.

- Cantoray, R., Dik, B., & Gülbahçe, S. (1990). Konya'da dört köpekte saptanan *Dirofilaria immitis* (Leidy, 1856) olgusu. *Veterinarium*, 1(2), 28-32.
- CDC. (2019). *Dirofilariasis-Biology*. Retrieved from <https://www.cdc.gov/parasites/dirofilariasis/biology.html> [18.11.2022].
- Cetinkaya, H., Akyazi, I., Ozkurt, M., & Matur, E. (2016). The serologic and molecular prevalence of heartworm disease in shelter dogs in the Thrace Region of Turkey. *Kafkas Univ Vet Fak Derg*, 22(5), 751-755.
- Civelek, T., Yıldırım, A., & İça, A. (2006). Bursa İli Gemlik yöresi köpeklerde kalp kurdu hastalığının prevalansı. *Vet Bil Derg*, 22(1-2), 65-68.
- Coşkun, Ş., Tınar, R., Akyol, C., Aydın, L., & Demir, S. (1992). Doğal enfekte köpeklerde *Dirofilaria immitis* mikrofiliferlerine ivermektinin etkisi. *Uludağ Univ Vet Fak Derg*, 11, 121-128.
- Çakıroğlu, D., & Meral, Y. (2007). Samsun bölgesinde köpeklerde *Dirofilaria immitis* enfestasyonu insidansı incelenmesi. *JIVS*, 2, 1-12.
- Demir, A., & Aktaş, M. S. (2020). Erzurum Yöresindeki Köpeklerde *Dirofilaria immitis*, *Ehrlichia canis*, *Borrelia burgdorferi* ve *Anaplasma spp* Sero-prevalansının Araştırılması. *Fırat Üniversitesi Sağlık Bilimleri Veteriner Dergisi*, 34(2), 91-96.
- Diakou, A., Kapantaidakis, E., Tamvakis, A., Giannakis, V., & Strus, N. (2016). *Dirofilaria* infections in dogs in different areas of Greece. *Parasites & vectors*, 9(1), 1-7.
- Doğanay, A. (1983). Prevalence of helminths in Ankara dogs and their potential public health significance *AÜ Vet Fak Derg*, 30(4), 550-561.
- Doğanay, A., & Bıyıkoğlu, G. (1992). Köpeklerde görülen Filarial nematodlar. *Etilik Veteriner Mikrobiyoloji Dergisi*, 7(3), 127-140.
- Doğanay, A., & Şahal, M. (1987). Türkiye'deki Köpeklerdeki *Dirofilariasis* Sorunu ve İnsan Sağlığı Açısından Önemi. *Ankara Üniversitesi Veteriner Fakültesi Dergisi*, 34(02), 277-287.
- Eroğlu, F. (2017). The *Dirofilaria* Species Caused of Disease in Human and *Dirofilariasis*. *Sağlık Akademisi Kastamonu*, 2(3), 232-241.
- Ertekin, B. (2017). *İzmir hayvan barınaklarındaki köpeklerde dirofilaria immitis* in prevalansı. (MSc). Van Yüzüncü Yıl University, Van.
- Fırat, İ., Gülçubuk, A., & Çetinkaya, H. (2005). İstanbul'da üç köpekte *Dirofilaria immitis* olgusu. *İstanbul Üniv Vet Fak derg*, 31(1), 185-193.
- Genchi, C., Rinaldi, L., Mortarino, M., Genchi, M., & Cringoli, G. (2009). Climate and *Dirofilaria* infection in Europe. *Veterinary parasitology*, 163(4), 286-292.
- Gökmen, T. G., Günaydin, E., Turut, N., Bünyamin, A., Özgür, K., & Ütük, A. E. (2019). A serosurvey on some canine vector-borne zoonoses (*Anaplasma spp.*, *Ehrlichia spp.*, *Borrelia burgdorferi*, *Dirofilaria immitis* and Leish-



- mania spp.) in Osmaniye. *Atatürk Üniversitesi Veteriner Bilimleri Dergisi*, 14(2), 151-158.
- Göz, Y., Koltas, İ. S., Altug, N., Demirkazık, M., Yüksek, N., & Agaoglu, Z. (2007). Van Yöresi Köpeklerinde *Dirofilaria immitis*' in Seroprevalansı. *YYÜ VET FAK DERG*, 18(2), 5-8.
- Güven, E., Avcioglu, H., Cengiz, S., & Hayırlı, A. (2017). Vector-borne pathogens in stray dogs in Northeastern Turkey. *Vector-Borne and Zoonotic Diseases*, 17(8), 610-617.
- Hoch, H., & Strickland, K. (2008). Canine and feline dirofilariasis: life cycle, pathophysiology, and diagnosis. *Compendium*, 30(3), 133-140.
- Hou, H., Shen, G., Wu, W., Gong, P., Liu, Q., You, J., . . . Zhang, X. (2011). Prevalence of *Dirofilaria immitis* infection in dogs from Dandong, China. *Veterinary parasitology*, 183(1-2), 189-193.
- İçen, H., Sekin, S., Simsek, A., Kochan, A., Celik, O., & Altas, M. (2011). Prevalence of *Dirofilaria immitis*, *Ehrlichia canis*, *Borrelia burgdorferi* infection in dogs from Diyarbakir in Turkey. *Asian Journal of Animal and Veterinary Advances*, 6(4), 371-378.
- Köse, K. (2005). *Studies on the prevalence of the dirofilaria immitis in dog living in the region of Erzincan*. (MSc). Yuzuncu Yil University, Van.
- Kozan, E., Sevimli, F. K., & Birdane, F. M. (2007). Afyonkarahisar ve Eskişehir İl'lerindeki sokak köpeklerinde *Dirofilaria sp.*'nin yayılışı. *AÜ Vet Fak Derg*, 54(2), 145-150.
- Köse, M., & Erdoğan, M. (2012). Serological screening of canine heartworm (*Dirofilaria immitis*) infections in Turkey. *Berliner und Münchener Tierärztliche Wochenschrift* 125(11-12), 503-508.
- Krämer, F., Schaper, R., Schunack, B., Połozowski, A., Piekarska, J., Szwedko, A., . . . Pantchev, N. (2014). Serological detection of *Anaplasma phagocytophilum*, *Borrelia burgdorferi sensu lato* and *Ehrlichia canis* antibodies and *Dirofilaria immitis* antigen in a countrywide survey in dogs in Poland. *Parasitology research*, 113(9), 3229-3239.
- Küçükler, S., & Şahinduran, Ş. (2018). Antalya İlinde bulunan köpeklerde *Dirofilaria immitis*, *Borrelia burgdorferi*, *Ehrlichia canis* ve *Anaplasma phagocytophilum*' in hızlı test kitleri ile teşhisi ve insidansı üzerine araştırmalar. *Atatürk Üniversitesi Veteriner Bilimleri Dergisi*, 13(2), 191-200.
- Labarthe, N., de Campos Pereira, M., Barbarini, O., McKee, W., Coimbra, C. A., & Hoskins, J. (2003). Serologic prevalence of *Dirofilaria immitis*, *Ehrlichia canis*, and *Borrelia burgdorferi* infections in Brazil. *Veterinary therapeutics: research in applied veterinary medicine*, 4(1), 67-75.
- Lok, J. (2018). *Dirofilaria sp.*: Taxonomy and Distribution. In P. Boreham & r. Atwell (Eds.), *Dirofilariasis* (pp. 1-24). Boca Raton London New York: CRC Press, Taylor & Francis Group.

- Manfredi, M. T., DiCerbo, A., & Genchi, M. (2007). Biology of filarial worms parasitizing dogs and cats. In G. Cringoli (Ed.), *Mappe parassitologiche* (Vol. 8, pp. 39-47). Italy: University of Naples Federico.
- Montoya, J., Morales, M., Ferrer, O., Molina, J., & Corbera, J. (1998). The prevalence of *Dirofilaria immitis* in gran canaria, Canary Islands, Spain (1994–1996). *Veterinary parasitology*, 75(2-3), 221-226.
- Morchón, R., Carretón, E., González-Miguel, J., & Mellado-Hernández, I. (2012). Heartworm disease (*Dirofilaria immitis*) and their vectors in Europe—new distribution trends. *Frontiers in physiology*, 3, 196.
- Oge, H., Doğanay, A., Oge, S., & Yildirim, A. (2003). Prevalence and distribution of *Dirofilaria immitis* in domestic dogs from Ankara and vicinity in Turkey. *Deutsche Tierärztliche Wochenschrift*, 110(2), 69-72.
- Oi, M., Yoshikawa, S., Ichikawa, Y., Nakagaki, K., Matsumoto, J., & Nogami, S. (2014). Prevalence of *Dirofilaria immitis* among shelter dogs in Tokyo, Japan, after a decade: comparison of 1999–2001 and 2009–2011. *Parasite*, 21, 10.
- Öncel, T., & Vural, G. (2005). Seroprevalence of *Dirofilaria immitis* in stray dogs in Istanbul and Izmir. *Turkish Journal of Veterinary & Animal Sciences*, 29(3), 785-789.
- Sarali, H., Bilgiç, H. B., Bakirci, S., & Karagenç, T. (2020). Prevalence of *Dirofilaria immitis* infection in dogs from Aydin and Izmir Provinces, Turkey. *Animal Health Prod and Hyg*, 9(2), 711-715.
- Sari, B., Taşçi, G. T., & Kilic, Y. (2013). Seroprevalence of *Dirofilaria immitis*, *Ehrlichia canis* and *Borrelia burgdorferi* in dogs in Iğdır province, Turkey. *Kafkas Univ Vet Fak Derg*, 49(5), 735-739.
- Sarnıç, H., & Alkan, M. (1986). Köpeklerde *Dirofilaria immitis* olguları ve insan sağlığı yönünden önemi. *Türkiye Parazitol Derg*, 11, 169-174.
- Simón, F., Siles-Lucas, M., Morchón, R., González-Miguel, J., Mellado, I., Carretón, E., & Montoya-Alonso, J. A. (2012). Human and animal dirofilariasis: the emergence of a zoonotic mosaic. *Clinical microbiology reviews*, 25(3), 507-544.
- Simsek, S., & Ciftci, A. T. (2016). Serological and molecular detection of *Dirofilaria* species in stray dogs and investigation of *Wolbachia* DNA by PCR in Turkey. *Journal of arthropod-borne diseases*, 10(4), 445.
- Simsek, S., Ozkanlar, Y., Balkaya, I., & Aktas, M. S. (2011). Microscopic, serologic and molecular surveys on *Dirofilaria immitis* in stray dogs, Turkey. *Veterinary parasitology*, 183(1-2), 109-113.
- Simsek, S., Utuk, A., Koroglu, E., & Rishniw, M. (2008). Serological and molecular studies on *Dirofilaria immitis* in dogs from Turkey. *Journal of Helminthology*, 82(2), 181-186.
- Sonnberger, K., Fuehrer, H.-P., Sonnberger, B. W., & Leschnik, M. (2021). The

- incidence of *Dirofilaria immitis* in shelter dogs and mosquitoes in Austria. *Pathogens*, 10(5), 550.
- Şahin, İ., Ekinci, N., Şen, İ., Özcan, M., & Gödekmerdan, A. (1993). Kayseri yöresi köpeklerinde *Echinococcus granulosus* (Batsch, 1786) ve diğer parazitlerin yayılışı. *T Parazitol Derg*, 17, 69-76.
- Şahin, T., Sevgili, M., & Çamkerten, İ. (2004). Şanlıurfa yöresi köpeklerinde *Dirofilaria sp*'nin yayılışı. *Türkiye Parazitol Derg*, 28(3), 140-142.
- Taşan, E. (1984). Elazığ kırsal yöre köpeklerinde helmintlerin yayılışı ve insan sağlığı yönünden önemi. *Doğa Bilim Dergisi*, 8, 160-167.
- Taşçı, G. T., & Kiliç, Y. (2012). Kars ve Iğdır Civarındaki Köpeklerde *Dirofilaria immitis* (Leidy, 1856)'nin Prevalansı ve Potansiyel Vektör Sivrisinek Türleri Üzerine Araştırmalar. *Kafkas Univ Vet Fak Derg*, 18(Suppl-A), 29-34.
- Tınar, R., Coşkun, Ş., Doğan, H., Demir, S., Akyol, Ç., & Aydın, L. (1989). Bursa yöresi köpeklerinde görülen helmint türleri ve bunların yayılışı. *T Parazitol Derg*, 13(3-4), 113-120.
- Toparlak, M., Gargili, A., Esatgil, M. U., & Cetinkaya, H. (2005). Canine filariosis around Istanbul, Turkey employing the naphtol AS-TR phosphatase technique. *Acta Veterinaria Brno*, 74(2), 233-236.
- Traş, B., Yazar, E., & Elmas, M. (2007). *Veteriner Hekimliğinde İlaç Kullanımına Pratik ve Akılcı Yaklaşım* (Vol. 2). Konya: Olgun Çelik Ofset Matbaa.
- Tzipory, N., Crawford, P. C., & Levy, J. K. (2010). Prevalence of *Dirofilaria immitis*, *Ehrlichia canis*, and *Borrelia burgdorferi* in pet dogs, racing greyhounds, and shelter dogs in Florida. *Veterinary parasitology*, 171(1-2), 136-139.
- Umur, Ş., & Arslan, M. (1998). Kars yöresi sokak köpeklerinde görülen helmint türlerinin yayılışı. *Türkiye Parazitol Derg*, 22(2), 188-193.
- Ural, K., Gultekin, M., Atasoy, A., & Ulutas, B. (2014). Spatial distribution of vector borne disease agents in dogs in Aegean region, Turkey. *Revista MVZ Córdoba*, 19(2), 4086-4098.
- Venco, L. (2007). Heartworm (*Dirofilaria immitis*) disease in dogs. In G. Cringoli (Ed.), *Mappe parassitologiche* (pp. 118-125). Italy: University of Naples Federico II.
- Vieira, A. L., Vieira, M. J., Oliveira, J. M., Simoes, A. R., Diez-Banos, P., & Gestal, J. (2014). Prevalence of canine heartworm (*Dirofilaria immitis*) disease in dogs of central Portugal. *Parasite*, 21.
- Voyvoda, H., Paşa, S., Töz, S. Ö., Özbel, Y., & Ertabaklar, H. (2004). Prevalence of *Leishmania infantum* and *Dirofilaria immitis* infection in dogs in Aydın province and the town of Selçuk, İzmir, Turkey. *Turkish Journal of Veterinary & Animal Sciences*, 28(6), 1105-1111.
- Wang, S., Zhang, N., Zhang, Z., Wang, D., Yao, Z., Zhang, H., . . . Liu, S. (2016).

Prevalence of *Dirofilaria immitis* infection in dogs in Henan province, central China. *Parasite*, 23.

- Yabaneri, F., Abdullah, İ., Yildirim, A., Önder, Z., Çiloğlu, A., & Düzlü, Ö. (2017). Avanos yöresi sokak köpeklerinde *Dirofilaria immitis*'in prevalansının belirlenmesi. *Sağlık Bilimleri Dergisi*, 26(2), 140-146.
- Yalçın, E., Şenlik, B., Yılmaz, Z., Alasonyalılar, A., & Akyol, V. (2007). Bursa'daki köpeklerde *Dirofilaria immitis*' in prevalansı. *JTVS*, 13(2), 23-27.
- Yaman, M., Guzel, M., Koltas, I., Demirkazık, M., & Aktas, H. (2009). Prevalence of *Dirofilaria immitis* in dogs from Hatay province, Turkey. *Journal of Helminthology*, 83(3), 255-260.
- Yıldırım, A. (2004). Ankara ve çevresindeki köpeklerde filarial etkenlerin prevalansı. *AÜ Vet Fak Derg*, 51, 35-40.
- Yildirim, A., Ica, A., Atalay, O., Duzlu, O., & Inci, A. (2007). Prevalence and epidemiological aspects of *Dirofilaria immitis* in dogs from Kayseri Province, Turkey. *Research in veterinary science*, 82(3), 358-363.
- Yıldız, K. (2018). *Dirofilaria-Dirofilaria*sis. In A. Doğanay (Ed.), *Helmintoloji* (pp. 313-322). Ankara: Ankara Nobel Tıp Kitabevleri Ltd Şti.
- Yıldız, K., Duru, S. Y., Yağcı, B. B., Öcal, N., & Gazyağcı, A. N. (2008). The prevalence of *Dirofilaria immitis* in dogs in Kırıkkale. *Türkiye Parazitoloj Derg*, 32(3), 225 - 228,.
- Zeybek, H. (1989). Ankara yöresi köpeklerinde *Dirofilaria immitis* olguları. *Etlik Veteriner Mikrobiyoloji Dergisi*, 6(5), 1-9.



## **CHAPTER 9**

### **GENERAL PERSPECTIVES OF ANTIOXIDANTS AND NATURAL SOURCES**

*Deniz KARAKCI<sup>1</sup>, Nilay SEYİDOĞLU<sup>2</sup>*

---

1 Assistant Professor, University of Tekirdag Namık Kemal Faculty of Veterinary Medicine, Department of Biochemistry E mail: dkarakci@nku.edu.tr  
ORCID: 0000-0002-1884-1874

2 Associate Professor, University of Tekirdag Namık Kemal Faculty of Veterinary Medicine, Department of Physiology E mail: nseyidoglu@nku.edu.tr  
ORCID: 0000-0002-2817-5131

## INTRODUCTION

Antioxidants are vital compounds and also systems that can safely interact with free radicals, and terminate the chain reaction in cell (Oroian & Escric, 2015). They are the most important weapon to eliminate the oxidative stress created by free radicals in the organism. Antioxidants are substances that can prevent cell damage by scavenging free radicals (Shinde et al., 2012).

Antioxidant was firstly described as “any substance that, when present in low concentrations compared to the non-oxidizable substrate, significantly delays and thus inhibits the oxidation of that substrate” by Halliwell and Gutteridge (1989). The term antioxidant is used to refer to a chemical that specifically inhibits oxygen consumption. Extensive research was conducted in the late 19th and early 20th centuries on the use of antioxidants in vital processes especially prevention of metal corrosion, rubber vulcanization, and fuel polymerization in the fouling of internal combustion engines (Matill, 1947). However, vitamins A, C, and E are known as vital antioxidants. They can be revolutionized this field by leading to a better understanding of antioxidants in the biochemistry of body (Knight, 1998). The possible mechanisms of action of antioxidants were first discovered by the realization that a substance with antioxidant activity can be easily oxidized. Antioxidants have been identified as reducing agents that prevent oxidative reactions, often by scavenging ROS before it can damage cells, as a result of research into how vitamin E inhibits the lipid peroxidation process (Wolf, 2005).

They can use various mechanisms, including scavenging species that initiate peroxidation, chelating metal ions to prevent them from producing reactive species or decomposing peroxides, quenching  $O_2$  to prevent peroxide formation, breaking the auto-oxidative chain reaction, and/or reducing localized  $O_2$  concentrations (Asimi et al., 2013).

Antioxidants in the body are either produced naturally by the body or taken as an external supplement. Both endogenous and exogenous antioxidants act as free radical scavengers. Therefore, they increase the defense system and reduce the diseases risks (Shinde et al., 2012) by neutralizing excess free radicals, protecting cells against the toxic effects of free radicals, and contributing to the prevention of diseases (Pham-Huy et al., 2013).

Both endogenous and exogenous antioxidants can maintain and re-establish the redox potential and homeostasis. Exogenous defense comes from antioxidant vegetables and fruits. Insight of literatures, exogenous antioxidants are important for a better health and life quality. As well, several specific natural antioxidants have several functional features and effects on diseases. The relationship between natural antioxidants and health is related to the structure and compounds of natural antioxidants.

### *A Sight of Antioxidants from Free Radicals and Reactive Oxygen Species*

Elements, atoms, or molecules with an unpaired electron in the outer orbital are classified as free radicals. In this way, they can exist independently (Poljsak et al., 2013). The presence of an unpaired electron results in some properties that most radicals share. Many radicals are highly reactive and unstable. The vast majority of chemically active  $O_2$  derivatives are free radicals. Two unpaired electrons with parallel spin states exist in molecular oxygen ( $O_2$ ). Although they have unpaired electrons, transition metals such as  $Fe^+$ ,  $Cu^{+2}$ ,  $Mn^{+2}$ , and  $Mo^{+5}$  are not considered free radicals. Free radicals can be positively cations or negatively charged anions, or electrically neutral. They can give an electron to or take an electron from other molecules, so they act as oxidants or reductants (Cheeseman and Slater, 1993). The most important oxygen-containing free radicals in many diseases are hydroxyl radicals, superoxide anion radicals, hydrogen peroxide, hypochlorite, nitric oxide radicals and peroxyxynitrite radicals. These are highly reactive species capable of damaging biologically relevant molecules such as DNA, proteins, carbohydrates and lipids in the nucleus and cell membranes. Free radicals attack critical macromolecules, causing cell damage and homeostasis breakdown. Free radicals can attack any type of molecule in the body and the main targets are lipids, nucleic acids, and proteins (Young & Woodside, 2001).

Reactive oxygen species (ROS) can be defined as free and non-free radical oxygen molecules, especially hydrogen peroxide ( $H_2O_2$ ), superoxide ( $O_2\cdot$ ), singlet oxygen ( $1/2 O_2$ ) and hydroxyl radical (OH), and singlet oxygen ( $O_2$ ). Reactive nitrogen, copper, iron and sulfur types are also seen (Halliwell et al., 1992; Riley, 1994). Oxidative stress and redox balance's disruption are caused by these radical species. The influence of endogenous and exogenous free radicals can't be prevented due to the metabolic processes and the influence of environmental oxidants (Poljsak et al., 2013).

Free radicals are important elements in aerobic processes. Especially they can exposure to microbial infections including cellular respiration, phagocyte activation, long physical activity, and during the action of pollutants/toxins such as smoking, alcohol, UV radiations, pesticides, ozone. Low amounts of reactive oxygen species consist of signaling molecules related to the regulation of cell proliferation, apoptosis, and gene expression transcription factors. Their production by phagocytes plays a vital role in the defense mechanism against various strains of bacteria or fungi (Poljsak et al., 2013). In the aerobic process, molecular oxygen, which is used to oxidize carbon and hydrogen-containing biomolecules to generate chemical energy and heat, is gradually reduced to a number of intermediate species which include hydroperoxyl radical, superoxide radical anion, hydrogen peroxide, hydroxyl anion and hydroxyl radical (Gutteridge, 1995).

### ***Oxidative Stress and Related Diseases***

Oxidative stress has a role in many diseases such as atherosclerosis, inflammatory conditions, some types of cancer, and the aging process. As well, oxidative stress is associated with some inflammatory diseases (glomerulonephritis, arthritis, adult respiratory disease syndrome and lupus), ischemic diseases (heart diseases and stroke), neurological disorders (muscular dystrophy, Alzheimer's disease and Parkinson's disease), hemochromatosis, emphysema, gastric ulcers, hypertension, preeclampsia, alcoholism and smoking-related diseases etc. Nevertheless, oxidative stress can lead to oxidation of proteins and lipids related to the changes of their structure and function (Stefanis et al., 1997).

As cardiovascular diseases are responsible for approximately half of the diseases that result in death, oxidative events may affect these diseases. Polyunsaturated fatty acids present in the blood as an essential part of low-density lipoproteins (LDL). It was reported that the oxidation of these lipid components in LDL plays a crucial role in atherosclerosis (Esterbauer et al., 1991). The important cell types in the vessel wall are endothelial cell, smooth muscle cell, and macrophage which cells can cause the release of free radicals that affect lipid peroxidation. This can lead to blood vessel damage and consequent plaque formation with symptoms of atherosclerosis. In addition, oxidized form of LDL is cytotoxic, and can damage endothelial cells directly. However, several cardiovascular diseases can be prevented by antioxidants such as  $\beta$ -carotene or vitamin E (Neuzil et al., 1997).

The superoxide, hydrogen peroxide, hydroxyl radical and nitric oxide, and their biological metabolites have vital roles in carcinogenesis. As a result of the reaction of free radicals with DNA, ROS disrupts the cross-links of DNA and causes DNA damage. Numerous researchers have suggested that free radicals may be involved in carcinogenesis, mutations and transformation. Their presence in the organism can lead to transformation and mutation, and finally cancer. The well-known of the biological effects of radiation, the induction of mutagenesis, occurs mainly through DNA damage by HO. Thereby these effects cause mutagenesis of cell and carcinogenesis. Also, lipid peroxides are responsible for the activation of carcinogenesis (Poppel and Goldbohm, 1995).

Antioxidants can directly scavenge the ROS and inhibit cell proliferation for reducing oxidative stress-induced carcinogenesis. A vital antioxidant named  $\beta$ -carotene is a protective role against cancer due to its antioxidant properties on genetic damage.  $\beta$ -carotene has the photo protective properties that may improve the organism against ultraviolet light-induced cancer. This molecule also contributes the immunity through cancer prevention. Also, Vitamin C can help to prevent cancer. Possible antioxidant



mechanisms about preventing process of vitamin C in carcinogenesis include the blocking nitrosamine formation, accelerating the immune responses and the detoxification of liver enzymes. Vitamin E, an important antioxidant, can also provide resistance to immunodeficiency and bacterial infections, and cell-mediated immunity by increasing humoral antibody protection (Glatthaar et al., 1986).

**Types of Antioxidants**

Oxidative damage can be met by severity of antioxidant enzymes and vitamins (Bayil et al., 2008; Karabulut et al., 2009). First, antioxidants are classified as endogenous or exogenous. While endogenous antioxidants are produced by the body, exogenous ones need to be supplemented. Endogenous antioxidants, are divided into enzymatic and non-enzymatic defense systems. The necessity of these systems is to prevent the ROS-induced cellular damage (Gutteridge, 1995) Enzymatic antioxidants are Superoxide Dismutase (SOD), Glutathione Peroxidase (GSH), Catalase (CAT), and Glutathione Reductase (GR) (Table 1).

*Table 1. Endogenous and Exogenous Antioxidants*

ENDOGENOUS ANTIOXIDANTS		EXOGENOUS ANTIOXIDANTS	
Enzymatic Antioxidants	Non-Enzymatic Antioxidants		
Superoxide Dismutase (SOD)	Glutathione		Vitamin E (α-Tocopherol)
Glutathione Peroxidase (GSH)	Melatonin		Vitamin C (Ascorbic Acid)
Catalase (CAT)	Coenzyme Q10		Vitamin A (β-Carotene)
Glutathione Reductase (GR)	Transferrin		Folic Acid (Vitamin B9)
	Ceruloplasmin		Cytokines (TNF ve IL-1)
	Uric acid		Lycopene
	Selenium		

**Superoxide Dismutase (SOD)**

Superoxide Dismutase (SOD) is the enzyme that catalyzes the breakdown of the superoxide radical into hydrogen peroxide and molecular oxygen (Young and Woodside, 2001). SOD is found in all aerobic cells and extracorporeal fluids in organism. There are three forms of SOD depend-

ing on the metal cofactors which include Cu/Zn which binds both copper and zinc, Mn-SOD and Cu-SOD (Sanyal et al., 2009).

The Cu/Zn SOD weighs 32,000 daltons and is found in the cytoplasm, nuclear compartments and lysosomes, and gene mutations play a role in the pathophysiology of Down syndrome, Amyotrophic Lateral Sclerosis (ALS). Mn-SOD is found in the mitochondria of aerobic cells and weighs 23,000 daltons. Mn-SOD plays a major role in cell differentiation, tumorigenesis, and hypoxia induced by pulmonary toxicity. In addition, Mn-SOD gene mutations can be associated with rare familial motor neuron diseases, idiopathic cardiomyopathy, and premature aging. Cu-SOD is the most recently detected member of the SOD family. This enzyme weighs 135,000 daltons. Also it is found in blood, lymph fluid and synovial fluid. Cu-SOD is especially high in vessel walls. It has been shown that vascular smooth muscle cells synthesize a large amount of Cu-SOD (Zelko et al., 2002).

### ***Catalase (CAT)***

Catalase (CAT) consists of four protein subunits (includes heme and NADPH molecule). Catalase is predominantly found in intracellular organelles such as peroxisomes and less commonly in mitochondria and endoplasmic reticulum. It catalyzes the conversion of hydrogen peroxide to  $H_2O$  and  $O_2$  (Kirkman et al., 1987).

Increased superoxide radicals damage mitochondria. Antioxidant defense systems take precautions against the damage that ROS may cause. Superoxide radicals formed in mitochondria are first destroyed by Mn-SOD and glutathione peroxidase enzymes. However, a significant amount of  $H_2O_2$  leaves the mitochondria and passes into the cytoplasm. Detoxification of  $H_2O_2$  passing from mitochondria to cytosol is performed by CAT enzyme synthesized by peroxisomes. CAT synthesized from peroxisomes clears higher steady-state  $H_2O_2$  concentrations than glutathione peroxidase (Radi et al., 1991). Catalase is a hemoprotein that includes a single ferriprotoporphyrin in every polypeptide structure. Catalase also can fragment the  $H_2O_2$  molecules in one second. CAT activity can occur in two steps. A hydrogen peroxide molecule oxidizes Heme to an oxyferryl species. In low amounts, hydrogen peroxide can regulate some physiological processes, especially carbohydrate metabolism, cell signal transduction, mitochondrial function, cell death, platelet activation, and also normal thiol redox balance maintenance (Chelikani et al., 2004). However, it is stated that it is very harmful for the cell at high concentrations. Therefore, CAT can restrict the  $H_2O_2$  concentration in cells, and can play important role as a first-line antioxidant defense enzyme. Either deficiency or mutation of the CAT enzyme is associated with abnormalities and several diseases. Studies have reported that the risk of oxidative DNA damage and cancer susceptibility increases in individuals

with the change in CAT gene activity and genetic polymorphism, and the development of mental disorders as a result of the polymorphism in the gene encoding CAT. Other studies showed that people with low CAT levels are more prone to type 2 diabetes mellitus, hypertension, and are sometimes effected by neoplasm and atherosclerosis. In this sense, CAT is one of the most studied enzyme classes and forms the basis of antioxidant studies in many different organisms (Zámocky and Koller, 1999).

### ***Glutathione Peroxidase***

Glutathione peroxidase (GSH) is found in the cytoplasm of cells and protects cells against oxidative damage caused by  $H_2O_2$ . Therefore, it prevents the formation of OH from  $H_2O_2$ . Glutathione peroxidase is an important antioxidant breaking down hydrogen peroxide into water in the mitochondria and the cytosol. Most of the time its activity is dependent on selenium. Therefore, it can be divided into selenium-bound GPx and non-selenium-bound GPx. The main role of GPx is to protect the cell against oxidative stress (Cnubben et al., 2001). According to research, low GPx levels cause deterioration of the antioxidant system. As a result, the formation of oxidative damage in membrane fatty acids and functional proteins, the development of neurotoxic damage and permanent damage together with neurodegeneration indicate that the antioxidant defense system is impaired. In another study, it was shown that GPx decreased in testicular tissue stimulated by electrical field, sperm DNA damage occurred, and a decrease in sperm count and motility occurred. Blankenberg et al. (2003) showed that decreased GPx activity in people with coronary artery disease may be associated with cardiovascular disease risk (Blankenberg et al., 2003).

### ***Glutathione Reductase***

Glutathione reductase (GR) is a flavoprotein enzyme containing flavin adenine dinucleotide (FAD). Glutathione reductase is converted back to GSH by transferring an electron from NADPH to the disulfide bonds of oxidized glutathione. Therefore, NADPH is necessary to prevent free radical damage and its most important source is the pentose phosphate pathway (Özkan and Fışkın, 2004).

### ***Natural Antioxidants***

New researches addressed that natural antioxidants are important for a better health and life quality. In addition, the relationship between natural antioxidants and health have been interested for many years. Natural antioxidants play significant role in improve of diseases. The mechanism of antioxidants are highlighted by two ways: The classical antioxidant mechanism prevents a target molecule which can neutralize free radicals acting. The other one is defined on redox signaling which disturbed in the pro oxidant antioxidant balance.

Natural antioxidants are widely observed in several plants, vegetables, fruits, herbs and spices (Table 2). The most important ones are ginger, licorice, rosemary, thyme, garlic and aniseed. All these antioxidants play several behaviors on health and life quality, especially anticancer, antiinflammatory, antidiabetic and anti aging effects. The importance of the antioxidant mechanism is belonged to oxidant-antioxidant balance. Studies indicated that natural antioxidants process the stress, pathogen infestation, immunological diseases, neurological diseases and etc. There have been numerous studies demonstrating health benefits of natural antioxidants (Li et al., 2014; Jiang and Xiong, 2016; Seyidoglu and Aydin, 2020; Aydin and Seyidoglu, 2021)

Nevertheless, the activities of natural antioxidants are related to their various compounds. The major components are polyphenols (phenolic acids, flavonoids), carotene, glutathione, phycocyanin, vitamin E and C, and volatile oils. These biochemical components express the functional properties of antioxidants. It is well known that they have greater biological effects on organism. However, the extraction methods of the natural antioxidants which for these various compounds, have been interested by researchers (Azmir et al., 2013; Barba et al., 2016). The extraction techniques, applications, standardization and procedures are still being developed for getting more and useful extracts (Xu et al., 2017).

Table 2. Some interesting antioxidant sources.

NATURAL ANTIOXIDANTS		
Antioxidant Contents	Natural Sources	Mode of Action
Polyphenols	Apples, cherries, legumes, oregano, black pepper, licorice, green tea, onion, grapes, broccoli, red peppers, oranges, spinach	Blocking and cleaning the free radicals
Carotenoids	Carrot, potatoes, mango, microalga, broccoli, egg yolks, pumpkin	Ability of radical scavenging
Glutathione	Melons, avocado, fish, peach, broccoli, meat, strawberries	Maintain the reestablishment of redox homeostasis
Phycocyanin	<i>Algae, Spirulina platensis</i> , broccoli, peas	Inhibiting the lipid peroxidation and radicals
Ascorbic acid (Vitamin C)	Vegetables, strawberries	Scavenging reactive oxygen species
Alpha-tocopherol (Vitamin E)	Grains, fish, liver oil, seeds	Chain break
Volatile oils	Vegetables, fruits, flowers, rhizomes, seeds	Ability of free radical scavenging

### ***Polyphenols***

Polyphenols include phenolic acids and flavonoids which are the most important antioxidant molecules. It was indicated that these compounds can serve organisms from oxidative stress by blocking and cleaning the free radicals. Polyphenols target to improve some important diseases, especially diabetes, cardiovascular disease, inflammation, and cancer. *Phenolic acids* are the most studied ones in polyphenols, especially gallic acid and caffeic acid. There are some exogenous phenolic compounds in nature as apples, cherries, legumes, oregano, black pepper, licorice extract and etc (Xu et al., 2017; Seyidoglu and Aydin, 2020). Phenolic acids have the ability for breaking radical chain reactions and show the antioxidant activity. *Flavonoids* can be derived from vegetables and fruits such as green tea, onion, grapes, broccoli, red peppers, oranges, spinach (Xu et al., 2017; Seyidoglu and Aydin, 2020). Flavonoids have a role on binding iron to improve the antioxidant potential of cells. In addition, they can achieve the free radicals clearance after convert the lipid compounds to phenolic radicals (Li et al., 2014).

### ***Carotenoids***

Carotenoids are important antioxidant molecules in several fruits and vegetables. Also, they are assigned as natural pigment, including lutein, beta carotene, zeaxanthin (Seyidoglu and Aydin, 2020). Beta carotene can be derived from carrot, potatoes, mango and nuts. Zeaxanthin can be found in some green plants especially in microalga, broccoli, egg yolks and pumpkin. Carotenoids have important biological effects like as antibacterial, anticancer, anti-inflammatory and antioxidant. They also have prooxidant action in organism. Carotenoids exhibit their ability of radical scavenging for biological systems. In addition, increased oxygen concentration is related with carotenoid activity (Jomova and Valko, 2013). In addition, carotenoids prevents the protein and DNA structure against oxidative stress. However, there are contradictory results related to carotenoids (McNulty et al., 2008).

### ***Glutathione***

Glutathione protects the cell from free radicals. This antioxidant molecule has a protecting role on the biological membranes with Vitamin E through the antioxidant process together. They all maintain the reestablishment of redox homeostasis. They can maintain the alpha tocopherol for preventing the cells against oxidative stress (Petersen and Doorn, 2004). Also, the glutathione activity in kidney was reported by some researchers (Xu et al., 2017). Glutathione can be found in several foods such as melons, avocado, fish, peach, broccoli, meat, strawberries and etc. Besides many of the natural fruits and vegetables, there are some spice and oils include

glutathione especially curcumin and thyme oil. Nevertheless, glutathione has important efficiency against diabetes, lung diseases, cancer and infertility (Xu et al., 2017; Seyidoglu and Aydin, 2020).

### ***Phycocyanin***

Phycocyanin is an extract from a microalga called *Spirulina platensis*. Its antioxidant mechanism is based on inhibiting the lipid peroxidation and radicals (McNulty et al., 2008). Also, it was observed that it can support the immunity and life quality by improving the antioxidant activity of organism (Karkos, 2011). Phycocyanin can improve the erythropoietin activity which based on lymphocytes (Løbner et al., 2008; Selmi et al., 2011). The most important one of the natural source of phycocyanin is seaweed (algae). In addition, it can be found in broccoli and peas. Many studies have been performed on the several effects like obesity, cancer, fertility and anemia (Seyidoglu et al., 2017).

### ***Ascorbic acid (Vitamin C) and Alpha-tocopherol (Vitamin E)***

Ascorbic acid (Vitamin C) and Alpha-tocopherol (Vitamin E) can change the enzyme system in oxidant antioxidant balance, and prevent the cellular membranes against oxidative stress. These vitamins are rich in fruits especially orange and lemon. Vitamin C is found in vegetables and strawberries, although Vitamin E is in whole grains, fish, liver oil and seeds. Vitamin E is a chain-break antioxidant, and protects the cells from lipid peroxidation. Also, it can be restored by Vitamin C. Vitamin E can scavenge lipid peroxyl radicals through the phospholipids as a chain-breaking antioxidant. It can be regenerated by redox reactions, and enhance the role of lipid antioxidant efficiency. Also it has important inhibitory activity on lipid peroxidation in erythrocytes, and protects the polyunsaturated fatty acids (Howard et al., 2011). On the other hand, vitamin C has biological effects by acting like an enzyme cofactor and also an antioxidant. It protects against oxidative stress by scavenging reactive oxygen species. However, vitamin C has important role in function of nitric oxide synthase (Traber and Stevens, 2011).

### ***Volatile oils***

Volatile oils sometimes are called essential oils. Among traditional herbs and spices, the most known oils are eugenol, carvacrol, thymol and menthol. Besides that, some flowers (rose, jasmine), fruits (anise, fennel), rhizomes (ginger) and seeds (nutmeg, cardamom) have volatile oils. These oils have antioxidant activity because of their ability of free radical scavenging. Volatile oils have significant effects such as antibacterial, antifungal, antispasmodic and antiviral (Dhifi et al., 2016).

Some of them showed a direct effect on diseases, some of them are

capable of effectively altering the functional capacity of diseases. In addition, they are used as an antimicrobial agent for pathogenic diseases. Moreover, clinical and experimental studies have been still documented the effects of volatile oils on health and diseases. (Korinek et al., 2021).

## CONCLUSIONS

The etiology of many chronic diseases especially cardiovascular and inflammatory diseases, and cancer can be contributed by free radical damage. Antioxidants prevent the tissue damage by averting, scavenging, radical formation or promoting the free radicals' decomposition. Therefore, natural compounds with antioxidant activity have interested by recent years.

Nutrition, stress, environmental differences, genetic factors and physiological insufficiency are important for a better life quality. Nowadays, besides medicinal therapy, antioxidant strategies and uses are being important. However, there has been still questionable for their uses and effects.

The findings of natural antioxidants on health are shed a light for scientific area. The researchers are still trying to show the therapeutic potential of natural antioxidants. The most important feasibilities are reducing health risk, improving life quality, less adverse effects and accessibility. However, further researches are necessary to determine the antioxidants that possess important potential of developing.

## REFERENCES

- Asimi, O.A., Sahu, N.P., & Pal, A.K. (2013). Antioxidant capacity of crude water and ethylacetate extracts of some Indian species and their antimicrobial activity against *Vibrio vulnificus* and *Micrococcus luteus*. *Journal of Medicinal Plants Research*, 7(26), 1907-1915.
- Aydin, C., & Seyidoglu, N. (2021). Natural Antioxidants to the Rescue? In *Antioxidants Benefits, Sources, Mechanisms of Action*. V.Y. Waisundara (Ed), (pp. 131-149), Intech Open, London.
- Azmir, J., Zaidul, I.S.M., Rahman, M.M., Sharif, K.M., Mohamed, A., Sahena, F., Jahurul, M.H.A., Ghafoor, K., Norulaini, N.A.N. & Omar, A.K.M. (2013). Techniques for extraction of bioactive compounds from plant materials: A review. *Journal of Food Engineering*, 117, 426-436.
- Barba, F.J., Zhu, Z., Koubaa, M., Sant'ana, A.S., & Orlie, V. (2016), Green alternative methods for the extraction of antioxidant bioactive compounds from winery wastes and by-products: A review. *Trends in Food Science and Technology*, 49, 96-109.
- Bayil, S., Cicek, H., Cimenci, I.G., & Hazar, M. (2008). How volatile organic compounds affect free radical and antioxidant enzyme activity in textile workers. *Achieves of Industrial Hygiene and Toxicology*, 59, 283-287.
- Blankenberg, S., Rupprecht, H.J., Bickel, C., Torzewski, M., Hafner, G., Tiret, L., Smieja, M., Cambien, F., Meyer, J., & Lackner, K.J. (2003). Glutathione Peroxidase 1 Activity and Cardiovascular Events in Patients with Coronary Artery Disease. *The New England Journal of Medicine*, 349, 1605-1613.
- Cheeseman, K.H., & Slater, T.F. (1993). An introduction to free radicals chemistry. *British Medical Bulletin*, 49, 481-493.
- Chelikani, P., Fita, I., & Loewen, P.C. (2004). Diversity of structures and properties among catalases. *Cellular and Molecular Life Sciences*, 61, 192-208.
- Cnubben, N.H.P., Rietjens, I.M.C.M., Wortelboer, H., Van, Zanden, J., & Van, Bladeren P.J. (2001). The interplay of glutathione-related processes in antioxidant defense. *Environmental Toxicology and Pharmacology*, 10, 141-152.
- Dhifi, W., Bellili, S., Jazi, S., Bahloul, N., & Mnif, W. (2016). Essential Oils' Chemical Characterization and Investigation of Some Biological Activities: A Critical Review. *Medicines (Basel)*, 22, 3(4), 25.
- Esterbauer, H., Puhl, H., & Dieber-Rotheneder, M. (1991). Effect of antioxidants on oxidative modification of LDL. *Annals of Medicine*, 23, 573-581.
- Glatthaar, B.E., Horing, D.H., & Moser, U. (1986). The role of ascorbic acid in carcinogenesis. *Advance in Experimental Medicine and Biology*, 206, 357-77.



- Gutteridge, J.M.C. (1994). Biological origin of free radicals, and mechanisms of antioxidant protection. *Chemico Biological Interactions*, 91, 133-140.
- Gutteridge, J.M. (1995). Lipid peroxidation and antioxidants as biomarkers of tissue damage. *Clinical Chemistry*, 41, 1819-1828.
- Halliwell, B. & Gutteridge, J.M. Free radicals in biology and medicine, 2nd ed. Oxford: Clarendon Press, 1989.
- Howard, A.C., Anna, K., Mcneil, A.K., & Mcneil, P.L. (2011). Promotion of plasma membrane repair by vitamin E. *Nature Communications*, 20, 597.
- Jiang, J., & Xiong, Y.L. (2016). Natural antioxidants as food and feed additives to promote health benefits and quality of meat products: A review. *Meat Science*, 120, 107-117.
- Jomova, K., & Valko, M. (2013). Mini-review-Health protective effects of carotenoids and their interactions with other biological antioxidants. *European Journal of Medicinal Chemistry*, 70, 102-110.
- Karabulut, I., Balkanci, Z.D., Pehlivanoglu, B., Erdem, A., & Fadillioglu E. (2009). Effect of toluene on erythrocyte membrane stability under in vivo and in vitro conditions with assessment of oxidant/antioxidant status. *Toxicology and Industrial Health*, 25, 545-550.
- Karkos, P.D., Leong, S.C., Karkos, C.D., Sivaji, N., & Assimakopoulos, D.A. (2011). Spirulina in clinical practice: Evidence-based human applications. *Evidence-Based Complementary and Alternative Medicine: eCAM*, 2011, 1-4.
- Kirkman, H.N., Galiano, S., & Gaetani, G.F. (1987). The function of catalase-bound NADPH. *Journal of Biological Chemistry*, 262(2), 660-666.
- Knight, J. (1998). Free radicals: Their history and current status in aging and disease. *Annals of Clinical and Laboratory Science*, 28, 331-46.
- Korinek, M., Handoussa, H., Tsai, Y.H., Chen, Y.Y., Chen, M.H., Chiou, Z.W., Fang, Y., Chang, F.R., Yen, C.H., Hsieh, C.F., Chen, B.H., El-Shazly, M., & Hwang, T.L. (2021). Anti-Inflammatory and Antimicrobial Volatile Oils: Fennel and Cumin Inhibit Neutrophilic Inflammation via Regulating Calcium and MAPKs. *Frontiers in Pharmacology*, 12, 674095.
- Li, S., Chen, G., Zhang, C., Wu, M., Wu, S., & Liu, Q. (2014). Research progress of natural antioxidants in foods for the treatment of diseases. *Food Science and Human Wellness*, 3, 110 -116.
- Løbner, M., Walsted, A., Larsen, R., Bendtzen, K., & Nielsen, C.H. (2008). Enhancement of human adaptive immune responses by administration of a high-molecular-weight polysaccharide extract from the cyanobacterium *Arthrospira platensis*. *Journal of Medicinal Food*, 11(2), 313-322.
- Matill, H.A. (1947). Antioxidants. *Annual Review of Biochemisrty*, 16, 177-92.
- McNulty, H., Jacob, R.F., & Mason, R.P. (2008). Biologic activity of carotenoids related to distinct membrane physicochemical interactions. *The American*

*Journal of Cardiology*, 101(10A), 20-29.

- Neuzil, J., Thomas, S.R., & Stocker, R. (1997). Requirement for promotion, or inhibition of  $\alpha$ -tocopherol of radical induced initiation of plasma lipoprotein lipid peroxidation. *Free Radical Biology and Medicine*, 22, 57-71.
- Oroian, M., & Escric, I. (2015). Antioxidants: Characterization, natural sources, extraction and analysis. *Food Research International*, 74, 10-36.
- Özkan, A., & Fışkın, K. (2004). Serbest Oksijen Radikalleri, Karsinogenez ve Antioksidant Enzimler. *Türk Hematoloji Onkoloji Dergisi*, 14, 52-60.
- Petersen, D.R., & Doorn, J.A. (2004). Reactions of 4-hydroxynonenal with proteins and cellular targets. *Free Radical Biology and Medicine*, 37, 937-945.
- Pham-Huy, L.A., He, H., & Pham-Huy, C. (2008). Free Radicals, Antioxidants in Disease and Health. *International Journal of Biomedical Science*, 4(2), 89-96.
- Poljsak, B., Suput, D., & Milisav, I. (2013). Achieving the balance between ROS and antioxidants: when to use the synthetic antioxidants. *Oxidative Medicine and Cellular Longevity*, 2013, 1-11. <http://dx.doi.org/10.1155/2013/956792>.
- Poppel, G.V., & Goldbohm, R.A. (1995). Epidemiologic evidence for  $\beta$ -carotene and cancer prevention. *American Journal of Clinical Nutrition*, 62, 1393-1395.
- Radi, R., Turrens, J.F., Chang, L.Y., Bush, K.M., Crapo, J.D., & Freeman, B.A. (1991). Detection of catalase in rat heart mitochondria. *Journal of Biological Chemistry*, 266, 22028-22034.
- Riley, P.A. (1994). Free radicals in biology: oxidative stress and the effects of ionizing radiation. *International Journal of Radiation Biology*, 65, 27-33.
- Sanyal, J., Bandyopadhyay, S.K., Banerjee, T.K., Mukherjee, S.C., Chakraborty, D.P., Ray, B.C., & Rao, V.R. (2009). Plasma levels of lipid peroxides in patients with Parkinson's disease. *European Review for Medical and Pharmacological Sciences*, 13(2), 129-132.
- Selmi, C., Leung, P.S., Fischer, L., German, B., Yang, C.Y., Kenny, T.P., Cysewski, G.R., & Gershwin, M.E. (2011). The effects of Spirulina on anemia and immune function in senior citizens. *Cellular and Molecular Immunology*, 8, 248-254.
- Seyidoglu, N., & Aydin, C. (2020). Stress, Natural Antioxidants and Future Perspectives. L.C. Salanță (ed), In: *The Health Benefits of Foods-Current Knowledge and Further Development*. (pp 149-165), IntechOpen, London.
- Seyidoglu, N., Inan, S., & Aydin, C. (2017). A Prominent Superfood: Spirulina platensis. N. Shiomi, and V. Waisundara (Eds.), In: *Superfood and Functional Food – The Development of Superfoods and Their Roles as Medicine*. (pp. 1-29), IntechOpen, London.
- Shinde, A., Ganu, J. & Naik, P. (2012). Effect of free radicals & Antioxidants on

- oxidative stress: A Review. *Journal of Dental and Allied Sciences*,1(2), 63- 66.
- Stefanis, L., Burke, R.E., & Greene, L.A. (1997). Apoptosis in neurodegenerative disorders. *Current Opinion in Neurology*, 10, 299-305.
- Traber, M.G., & Stevens, J.F. (2011). Vitamins C and E: Beneficial effects from a mechanistic Perspective. *Free Radical Biology and Medicine*, 51(5), 1000-1013.
- Wolf, G. (2005). The discovery of the antioxidant function of vitamin E: The contribution of Henry A. Mattill. *The Journal of Nutrition*, 135, 363-366.
- Xu, D.P., Li, Y., Meng, X., Zhou, T., Zhou, Y., Zheng, J., Zhang, J.J., & Li, H.B. (2017). Natural antioxidants in foods and medicinal plants: Extraction, assessment and resources. *International Journal of Molecular Sciences*, 18(1), 96.
- Young, I.S., & Woodside, J.V. (2001). Antioxidants in health and disease. *Journal of Clinical Pathology*, 54, 176-86.
- Zámocky, M., & Koller, F. (1999). Understanding the structure and function of catalases: clues from molecular evolution and in vitro mutagenesis. *Progress in Biophysics Molecular Biology*, 72, 19-66.
- Zelko, I.N., Mariani, T.J., & Folz, R.J. (2002). Superoxide dismutase multigene family: a comparison of the CuZn-SOD (SOD1), Mn-SOD (SOD2), and EC-SOD (SOD3) gene structures, evolution, and expression. *Free Radical Biology & Medicine*, 33(3), 337-349.





## ***CHAPTER 10***

### **VARICOCELE, TESTOSTERONE HORMONE AND VARICOCELECTOMY**

*Saadet BELHAN<sup>1</sup>*

---

<sup>1</sup> Assoc. Prof. Dr. Van Yuzuncu Yil University, Faculty of Veterinary Medicine, Department of Reproduction and Artificial Insemination, Van, Turkey. ORCID ID: <http://orcid.org/0000-0002-8115-2051>

## INTRODUCTION

Varicocele, which is defined as the enlargement of the veins in the spermatic cord, which takes on the role of venous drainage in the testicular tissue, above the physiological limits (Kendirci et al., 2003), although it is usually seen on the left side, it has been reported to be bilateral at a rate of more than 50% (Amelar and Dubin, 1987). Its prevalence in the male population is 10-15%, and this rate rises to 40% in cases of infertility (Dubin and Amelar, 1971). It has been reported that varicocele is seen more frequently in men with secondary infertility, and fertility declines if treatment is not followed (Gorelick and Goldstein, 1993).

### **Varicocele, Spermatogenesis and Testosterone**

Varicocele causes some harmful effects on reproduction and testosterone hormone. These detrimental effects may be caused by a combination of factors such as increased testicular temperature, hormonal dysfunction, changes in testicular blood flow, reflux of toxic metabolites, and hypoxia in the seminiferous tubules (Pryor and Howards, 1987). Hotchkiss, who first described the effect of varicocele on fertility, emphasized the importance of the issue in 1944 (Tulloch, 1955). It is known that male fertility is dependent on spermatogenesis and testosterone plays an important role in maintaining spermatogenesis (Alkaram and McCullough, 2014). A very large proportion of testosterone is produced by Leydig cells. Leydig cells are responsible for testosterone biosynthesis and secretion as well as spermatogenesis. Testosterone levels vary according to the number of Leydig cells and the capacity of these cells to produce testosterone (Luo et al., 2011). It has been suggested that varicocele disrupts normal endocrine function by apoptosis in Leydig cells and thus leads to suppression of secreted testosterone (Henriksén et al., 1995; Luo et al., 2011). In particular, varicocele has been reported to cause decreased production of the StAR protein, which may compromise the transport of cholesterol, the substrate of androgen biosynthesis, to the mitochondria. This decrease causes a decrease in testosterone levels produced by Leydig cells (Luo et al., 2011).

Considering the importance of testosterone levels for spermatogenesis and fertility, and the decrease in testosterone levels in cases of varicocele, the importance of varicocele in male reproduction will become very striking (Benoff and Gilbert, 2001). Studies have shown that animals with varicocele have an increase in apoptosis of Leydig cells and a decrease in testosterone synthesis compared to animals without varicocele (Luo et al., 2011). Varicocele has also been reported to impair Leydig cell functions and decrease serum testosterone levels in non-infertile men (Comhaire and Vermeulen, 1975; Pirke et al., 1983).

Increase in testicular temperature and spermatic vein pressure, accumulation of adrenal waste products and autoimmunity create a toxic environment not only for Leydig cells but also for Sertoli cells (Shiraishi et al., 2010). There have been increases in testicular temperature and hydrostatic pressure in both testicles in the presence of varicocele in humans and animals (rat, ram, monkey) (Gomes et al., 1971; Green et al., 1984; Fussel et al., 1981; Harrison et al., 1983). It is known that there are problems in testosterone production in varicocele. Testicular temperature increase can be counted among the reasons that pave the way for these problems. It is known that the activity of any enzyme is dependent on temperature. The increase in intratesticular temperature has an inhibitory effect on the activities of enzymes involved in the conversion of cholesterol to testosterone in the testis (Bedrak et al., 1971; Gomes et al., 1971). Venous stasis also has an important place among the predisposing causes. Because venous stasis causes damage and depletion of Leydig cells and suppression of testosterone synthesis (Andres et al., 1981; Chakraborty et al., 1985).

### **Varicocele and Hypogonadism**

Varicocele is an important risk factor for hypogonadism (Andò et al., 1984; Luo et al., 2011). However, it is not known exactly how long it takes for a varicocele to cause hypogonadism. Varicocele may decrease sperm quality over time, however, it should be noted that not all men with varicocele are infertile. In addition, it is not correct to conclude that all men with varicocele will be hypogonadal. However, it may be correct to say that men with varicocele are at greater risk for hypogonadism (Whelan and Levine, 2016).

In a reported study, an experimental varicocele was created and testosterone levels were evaluated. In the study, it was determined that serum testosterone levels did not change 8 weeks after varicocele induction. Researchers have suggested that 8 weeks may not be long enough to observe these changes. They also explained that, as another reason for the lack of change, the adrenal gland also secretes a certain amount of testosterone and can compensate for the loss that may occur due to varicocele. In the same study, intratesticular testosterone concentration did not change after 4 weeks and decreased significantly after 8 weeks compared to controls (Luo et al., 2011). The decrease in intratesticular testosterone in varicocele may also be caused by the weak response of testosterone to human chorionic gonadotropin (hCG) stimulation (Sofikitis and Miyagawa, 1994). As a matter of fact, Kazama (1995) determined that there was a decrease in the binding of hCG to Leydig cells in the rat testis with varicocele. In another study, it was reported that serum free testosterone levels were lower and estradiol and steroid-binding globulin levels were higher (Kazama, 1995).

In an experimental study, the effects of varicocele on testosterone, apoptosis and StAR mRNA expression in Leydig cells were evaluated. In the study, 40 rats were divided into two groups and testosterone (serum and intratesticular) levels were evaluated 4 and 8 weeks after the operation. After 8 weeks, intratesticular testosterone levels and StAR mRNA levels in Leydig cells decreased significantly, and the mean apoptosis index of Leydig cells increased significantly. Researchers have reported that varicocele impairs Leydig cell function by increasing apoptosis and suppressing the expression of StAR protein (Luo et al., 2011).

Khosravian et al. (2014) found that the number of Leydig cells in the varicocele group decreased significantly and the number of hypertrophied Leydig cells increased. They also explained that serum testosterone decreased significantly, but when VitE and testosterone were administered together, the degeneration of Leydig cells was alleviated and testosterone levels increased.

In studies conducted on humans, it has been reported that there are problems in sperm and hormonal parameters in varicocele and that the level of follicle stimulating hormone (FSH) increases (Nagao et al. 1986; Nieschlag et al., 1997). Another study reported a link between varicocele and erectile dysfunction (Kim and Choi, 1992).

### **Diagnosis in Varicocele**

Varicocele is mostly diagnosed with the Valsalva maneuver. When diagnosing, grading is done as 1st degree, 2nd degree and 3rd degree. If varicocele is detected with the Valsalva maneuver, it is called 1 degree varicocele. If it can be detected without the Valsalva maneuver but is not visible to the naked eye, it is defined as a grade 2 varicocele. If it is understood by direct inspection, it is defined as 3rd degree (Dubin and Amelar, 1971). Apart from these definitions, there is also a subclinical varicocele that is not palpable and invisible, which can only be detected by imaging methods (de Los Reyes et al., 2017).

### **Treatment in Varicocele**

It is known that serious problems occur in Leydig cells and decrease in testosterone levels in clinical varicocele. It has also been reported that varicocele repair has beneficial effects on testosterone production in such cases (Comhaire and Vermeulen, 1975; Andò et al., 1984). Improvements in sperm quality and pregnancy rates have been reported after varicocele repair (Agarwal et al., 2007; Abdel-Meguid et al., 2011). Even in men with normal sperm parameters, varicocele repair is recommended to compensate for the decrease in testosterone hormone (Mehta and Goldstein, 2013). Varicocele repair has no significant effect on testosterone in men with nor-



mal or above normal testosterone levels. In such cases, varicocele repair may be considered to increase fertility (Fisch and Hyun, 2012).

The aim of the treatment of varicocele, which causes problems in testicular functions such as spermatogenesis and steroidogenesis, is to improve testicular function and sperm parameters and thus to increase the pregnancy rate. Reports describe varicocelectomy as a viable method to treat infertility in varicocele (Jensen et al., 2017; Mostafa et al. 2001). It has been reported that there is an improvement of 70% in spermatogenesis with surgical repair in varicocele, and an increase of 30% in the rate of spontaneous pregnancy with only varicocele repair without other treatments (Ficarra et al., 2012). However, varicocelectomy does not necessarily return the changed sperm parameters to their initial values (Lundy and Sabanegh, 2017). In addition, adjuvant treatments have been developed to assist varicocelectomy, since there has been no definitive success in the treatment of infertility (Esteves and Agarwal, 2016). It has been reported that varicocelectomy improves testosterone levels in varicocele patients (Li et al., 2012), decreases the concentration of reactive oxygen species and increases antioxidant capacity (Mostafa et al., 2001).

In hypogonadal men with varicocele, either testosterone administration or alternative varicocele treatments can be considered. However, it has been reported that there may be some advantages and disadvantages in both treatments. For example, when hypogonadal men are treated with long-term testosterone therapy, significant improvements in urinary and sexual function and quality of life are achieved (Haider et al., 2018). However, hypogonadal men with varicocele who want a child become 90% azoospermic under testosterone replacement therapy, and serious fertility problems occur. In some cases, azoospermia may persist despite discontinuation of exogenous testosterone therapy (Samplaski et al., 2014). It is unclear whether there will be adequate testosterone increase after varicocele repair if men opt for varicocelectomy (Schlegel and Goldstein, 2011). Alternative varicocele treatment methods in hypogonadal men with varicocele; open surgery, radiological interventions and laparoscopic methods (Rotker and Sigman, 2016; Çayan et al., 2019). However, among all methods, the microsurgical varicocelectomy method comes first. Because in this method, some complications such as varicocele recurrence, testicular atrophy and hydrocele formation occur at very low rates (Saylam et al., 2020). It is worth noting that if varicocele is not treated and if too much time passes, there will be progressive decreases in fertility (Gorelick and Goldstein, 1993).

It is expected that there will be some indications for intervention in adolescent varicoceles. The main indications are; testicular pain, testicular swelling, testicular hypotrophy/atrophy, density of varicocele and ab-

normal changes in sperm parameters if old enough. In adults, the main indications for intervention are infertility, hypogonadism and abnormal changes in sperm parameters (Alkaram and McCullough, 2014; Saylam et al., 2020). Repair of varicoceles is not recommended in men who are considered subclinical or have normal seminal parameters (Alkaram and McCullough, 2014).

### **Hormonal Change After Varicocele Treatment**

Different results have been reported regarding the effect of varicocele repair on hormonal parameters. Some studies suggest that testosterone concentration does not change after varicocele repair (Hudson et al., 1985; Segenreich et al., 1986). In a reported study, it was reported that in biopsies evaluating the histological appearance of Leydig cells, irreparable damage occurred in Leydig cell structures and these patients did not benefit from varicocelectomy (Hadziselimovic et al., 1986). In another study, it is reported that varicocele repair increases serum testosterone level (Li et al., 2012). According to Cayan et al. (1999) reported that varicocele repair increased Sertoli and Leydig cell function and produced significant increases in serum free testosterone levels (Cayan et al., 1999). Other investigators reported that hormones such as FSH, luteinizing hormone (LH), testosterone and estradiol remained at normal levels in patients with varicocele (Hudson et al., 1981; Schiff et al., 1976).

Abdel-Meguid et al. (2014) applied a 6-month follow-up period in their study. Researchers reported that basal testosterone levels decreased significantly in men with varicocele. They found that varicocelectomy produced significant testosterone improvements in hypogonadal men, while insignificant changes in eugonadals. They concluded that testosterone changes after varicocelectomy were significant and inversely proportional to baseline testosterone. Other studies have reported that varicocelectomy increases serum testosterone in men with infertile hypogonadism (Srini and Veerachari, 2011; Zohdy et al., 2011).

Another study reported significant improvements in serum testosterone after varicocelectomy in men aged 40 years (Hsiao et al., 2011). However, in 2 other studies in which varicocelectomy was performed, no significant changes were reported in serum testosterone levels (Hudson et al., 1985; Segenreich et al., 1986).

In the study conducted on 200 men with infertility, clinical varicocele and testosterone level less than 280 ng/dL, 100 men underwent surgery and 100 men underwent assisted reproductive techniques. While there were significant increases in testosterone levels in the 6th month postoperatively in those who underwent surgical repair, there were decreases in testosterone levels in those who did not undergo surgical repair (Srini and

Veerachari, 2011). In another study, it was reported that varicocelectomy applied in cases of low testosterone and erectile dysfunction improved both symptoms (Comhaire and Vermeulen, 1975).

### **CONCLUSION**

Many studies have been done and are still being done to obtain definitive data on the causes and treatment of varicocele. It is known that the share of varicocele in male infertility is not very low. In the literature review, it was emphasized that varicocele causes disruptions in testosterone biosynthesis and varicocele repair has beneficial effects on testosterone levels. The potential benefit of varicocele repair is known, especially in older men with low testosterone levels. Varicocele repair has no significant effect on testosterone in men with normal or above normal testosterone levels. However, in such a case, varicocelectomy can be performed with the desire to increase fertility. As a matter of fact, it has been reported that there are improvements in both hormonal parameters, sperm parameters and testicular structure after varicocelectomy.

## REFERENCES

- Abdel-Meguid, T. A., Al-Sayyad, A., Tayib, A., & Farsi, H. M. (2011). Does varicocele repair improve male infertility? An evidence-based perspective from a randomized, controlled trial. *European Urology*, 59(3), 455–61.
- Abdel-Meguid, T. A., Farsi, H. M., Al-Sayyad, A., Tayib, A., Mosli, H. A., & Halawani, A.H. (2014). Effects of varicocele on serum testosterone and changes of testosterone after varicocelectomy: a prospective controlled study. *Urology*, 84(5), 1081–7.
- Agarwal, A., Deepinder, F., Cocuzza, M., Agarwal, R., Short, R. A., Sabanegh, E., & Marmar, J. L. (2007). Efficacy of varicocelectomy in improving semen parameters: new meta-analytical approach. *Urology*, 70(3), 532–8.
- Alkaram A, & McCullough A. (2014). Varicocele and its effect on testosterone: implications for the adolescent. *Translational Andrology and Urology*, 3(4), 413–7.
- Amelar, R. D., & Dubin, L. (1987). Right varicocelectomy in selected infertile patients who have failed to improve after previous left varicocelectomy. *Fertility and Sterility*, 47(5), 833–837.
- Andò, S., Giacchetto, C., Colpi, G., Beraldi, E., Panno, M. L., Lombardi, A., & Sposato, G. (1984). Physiopathologic aspects of Leydig cell function in varicocele patients. *Journal of Andrology*, 5(3), 163–70.
- Andres, T. E., Trainer, T. D., & Lapenas, D. J. (1981) Small vessel alteration in testis of infertile men with varicocele. *American Journal of Clinical Pathology*, 76(4), 378–84.
- Bedrak, E., Samiloff, V., Sod-Moriah, U. A., & Goldberg, S. (1971). Synthesis of androgens in vitro by testes of rats acclimatized to a hot environment. *Journal of Endocrinology*, 51(3), 489-98
- Benoff, S., & Gilbert, B. R. (2001). Varicocele and male infertility: part I. Preface. *Human Reproduction Update*. 7(1). 47–54.
- Cayan, S., Kadioglu, A., Orhan, I., Kandirali, E., Tefekli, A., & Tellaloglu, S. (1999). The effect of microsurgical varicocelectomy on serum follicle stimulating hormone, testosterone and free testosterone levels in infertile men with varicocele. *BJU International*, 84(9), 1046–1049.
- Çayan, S., Orhan, İ., Akbay, E., & Kadioğlu, A. (2019). Systematic review of treatment methods for recurrent varicoceles to compare post-treatment sperm parameters, pregnancy and complication rates. *Andrologia*, 51(11), e13419.
- Chakraborty, J., Hikim, A. P., & Jhunjhunwala, J. S. (1985) Stagnation of blood in the microcirculatory vessels in the in the testes of men with varicocele. *Journal of Andrology*, 6(2), 117–26.
- Comhaire, F., & Vermeulen, A. (1975). Plasma testosterone in patients with varicocele and sexual inadequacy. *Journal of Clinical Endocrinology and Me-*

*tabolism*, 40(5), 824–9.

- de Los Reyes, T., Locke, J., & Afshar, K. (2017). Varicoceles in the pediatric population: Diagnosis, treatment, and outcomes. *Canadian Urological Association Journal*, 11(1-2Suppl1), 34–39.
- Dubin L, & Amelar RD. (1971). Etiologic factors in 1294 consecutive cases of male infertility. *Fertility and Sterility*, 22(8), 469–74.
- Esteves, S. C., & Agarwal, A. (2016). Afterword to varicocele and male infertility: Current concepts and future perspectives. *Asian Journal of Andrology*, 18(2), 319–22.
- Ficarra, V., Crestani, A., Novara, G., & Mirone, V. (2012). Varicocele repair for infertility: what is the evidence? *Current Opinion in Urology*, 22(6), 489–94.
- Fisch, H., & Hyun, G. (2012). Varicocele repair for low testosterone. *Current Opinion in Urology*, 22(6), 495–8.
- Fussell, E. N., Lewis, R. W., Roberts, J. A., Harrison, R. M. (1981). Early ultrastructural findings in experimentally produced varicocele in the monkey testis. *Journal of Andrology*, 2(2), 111-19.
- Harrison, R. M., Lewis, R. W., Roberts, J. A. (1983). Testicular blood flow and fluid dynamics in monkeys with surgically induced varicoceles. *Journal of Andrology*, 4(4), 256-60.
- Gomes, W. R., Butler, W. R., & Johnson, A. D. (1971). Effect of elevated ambient temperature on testis and blood levels and in vitro biosynthesis of testosterone in the ram. *Journal of Animal Science*, 33(4), 804–7.
- Gorelick, J. I., & Goldstein, M. (1993). Loss of fertility in men with varicocele. *Fertility and Sterility*, 59(3), 613–616.
- Green, K. F., Turner, T. T. & Howard, S. S. (1984). Varicocele: reversal of the testicular blood flow and temperature effects by varicocele repair. *Journal of Urology*, 131(6), 1208–1211.
- Hadziselimovic, F., Leibundgut, B., Da Runga, D., Buser, M. W. (1986). The value of testicular biopsy in patients with varicoceles. *Journal of Urology*, 135(4), 707-10.
- Haider, K. S., Haider, A., Doros, G., Traish, A. (2018). A Long-term testosterone therapy improves urinary and sexual function, and quality of life in men with hypogonadism: results from a Propensity Matched Subgroup of a Controlled Registry Study. *Journal of Urology*, 199(1): 257–265.
- Henriksén, K., Hakovirta, H., & Parvinen, M. (1995). Testosterone inhibits and induces apoptosis in rat seminiferous tubules in a stage-specific manner: in situ quantification in squash preparations after administration of ethane dimethane sulfonate. *Endocrinology*, 136(8), 3285–3291.
- Hsiao, W., Rosoff, J. S., Pale, J. R., Greenwood, E. A., & Goldstein, M. (2011). Older age is associated with similar improvements in semen parameters

- and testosterone after subinguinal microsurgical varicocelectomy. *Journal of Urology*, 185(2), 620–5.
- Hudson, R. W., Crawford, V. A., & McKay, D. E. (1981). The gonadotropin response of men with varicoceles to a four-hour infusion of gonadotropin-releasing hormone. *Fertility and Sterility*, 36(5), 633–637.
- Hudson, R. W., Perez-Marrero, R. A., Crawford, V. A., & McKay, D. E. (1985). Hormonal parameters of men with varicoceles before and after varicocelectomy. *Fertility and Sterility*, 43(6), 905–910.
- Jensen, C. F. S., Østergren, P., Dupree, J. M., Ohl, D. A., Sønksen, J., & Fode, M. (2017). Varicocele and male infertility. *Nature Reviews Urology*, 14(9), 523–533.
- Kazama, T. (1995). Effect of experimental varicocele on rat Leydig cell function. *Nihon Hinyōkika Gakkai Zasshi*, 86(2), 308–315.
- Kendirci, M., Boylu, U., & Miroglu, C. (2003). Andrologic surgery of the 15th century. In Cerrahiyetü'l Haniye. The history of Male-Female Sexuality and fertility in Asia Minor (Today's Turkey). (Eds: Kendirci, M., Kadioglu, A., Miroglu, C.), Istanbul, 127–148.
- Khosravanian, N., Razi, M., Farokhi, F., & Khosravanian, H. (2014). Testosterone and vitamin E administration up-regulated varicocele-reduced Hsp70-2 protein expression and ameliorated biochemical alterations. *Journal of Assisted Reproduction and Genetics*, 31(3), 341–54.
- Kim, Y. C., & Choi, H. K. (1992). Clinical value of scrotopenogram for evaluating varicocele and erectile dysfunction. *Urology*, 39(2), 150–6
- Li, F., Yamaguchi, K., Okada, K., Matsushita, K., Ando, M., Chiba, K., Yue, H., & Fujisawa, M. (2012) Significant improvement of sperm DNA quality after microsurgical repair of varicocele. *Systems Biology in Reproductive Medicine*, 58(5), 274–7
- Lundy, S. D., & Sabanegh Jr, E. S. (2017). Varicocele management for infertility and pain: A systematic review. *Arab Journal of Urology*, 16(1), 157–170.
- Luo, D. Y., Yang, G., Liu, J. J., Yang, Y. R., & Dong, Q. (2011). Effects of varicocele on testosterone, apoptosis and expression of StAR mRNA in rat Leydig cells. *Asian Journal of Andrology*, 13(2), 287–291.
- Mehta, A., & Goldstein, M. (2013). Microsurgical varicocelectomy: a review. *Asian Journal of Andrology*, 15(1), 56–60.
- Mostafa, T., Anis, T. H., El-Nashar, A., Imam, H., & Othman, I. A. (2001). Varicocelectomy reduces reactive oxygen species levels and increases antioxidant activity of seminal plasma from infertile men with varicocele. *International Journal of Andrology*, 24(5), 261–265.
- Nagao, R. R., Plymate, S. R., Berger, R. E., Perin, E. B., & Paulsen, C. A. (1986): Comparison of gonadal between fertile and infertile men with varicocele. *Fertility and Sterility*, 46(5), 930–3.

- Nieschlag, E., Behre, H. M., Meschede, D., & Kamischke, A. (1997). Disorders at the testicular level. In: *Andrology, Male Reproductive Health and Dysfunction*, chapter 8, 133–157.
- Pirke, K. M., Vogt, H. J., Sintermann, R., & Spyra, B. (1983). Testosterone in peripheral plasma, spermatic vein and in testicular tissue under basal conditions and after HCG stimulation in patients with varicocele. *Andrologia*, 15(6), 637–41.
- Pryor, J. L., & Howards, S. S. (1987). Varicocele. *Urologic Clinics of North America*, 14(3), 499–513.
- Rotker, K., & Sigman, M. (2016). Recurrent varicocele. *Asian Journal of Andrology*, 18(2), 229–233.
- Samplaski, M. K., Loai, Y., Wong, K., Lo, K. C., Grober, E. D., & Jarvi, K. A. (2014). Testosterone use in the male infertility population: prescribing patterns and effects on semen and hormonal parameters. *Fertility and Sterility*, 101(1), 64–69.
- Saylam, B., Çayan, S., & Akbay, E. (2020). Effect of microsurgical varicocele repair on sexual functions and testosterone in hypogonadal infertile men with varicocele. *Aging Male*, 23(5), 1366–1373.
- Schiff, I., Wilson, E., Newton, R., Shane, J., Kates, R., Ryan, K. J., & Naftolin, F. (1976). Serum luteinizing hormone, folliclestimulating hormone and testosterone responses to gonadotrophin-releasing factor in males with varicoceles. *Fertility and Sterility*, 27(9), 1059–1061.
- Schlegel, P. N., Goldstein, M. (2011). Alternate indications for varicocele repair: non-obstructive azoospermia, pain, androgen deficiency and progressive testicular dysfunction. *Fertility and Sterility*, 96(6), 1288–93.
- Segenreich, E., Shmueli, H., Singer, R. & Servadio, C. (1986). Andrological parameters in patients with varicoceles and fertility disorders treated by high ligation of the left spermatic vein. *International Journal of Fertility*, 31(3), 200–203.
- Shiraishi, K., Takihara, H., & Matsuyama, H. (2010). Elevated scrotal temperature, but not varicocele grade, reflects testicular oxidative stress-mediated apoptosis. *World Journal of Urology*, 28(3), 359–64.
- Sofikitis, N., & Miyagawa, I. (1994). Bilateral effect of unilateral varicocele on testicular metabolism in the rabbit. *International Journal of Fertility and Menopausal Studies*, 39(4), 239–47.
- Srini, V. S., & Veerachari, B. S. (2011). Does varicocelectomy improve gonadal function in men with hypogonadism and infertility? Analysis of a prospective study. *International Journal of Endocrinology*. 2011, 916380.
- Tulloch, W. S. (1955). Varicocele in subfertility; results of treatment. *British Medical Journal*, 2(4935), 356–8.
- Whelan, P., & Levine, L. (2016). Effects of varicocelectomy on serum testosterone

one. *Translational Andrology and Urology*, 5(6), 866–76.

Zohdy, W., Ghazi, S., & Arafa, M. (2011). Impact of varicocelectomy on gonadal and erectile functions in men with hypogonadism and infertility. *Journal of Sexual Medicine*, 8(3), 885–93.





## **CHAPTER 11**

### **EFFECTS OF THE PANDEMIC ON MOTHER-INFANT ATTACHMENT: A LITERATURE REVIEW<sup>1</sup>**

*Gizem ÇITAK<sup>2</sup>, Özlem DURAN AKSOY<sup>3</sup>*

---

1 This study was presented as an oral presentation at the 1st International National Sivas Midwifery Congress.

2 Instructor, Tokat Gaziosmanpaşa University, Faculty of Health Sciences, Department of Midwifery, Orcid: 0000-0002-5484-2233

3 Assoc. Prof. Dr. Sivas Cumhuriyet University Faculty of Health Sciences Department of Midwifery, Orcid: 0000-0003-0843-5589

## Introduction

A pandemic is a global health crisis that paves the way for many physiological, psychological, and social health problems. The COVID-19 pandemic, which first emerged in China and spread all over the world, affected people of all ages negatively (Lee et al., 2021). The lack of a specific treatment protocol and negative thoughts about the protection of vaccines have driven people into despair. The consequences of the pandemic, such as having to stay at home for a long time, experiencing losses, staying away from social relations, and future anxiety, have brought along psychosocial problems (Li et al., 2020). The pandemic has led to many negative consequences, such as increased stress, anxiety, mourning, quarantine rules put into effect, lockdowns in many countries, access to social life only through the virtual environment, concerns about the economic future of the country, having to wear a mask, and the deterioration of people's social relations. These results have a psychological effect on individuals (Li et al., 2020). The impact is particularly higher in groups at risk (Sousa et al., 2020).

The future effects of the pandemic on the general population could have negative psychological consequences. It will take some time for the impact of the pandemic on mental health to be recognized and fully visible (Sousa et al., 2020). Women who have recently given birth are at the forefront of the groups at risk. The pregnancy and postpartum periods are one of the riskiest periods when mental disorders may occur (Carter & Kostaras, 2005). Although the effects of the pandemic on pregnancy, childbirth, and the postpartum period are not fully known, it is stated that women in this period should be considered among more vulnerable groups. Psychological changes are seen more frequently, especially with the arrival of a new member of the family after birth (Arslan & Uzun, 2008). The quarantine measures taken affect secure maternal attachment and breastfeeding adversely, especially for newborns and their mothers.

The mother's perception of the baby makes up the basis of mother-infant attachment after birth. When this attachment is positive, it affects the future lives of babies positively and paves the way for healthy adulthood (Adam et al., 2004). In the literature, it is stated that incompatibility between couples, inadequate social support, and living in a stressful environment has negative effects on mother-infant attachment (Brockington, 2004; Callister et al., 2011; Alan & Ege, 2013). Stressful processes for the mother, such as their separation from their infants due to the mother's infection or being a suspected case during the pandemic process, not getting enough social support from the family, lack of skin-to-skin contact with their baby, and inability to breastfeed effectively, affect their attachment with their infant negatively (Stuebe, 2020; Vincenzo & Hughes, 2020). In this process, it is recommended that midwives, who are closest to wom-

en, access up-to-date information from right sources and maintain secure maternal attachment and breastfeeding. Midwives play a key role in mother-infant attachment. They must ensure the sustainability of care with tele-midwifery services, especially in this period when contact among people is reduced.

### **The COVID-19 pandemic**

The pandemic, which started in Wuhan, China in 2019 and affected the whole world, has caused many changes in business, family, and education life, especially in health (Kabasakal & Aktaş, 2021). The most typical symptoms of COVID-19 include high fever, dry cough, and fatigue (Johns Hopkins, 2020). More rarely seen symptoms are nasal congestion, headache, general body pain, loss of sense of taste and smell, diarrhea, redness in the body, and color changes in the fingers (WHO, 2020). Psychosocial problems have emerged as well as physiological symptoms.

Quarantine measures taken to protect individuals' health during the pandemic process have caused individuals to experience very different changes over time. It has been stated that a quarantine period of longer than 10 days may affect individuals' psychological well-being and cause some psychological problems (Sousa et al., 2020). Perceptions and coping mechanisms of individuals staying at home regarding the pandemic process have been adversely affected. It is known that family characteristics affect the individual's psychological well-being and that there is a relationship between the individual's perceived social support and their psychological resilience (Cullen et al., 2020).

### **The Pandemic and Its Psychological Effects**

Existing literature shows that exposure to disaster is associated with psychosocial problems. Studies have shown that natural disasters, such as floods, hurricanes, earthquakes, or certain collective traumatic events such as wars or pandemics may pose a threat to mental health (Fergusson et al., 2014). Stress, inadequate self-care, medical insecurity, depression, and suicidal tendencies increased in past pandemics (Duan & Zhu, 2020).

The pandemic has become a dangerous event that threatens the physical, mental, and social health of individuals since its declaration. The security measures taken due to the pandemic have negatively affected the socialization and interpersonal communication of individuals. In addition, it is predicted that it may affect mental health in the future (Calcia et al., 2016). Worries about when the epidemic will end increase panic in people and cause stress. In addition, panic, fear of losing health, and loneliness cause many psychosocial problems. It is also important to be alert to certain psychiatric conditions that may arise. Moreover, the condition of people with psychiatric problems also gets worse with the pandemic (Duan & Zhu, 2020).

In studies on the COVID-19 pandemic, it has been found that mental disorders are more common in women than in men (Liu et al., 2020). This is an important criterion showing that women should be handled within more vulnerable groups.

### **The Pandemic and Its Effect on The Perinatal Period**

The pandemic, which has caused many negative effects globally, has also affected pregnant and postpartum women. Although pregnancy is perceived as a pleasant journey, many women have experienced some mental problems during this process (Altay & Arıkan, 2021). In addition, women in this period are more sensitive to emotional problems, and together with intense parenting feelings, they are at increased risk. Unnoticed or untreated mental disorders can also affect infants and other family members (The National Institute for Health and Care Excellence, 2020).

In addition to the life changes and anxiety brought about by becoming a parent, the quarantine measures taken due to the pandemic, anxiety, fear of contamination, and uncertainty affect women's mental health negatively and cause panic (Grigoriadis et al., 2018; Riyad et al., 2019). This shows that pregnant and postpartum women have been vulnerable to psychiatric diseases during the COVID-19 pandemic.

Although preliminary data from China shows that there is no increased risk of mortality and morbidity among pregnant women compared to the general population, the transformation of the disease into a global pandemic has indicated that this risk may increase (Chen et al., 2020). Disturbances that may occur due to the effect of the pandemic in the postpartum period are multifaceted, and it will be useful to classify them.

**Psychology:** Pregnancy is a period in which many psychological changes occur in a short time. Decreased access to healthcare services due to the pandemic, fear of contracting the disease, quarantine measures and restrictions, increasing uncertainty, losses, and changes in traditional perinatal care can cause a psychological crisis. Psychological problems in this period can be listed as follows: negative attitudes towards the baby, inadequate mother-infant attachment, stress caused by uncertainty, perinatal mood disorder, and anxiety disorders. In addition, psychological problems related to COVID-19 include adaptation to the new normal, mourning, losses, psychological effects of social isolation, and an increase in pre-existing mental health problems (Diamond et al., 2020).

**Social:** Social isolation affects a person psychosocially. Changes in traditional care, particularly during pregnancy, cause additional concerns for the person. Therefore, the restriction in this area during the puerperium, when social support is needed, brings along psychosocial problems.

Some changes have occurred in hospital births with the pandemic. Psychosocial experiences, such as lack of personal care during birth, poor communication, fear that the baby will not be healthy, loneliness, and lack of contact, are some of them (Diamond et al., 2020).

**Biological:** Many biological changes occur during the development of the fetus and its preparation for birth in pregnancy (Pillay et al., 2016). Some respiratory changes during pregnancy may increase susceptibility to COVID-19 and make the pregnant woman more vulnerable. Physiological problems in pregnancy can be listed as complications, such as hormone changes, immune system suppression, and sleep problems. With the pandemic, these problems are fever and dry cough, uncertain biological risks of infecting the baby, risk of premature birth, fear of death, and recurrence of pre-existing diseases (Diamond et al., 2020).

In a study, it was determined that there was an increase in depressive symptoms and anxiety levels in women who gave birth during the pandemic period. Therefore, it was stated that more sensitive behaviors should be shown and that emotional well-being should be emphasized during this period (Zanardo et al., 2020). Some studies in the literature have listed the problems experienced during pregnancy during the pandemic as attitudes toward the infant, attachment to it, stress caused by uncertainty, perinatal mood, and anxiety disorders (Diamond et al., 2020; Brooks et al., 2020).

Changes in hospital births due to the pandemic cause psychosocial experiences, such as lack of personal care during birth, poor communication, and fear that the baby will not be healthy (Diamond et al., 2020). In addition, early postnatal discharge and social distancing recommendations in this process can be shown as psychosocial stress factors for parents due to loneliness (National Perinatal Association, 2020).

### **Mother-Infant Attachment-Maternal Attachment**

Mother-infant attachment, which starts with the intrauterine period and continues throughout the postpartum period, is the most valuable attachment type (Nacar & Gökkaya, 2019). The arrival of a new member of the family is an important period that affects both relationships and lifestyle (Yıldızhan, 2017). With these changes, new roles and responsibilities can make up a challenging period for the mother or expectant mother. Maternal attachment is a concept that affects an individual's whole life. Initiating this attachment safely and effectively affects both the mother's adjustment to her role and the development of the baby's sense of trust positively (Nacar & Gökkaya, 2019). The mother-infant attachment process is fragile, and in case of separation that occurs in this process, neurodevelopmental problems may emerge in the following years (Altay & Arıkan, 2021).

Secure attachment is associated with responsiveness, acceptance, collaboration, and accessibility because the most important aspect of maternal behavior is the infant's safety-anxiety dimension. Past experiences affect the mother in this process. Therefore, maternal attachment representations may limit the processing and expression of emotions during mother-infant interactions (Alhusen, 2008). Mothers who value attachment relationships and see the experiences in these relationships as effective experience a more secure attachment with their babies. Secure attachment in the mother affects the baby and brings a more harmonious process (Milligan et al., 2003). Sometimes mothers find it difficult to start a relationship with their infants due to environmental factors such as stress, and such failure can have long-term effects on the baby.

### **The Pandemic and Its Effects on Mother-Infant Attachment**

Considering that the pandemic period is a major source of stress in itself, it is predicted that it will affect the mother-infant attachment process. In a study, it was stated that the anxiety experienced by the mother affected the mother-infant attachment and caused long-term results in the infant (Brockington, 2004). For a healthy attachment, mothers need to receive support for their adjustment to the motherhood role. Support from acquaintances has an important place in pregnancy and the postpartum period. Having harmony and support with the spouse ensures that the mother has fewer problems, whereas marital incompatibility, inadequate social support, and stressful life conditions cause her to have more psychiatric problems (Callister et al., 2011). Incompatibility between mother and father, lack of social security, health problems, lack of social support, anxiety, trauma, disasters, and social events have also been observed to negatively affect mother-infant attachment (Alan & Ege, 2013).

Mother-infant attachment includes skin-to-skin contact, the kangaroo method, breastfeeding, and sharing the same room (Morre et al., 2007). The World Health Organization (WHO) created some interim guidelines on the management of pregnancy and childbirth in the context of the COVID-19 pandemic. However, recommendations have varied continuously due to the lack of robust evidence (WHO, 2020). Within the scope of these precautions, it has been stated that infected or suspicious mothers should not share the same room with their babies (Stuebe, 2020). This practice is risky for both the mother and the baby and has negatively affected many functions such as breastfeeding and attachment (Vincenzo & Hughes, 2020). In the course of the pandemic, the WHO stated that it was not necessary to separate mothers with suspected or diagnosed COVID-19 from their infants unless they needed hospital care, and routine care practices could be performed in this process (WHO, 2020). The United States Center for Disease Prevention and Control (CDC), on the other hand, stat-

ed that decisions for both the mother and the infant needed to be individualized. At this stage, it has been suggested that an evaluation should be made considering the test result of the mother or the infant, whether the mother has a chronic disease, the mother's breastfeeding attitude, clinical conditions, the mother's perspective on the separation from her infant, and other results that mother-infant separation may reveal (Vincenzo & Hughes, 2020).

It has been reported in the literature that there is an increase in mother-infant attachment with age (Lavender, 2011). However, in a study conducted during the pandemic period, it was observed that there was a decrease in attachment with increasing age. In the same study, it was stated that working status and family type also affected it. These results highlight the psychosocial aspects of the pandemic and reveal the effects of stress.

In addition, the number of pregnancies is a factor affecting attachment. In a study conducted during the pandemic, the attachment scores of mothers who had their first pregnancy were found to be higher than those with the third pregnancy (Kurt, 2021). In some studies conducted before the pandemic, it was found that the number of pregnancies was effective on mother-infant attachment, and it was stated that attachment was higher in the first pregnancy (Ngai et al., 2011; Cınar Ozen & Ozturk, 2014). The mother-infant attachment was found to be associated with the number of pregnancies in the pandemic similar to the literature.

In the literature, it has been stated that the mode of delivery affects mother-infant attachment (Cetisli Egelioglu et al., 2018; Kokanali et al., 2018). In the pandemic, on the other hand, the mode of delivery has been found to not affect attachment (Kurt, 2021). More studies are needed to obtain overall results.

Breastfeeding is one of the basic building blocks of mother-infant attachment. According to the results of a study conducted with COVID-positive mothers, it was stated that staying in the same room with their infants did not pose a problem as long as an appropriate hygiene environment was provided (Salvatore et al., 2020). According to the CDC, there is no virus agent in breast milk; on the contrary, there are antibodies to fight the virus (CDC, 2020). In the literature, some researchers have reported that newborns at risk of COVID should be kept in isolation for 14 days (Chen et al., 2020; Li et al., 2020). Some other researchers, on the contrary, have argued that breast milk has a protective effect and that effective breastfeeding should be initiated in this process (Salvatore et al., 2020). In a study, it was stated that separating the infant from its mother negatively affected mother-infant attachment (Fernandez et al., 2020). The WHO and some international organizations have stated that breastfeeding should be

continued after the necessary protective measures are taken (CDC, 2020; WHO, 2020).

### **The Role of Midwives in Mother-Infant Attachment in The Pandemic**

The postpartum period is a very important and complex process for both the mother and the infant. Several factors affect the realization of attachment in this process. The COVID-19 pandemic is one of these factors. To ensure a secure mother-infant attachment, midwives should be able to anticipate potential problems and provide effective counseling services (Yıldızhan, 2017). It is important to use evidence-based practices as a guide in this process. For this purpose, it is extremely important that the mother and the infant share the same room, breastfeeding is started and continued at an early stage, the mother's questions are answered, and that her self-confidence is ensured (Köse et al., 2013).

As before the pandemic, midwives are the health professionals who are closest to mothers and infants during the pandemic, and they have a critical role in mother and infant health. They have many responsibilities, such as providing education and consultancy on the use of protective equipment due to the pandemic, preventing the spread of infection and protection against it, and ensuring that tele-midwifery services are actively maintained in this process. Midwives, who are primarily responsible for the care of women and newborns in the postpartum period, also have an important place in mother-infant attachment (Sen Aytekin et al., 2021).

Within the scope of the COVID-19 pandemic, mother-infant attachment has faced many adverse situations. Midwives should reduce these problems as much as possible and have up-to-date knowledge and apply it (Cuvadar & Cuvadar, 2021). The mother and the infant should not be separated, breastfeeding should be continued effectively, the mother should actively participate in the care of her baby, and she should be supported. In addition, it is thought that more active use of tele-midwifery services to maintain communication and care will have positive results for the mother and the infant.



## REFERENCES

- Adam, K. E., Gunnar, R. M., & Tanaka, A. (2004). Adult Attachment, Parent Emotion And Observed Parenting Behavior: Mediator And Moderator Models. *Child Development*, 75(1); 110-122.
- Alan, H., Ege, E. (2013). The Influence Of Social Support On Maternal-Infant Attachment In Turkish Society. *Anatolian Journal of Nursing and Health Sciences*, 16(4); 234-240.
- Alhusen, L. J. (2008). A Literature Update On Maternal-Fetal Attachment. *Journal Of Obstetric, Gynecologic And Neonatal Nursing*, 37(3), 317-328.
- Altay, G., Arikan, D. (2021). Safe maternal attachment and breastfeeding in newborns during the COVID-19 pandemic. *Gumushane University Journal of Health Sciences*, 10(4): 993-999.
- Arslan, F., Uzun, S. (2008). Investigation of Nurse's Postnatal Education and Counseling Services. *Turkey Clinics*, 28;736-742.
- Brockington, I. (2004). Postpartum Psychiatric Disorders. *Lancet*, 363; 303-310.
- Brooks, K. S., Webster, K. R., Smith, E. L., Woodland, L., Wessely, S., Greenberg, N., et al. (2020). The Psychological Impact Of Quarantine And How To Reduce It: Rapid Review Of The Evidence. *Lancet*, 14;395(10227); 912-920.
- Calcia, A. M., Bonsall, R. D., Bloomfield, S. P., Selvaraj, S., Barichello, T., & Howes, D. O. (2016). Stress And Neuroinflammation: A Systematic Review Of The Effects Of Stress On Microglia And The Implications For Mental Illness. *Psychopharmacology*, 233; 1637-1650.
- Callister, C. L., Beckstrand, L. R., Corbett, C. (2011). Postpartum Depression And Help-Seeking Behaviors In Immigrant Hispanic Women. *Journal Of Obstetric Gynecologic Neonatal Nursing*, 40(4); 440-449.
- Carter, D., Kostaras, X. (2005). Psychiatric Disorders In Pregnancy. *BC Medical Journal*, 47(2); 96-99.
- Breastfeeding". Accessed at: <https://www.cdc.gov/breastfeeding/breastfeeding-special-circumstances/maternal-or-infant-illnesses/covid-19-and-breast-feeding.html> (Accessed on 07.12.2022).
- Cetisli Egelioglu, N., Arkan, G., Top, D. E. (2018). Maternal Attachment And Breastfeeding Behaviors According To Type Of Delivery In The Immediate Postpartum Period. *Rev. Assoc. Med. Bras*, 64(2); 164-169.
- Chen, H., Guo, J., Wang, C., Luo, F., Yu, X., Zhang, W., et al. (2020). "Clinical Characteristics and Intrauterine Vertical Transmission Potential of COVID-19 Infection In Nine Pregnant Women: A Retrospective Review of Medical Records". *Lancet*, 395(10226), 809-815.
- Cinar Ozen, I., Ozturk, A. (2014). The Effect Of Planned Baby Care Education Given To Primiparous Mothers On Maternal Attachment And Self-Confi-

- dence Levels. *Health Care For Women International*, 35(3); 320-333.
- Cullen, W., Gulati, G., Kelly, B. D. (2020). Mental health in the Covid-19 pandemic. *QJM: An International Journal of Medicine*, 113(5), 311-312. doi: <https://doi.org/10.1093/qjmed/hcaa110>.
- Çuvadar, Y., Çuvadar, A. (2021). Covid-19 and Care in the Newborn. *Journal Of Health Professionals Research*, 3(1), 38-41.
- Diamond, M. R., Brown, S. K., Miranda, J. (2020). Impact Of Covid-19 On The Perinatal Period Through A Biopsychosocial Systemic Framework . *Contemporary Family Therapy*, 42; 205-216.
- Duan, L., Zhu, G. (2020). Psychological Interventions For People Affected By The Covid-19 Epidemic. *The Lancet Psychiatry*, 7(4); 300-302.
- Fergusson, M. D., Horwood, L. J., Boden, M. J., Mulder, T. R. (2014). Impact Of A Major Disaster On The Mental Health Of A Well Studied Cohort. *JAMA Psychiatry*, 71(9); 1025-1031.
- Fernández-Carrasco, F.J., Vázquez-Lara, J.M., González-Mey, U., Gómez-Salgado, J., Parrón-Carreño, T., Rodríguez-Díaz, L. (2020). “Coronavirus Covid-19 Infection and Breastfeeding: An Exploratory Review”. *Revista Espanola de Salud Publica*, 94, e202005055.
- Grigoriadis, S., Graves, L., Peer, M., Mamisashvili, L., Tamlinson, G., Vigod, N. S., et al. (2018). Maternal Anxiety During Pregnancy And The Association With Adverse Perinatal Outcomes: Systematic Review And Meta-Analysis. *J. Clin. Psychiatry*, 79(5); 17r12011.
- Health: Clinical Management And Service Guidance. *Clinical Guideline* , <https://www.nice.org.uk/guidance/cg192>.
- Johns Hopkins Medicine. (2020). Coronavirus COVID-19 (SARS-CoV-2). [https://www.hopkinsguides.com/hopkins/view/Johns\\_Hopkins\\_ABX\\_Guide/540747/all/Coronavirus\\_COVID\\_19\\_\\_SARS\\_CoV\\_2\\_](https://www.hopkinsguides.com/hopkins/view/Johns_Hopkins_ABX_Guide/540747/all/Coronavirus_COVID_19__SARS_CoV_2_) (Access Date: 09.12.2022).
- Kabasakal, Z., Aktaş, A. (2021). Investigation of Social Support and Family Climate Perceptions of Individuals in the Covid-19 Pandemic Process. *Western Anatolian Journal of Educational Sciences*, 12(1); 145-157.
- Kokanali, D., Ayhan, S., Devran, A., Kokanali, K. M., Taşçı, Y. (2018). The Effect of Cesarean Delivery on Postpartum Depression and Maternal Attachment. *Journal of Contemporary Medicine*, 8(2); 148-152.
- Köse, D, Çınar, N., Altınkaynak, S. (2013). “The Bonding Process of the Newborn with the Mother and Father”. *Journal of Continuing Medical Education*, 22(6), 239-45.
- Kurt, A. (2021). The Effect of Perinatal Anxiety and OCD on Maternal Attachment in Women Who Give Birth During the Covid-19 Period. Near East University Graduate Education Institute. Master Thesis. Nicosia.

- Lee, T.Y., Zhong, Y., Zhou, J., He, X., Kong, R., Ji, J. (2021). The Outbreak Of Coronavirus Disease In China: Risk Perceptions, Knowledge And Information Sources Among Prenatal And Postnatal Women. *Women And Birth*, 34(3); 212-218 DOI: 10.1016/j.wombi.2020.05.010.
- Li, F, Feng, Z.C., Shi, Y. (2020). “Proposal for Prevention and Control of The 2019 Novel Coronavirus Disease in Newborn Infants”. *Archives of Disease in Childhood. Fetal and Neonatal Edition*, 105(6), 683–684.
- Li, S., Wang, Y., Xue, J., Zhao, N., Zhu, T. S. (2020). The Impact Of Covid-19 Epidemic Declaration On Psychological Consequences: A Study On Active Weibo Users. *International Journal Of Environmental Research And Public Health*, 17(6); 2032.
- Liu, N., Zhang, F., Wei, C., Jia, Y., Shang, Z., Sun, L., et al. (2020). Prevalence And Predictors Of PTSS During Covid-19 Outbreak In China Hardest-Hit Areas: Gender Differences Matter. *Psychiatry Research*, 287: 112921.
- Milligan, K., Atkinson, L., Trehub, E. S., Benoit, D. ve Poulton, L. (2003). Maternal Attachment And The Communication Of Emotion Through Song. *Infant Behavior And Development*, 26, 1-13.
- Moore, E.R, Anderson, G.C, Bergman, N. (2007). “Early Skin-To-Skin Contact for Mothers and Their Healthy Newborn Infants”. *The Cochrane Database of Systematic Reviews*, (3), CD003519.
- Nacar, E.H. Gökkaya, F. (2019). “A Review on Attachment and Maternal Attachment”. *Cyprus Turkish Journal of Psychiatry and Psychology*, 1(1), 50-56.
- National Perinatal Association. (2020). Mothers With Covid-19 And Their Newborn Infants. *National Association of Neonatal Nurses*, [http://www.nationalperinatal.org/resources/Documents/COVID-19/COVID\\_19\\_NPA%20and%20NANN.pdf](http://www.nationalperinatal.org/resources/Documents/COVID-19/COVID_19_NPA%20and%20NANN.pdf)
- National Institute For Health And Care Excellence (2020). Antenatal And Postnatal Mental
- Ngai, W.F., Chan, C. W., Holroyd, E. (2011). Chinese Primiparous Women’s Experiences
- Of Early Motherhood: Factors Affecting Maternal Role Competence. *Journal Of Clinical Nursing*, 20(9-10); 1481-1489.
- Pillay, S.P., Piercy, N.C., Tolppanen, H., Mebazaa, A. (2016). Physiological Changes In
- Pregnancy. *Cardiovascular Journal Of Africa*, 27(2); 89-94.
- Riyad, S. F., Islam, S., East, L., Usher, K. (2019). Women’s Health-Related Vulnerabilities In Natural Disasters; A Systematic Review Protocol. *BMJ Open*, 29: 9(12);e032079.
- Salvatore, C.M., Han, J.Y., Acker, K.P., Tiwari, P, Jin, J., Brandler, M., Cangemi, C., Gordon, L., Parow, A., DiPace, J., DeLaMora, P. (2020). “Neonatal Management and Outcomes. during the COVID-19 Pandemic: an Obser-

- vation Cohort Study”. *The Lancet Child & Adolescent Health*, 4(10), 721-727.
- Sousa, D. A., Mohandas, E., Javed, A. (2020). Psychological Interventions During Covid-19: Challenges For Low And Middle Income Countries. *Asian Journal Of Psychiatry*, 51;102128.
- Stuebe A. (2020). “Should Infants Be Separated from Mothers with COVID-19? First, Do No Harm”. *Breastfeeding Medicine*, 15(5), 351-352.
- Şen Aytakin M, Yılar Erkek Z, Kahraman A. Midwifery care for the protection of pregnant women, newborns and healthcare personnel in labor during the COVID-19 pandemic. *Journal of Midwifery and Health Sciences*. 2021;4(2): 176-88.
- Vincenzo, B. and Hughes, B. (2020). “Coronavirus disease 2019 (COVID-19): Pregnancy issues”. Erişim adresi: <https://www.uptodate.com/contents/coronavirus-disease-2019-covid-19-pregnancy-issues-and-antenatal-care>. (Accessed on 01.12.2022).
- World Health Organization. (2020). “Coronavirus Disease (COVID-19) Pandemic”. Erişim adresi: [https://www.who.int/emergencies/diseases/novel-coronavirus-2019?gclid=EAIaIQobChMIw77zqoys6QIVA7DtCh0icga6EAAAYASAAEgIGCfD\\_BwE](https://www.who.int/emergencies/diseases/novel-coronavirus-2019?gclid=EAIaIQobChMIw77zqoys6QIVA7DtCh0icga6EAAAYASAAEgIGCfD_BwE) (Accessed on 01.12.2022).
- World Health Organization. (2020). “Coronavirus Disease (COVID-19): Pregnancy and Childbirth”. <https://www.who.int/news-room/q-a-detail/coronavirus-disease-covid-19-pregnancyand-childbirth> (Accessed on 09.12.2022).
- Yıldızhan, E. (2017). “Attachment Theory and An Overview of Attachment Disorders”. *Anatol Clin*, 22, 66-72.
- Zanardo, V., Manghina, V., Gilberti, L., Vettore, M., Severino, L., Straface, G. (2020). Psychological Impact of Covid-19 Quarantine Measures In Northeastern Italy On Mothers In The Immediate Postpartum Period. *International Journal Of Gynecology Obstetrics*, 1-5, <https://obgyn.onlinelibrary.wiley.com/doi/10.1002/ijgo.13249>.



## **CHAPTER 12**

### **THE EFFECT OF EXERCISE ON INFLAMMATION**

*Cemre AYDEĐER<sup>1</sup>, Hüseyin Avni EROĐLU<sup>2</sup>*

---

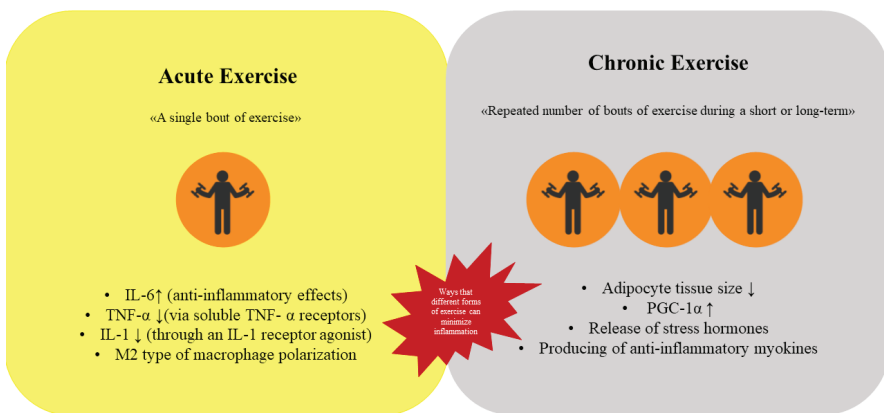
1 Research Assistant Çanakkale Onsekiz Mart University, Medicine Faculty,  
Department of Physiology Email: cemre.ayd@hotmail.com.tr ORCID: 0000-  
0003-1654-6406

2 Associate Professor Çanakkale Onsekiz Mart University, Medicine Faculty,  
Department of Physiology Email: haeroglu@comu.edu.tr ORCID: 0000-0002-  
1040-3255

Inflammation is defined as an environmental response by activated macrophages, which include chemokines, cytokines, and other molecules. It could be acute or chronic. These two different types of responses are characterized by different pathways. Acute inflammation is related to a process that includes vascularity, the immune system, and cells existing in the injured area. Also, it resulted in some situations such as physical injury, infection, etc. Chronic inflammation, on the other hand, causes tissue damage as a result of the inflammatory process. Also, there are some progressive changes in the immune cells. Long-term infections and autoimmune diseases are not unrelated to each other. In consequence of investigations, it was determined that inflammation is connected with a lot of chronic diseases, like ischemic cardiovascular diseases, stroke, chronic obstructive pulmonary disease, Alzheimer's disease, and type 2 diabetes mellitus (Woods, Vieira, and Keylock 2009).

Exercise is a subtype of physical activity that encompasses all movements that are performed in a systematic and rhythmic manner. Many of chronic diseases is stem from lack of physical activities. Furthermore, physical activities and exercise are used as a modality for preventing and treating diseases (Booth, Roberts, and Laye 2012).

On the body, exercise has a variety of impacts. Inflammation is one of them. Exercise diminishes inflammation, which is brought on by chronic illnesses, according to both epidemiological and long-term study. Furthermore, it is claimed that exercise, both short-term and long-term, affects inflammation (Metsios, Moe, and Kitas 2020; Woods et al. 2009). For these reasons, the effects of both acute and chronic exercise on inflammation are examined in this chapter using the most current information.



**Figure 1.** Anti-inflammatory effects of both chronic and acute exercise

## 1. Acute Exercise and Inflammation

Performing only one bout of exercise is identified as acute exercise (Basso and Suzuki 2017). Strikingly, acute exercise reveals anti-inflammatory effects on the body. The effect is mainly through interleukin-6 (IL-6), which is triggered by muscle contraction on the sidelines of the exercise (Metsios et al. 2020). IL-6 is the main cytokines and has a role in inflammation, tumorigenesis, metabolism, haematopoiesis, both natural and adaptive immunity (McElvaney et al. 2021). It has both anti-inflammatory and pro-inflammatory properties. IL-6, which is produced during exercise, is primarily anti-inflammatory rather than pro-inflammatory. Why IL-6 acts as an anti-inflammatory molecule is explained with some research in relation to sepsis, rheumatological problems, and musculoskeletal system diseases (Figure 2). These kinds of diseases are triggered to production of tumour necrosis factor alpha (TNF- $\alpha$ ) that is one of the essential molecules to inflammation. TNF- $\alpha$  and IL-6, when combined, increase the level of nuclear factor kappa beta (NF- $\kappa$ B), which induces some pro-inflammatory genes. Thus, inflammation continues to develop and progress (Cavaillon 2001; Liu et al. 2017; Metsios et al. 2020). Because TNF- $\alpha$  is not present during acute exercise, IL-6 does not exhibit pro-inflammatory properties. In addition to that, IL-6 is linked via pathways between the nuclear factor of activated T-cells (NFAT) and glycogen-p38 mitogen activated protein kinases (MAPK). Additionally, it indicates anti-inflammatory activities (Metsios et al. 2020; Pedersen 2017; Pedersen and Febbraio 2008). Some epidemiological studies also support it. They demonstrate that even with acute activity, the baseline value of IL-6 levels rises (Cesari et al. 2004; Colbert et al. 2004; Panagiotakos et al. 2005).

Acute exercise has anti-inflammatory benefits as well that are not IL-6-mediated. During exercise, soluble TNF- $\alpha$  receptors, which are natural TNF- $\alpha$  inhibitors, are produced. Furthermore, the activity of IL-1, one of the most important cytokines in inflammation, decreases with the production of IL-1 receptor agonists (IL-1Ra). TNF- $\alpha$  and IL-1, the main regulators of the inflammatory response, are rendered ineffective as a result of these. As a result, cascades initiated by these two cytokines have been shut down, and the inflammation is under control (Cavaillon 2001; Metsios et al. 2020; Scheller et al. 2011). Various more cytokines are also released during acute exercise in addition to these. Table 1 lists some of these cytokines' activities and their state during exercise (Docherty et al. 2022).

Another anti-inflammatory effect of acute exercise is on macrophages. In terms of inflammatory characteristics, macrophage activation is divided into two categories: classic and alternative. Classical activation results in the formation of M1 proinflammatory macrophages. So, some of pro-inflammatory cytokines such as TNF- $\alpha$ , IL-6, IL-12 and IL-1 $\beta$  are

produced. Rising cytokine levels exacerbate inflammation. On the other hand, in alternative activation, it is activated in M2 macrophages. They have anti-inflammatory species. So, this polarisation results with production of some anti-inflammatory molecules including Transforming growth factor beta (TGF- $\beta$ ) and IL-10. This means that inflammation is reduced by M2 macrophages. When acute exercise activated macrophages in the muscles, it ensured the polarization of M2 type macrophages rather than M1 type macrophages. The varying cytokine profile causes this effect. In these ways, acute exercise supplies anti-inflammatory activity (Kolliniati et al. 2022; Metsios et al. 2020).

Numerous research has looked into how acute exercise affects inflammation. According to this research, depending on the bodily system, acute exercise decreases inflammation in different ways. Dimitrov et al. (2017) conducted a study involving 47 healthy volunteers. TNF- $\alpha$  was induced by external lipopolysaccharide (LPS) so the immune response was activated in the study. Following that, participants did 20 minutes of intermediate treadmill exercise. Then, blood samples were taken from volunteers and extracted into plasma, which was used for examination. The investigation led to the conclusion that acute exercise had anti-inflammatory properties and also realized these effects through adrenergic  $\beta$ 2 receptors. (Dimitrov, Hulteng, and Hong 2017). Another study that was done as an experiment investigated the benefits of acute exercise on the inflammation of the airways. For this purpose, inflammation of the mouse's airways was caused by sensitization. Then the animals were treated with acute exercise or ovalbumin which is the one of medicine for allergic asthma. It was stated that the p65 subunit of the NF- $\kappa$ B was phosphorylated less frequently in the exercise group compared to the sedentary control group at the conclusion of the research. Furthermore, IL-5 and IL-13, both produced from Th2, as well as prostaglandin PGE2, were found to be lower in the ovalbumin and exercise treatment groups when compared to the control groups. As a result, it is presented that only single bout of moderate exercise has an impact on inflammation (Hewitt et al. 2012). In another study, it was investigated whether acute exercise inhibited inflammation caused by chronic kidney damage. Children and adolescents, both having advanced stages of chronic kidney failure, were included in the study. Participants did acute exercise on a cycle ergometer, and blood samples were collected and analysed both before and after the exercise. TNF- $\alpha$  levels were found to be rising as a result of the analyses. Furthermore, IL-6, the IL-6/TNF- ratio, and the number of immunoregulator natural killer cells were also increased. All these results demonstrated that acute exercise could contribute to an anti-inflammatory environment (Lau et al. 2015). Teixeira De Lemos et al. (2011) investigated the effects of acute exercise on type 2 diabetes mellitus.











They modelled type 2 diabetes mellitus on obese ZDF rats in the study and did, on the one hand, a single bout of exercise and, on the other hand, swimming exercise during 12 weeks as an intervention for the groups. End of the study collected blood samples were examined aspect of oxidant and inflammation. It is determined that even if one training, high-sensitivity C-reactive protein, TNF- $\alpha$ , and adiponectin levels were reduced. Also, the homeostatic model assessment for insulin resistance (HOMA-IR), which uses insulin sensitivity, was lower than the control group in the acute exercise group (Teixeira De Lemos et al. 2011). Considering all these data, it is clear that acute exercise shows anti-inflammatory properties in both local and systemic conditions.

To the contrary, mounting evidence brings to light the anti-inflammatory effects of acute exercise, but there are still some assertions about its increasing effects on inflammation. These claims are related to muscle damage that is caused by acute exercise.

It is a known fact that a single bout of exercise leads to a variety of degrees of muscle damage. The body tries to regulate the damage. As a natural result, there is a moderate level of inflammation and oxidative stress. If the body rests enough, all the damage could be eliminated. The body could then adapt to the circumstances. The process is an ordinary procedure aiming to ensure homeostasis. However, if there is a lack of resting time and/or conditions in which the body is overloaded, the damage could become chronic. Thus, chronic inflammation could be result with overloaded exercise syndrome which characterized by fatigue, depression, pain in the joint and loss of appetite (He et al. 2016; Woods et al. 2009). Based on these, when it is indicated that chronic exercise has anti-inflammatory effects, acute exercise is usually related to inflammation (Woods et al. 2009). Additionally, whether the activity is acute or chronic, it is probable that excessive exercise time and/or intensity, commencing an exercise session without warming up, or insufficient rest are likely to have an inflammatory impact. In order to achieve objective results regarding the exercise's impact on inflammation, one should select the exercise in accordance with the intensity, duration, and suitability of the individual. Additionally, one should consider the exercise's overall effects rather than just its local effects on the musculoskeletal system.

**Table 1.** An overview of several important cytokines related to inflammation (Docherty et al. 2022).

Cytokines	Action	Condition Of Alteration with Exercise
<b>Pro-Inflammatory</b>		
<b>TNF-<math>\alpha</math></b>	<ul style="list-style-type: none"> <li>• Stimulation of immune cells</li> <li>• Stimulating the synthesis of prostaglandin</li> </ul>	
<b>IL-8</b>	<ul style="list-style-type: none"> <li>• Chemotaxis of neutrophils</li> <li>• Induction of angiogenesis</li> </ul>	
<b>IL-15</b>	<ul style="list-style-type: none"> <li>• Activation of adaptive immune cell (B and T cells)</li> </ul>	
<b>IL-1<math>\beta</math></b>	<ul style="list-style-type: none"> <li>• Induces synthesis of nitric oxide, prostaglandins, and leukotrienes</li> </ul>	
<b>Anti-Inflammatory</b>		
<b>IL-4 &amp; IL-13</b>	<ul style="list-style-type: none"> <li>• Th1 cells inhibition</li> <li>• Plasma IL-1<math>\beta</math> mitigation</li> <li>• Upregulation of IL-1Ra expression</li> </ul>	
<b>IL-10</b>	<ul style="list-style-type: none"> <li>• Inhibition of pro-inflammatory cytokines including IL-1<math>\beta</math> and TNF-<math>\alpha</math></li> </ul>	

<b>IL-6</b>	<ul style="list-style-type: none"> <li>• Induces upregulation of IL-10 and IL-1Ra</li> <li>• P r o - i n f l a m m a t o r y cytokines inhibition</li> </ul>	
<b>IL-1Ra</b>	<ul style="list-style-type: none"> <li>• Inhibition of signalling through IL-1 receptor</li> </ul>	

## 2. Chronic Exercise and Inflammation

Exercise that is done repeatedly over a short or long period of time is referred to as chronic exercise (Sellami et al. 2018). Chronic exercise is known to have an anti-inflammatory impact (Woods et al. 2009). In the effect, it is stated that many mechanisms are effective (Scheffer and Latini 2020).

The primary reason for chronic exercise's anti-inflammatory effect is thought to be reduced adipocyte tissue size. Adipose tissue, a primary endocrine organ, secretes a variety of substances. These stimulants take on assignments in some situations and control or modify a variety of processes by interacting with surrounding cells or cells from other tissues. One of the mechanisms in which adipose tissue functions as an endocrine and paracrine organ is inflammation. Adipose tissue generates inflammatory mediators and has a growing impact on inflammation in conditions when there is an elevation in the mass, such as obesity. The mediators that are produced cause the resting macrophages to become active and exhibit signs of inflammation (Metsios et al. 2020; Scheja and Heeren 2019). On the other hand, the size of adipose tissue can be significantly reduced with regular exercise (Verheggen et al. 2016). Regular exercise also controls the hormones involved in metabolism (You et al. 2013). Thus, a reduction in inflammation is achieved by shrinking adipose tissue, altering mediators, and controlling metabolic hormones.

Peroxisome proliferator-activated receptor  $\gamma$  coactivator 1  $\alpha$  (PGC-1 $\alpha$ ), which is involved in energy metabolism and mitochondrial biogenesis, is another way that chronic exercise affects inflammation. Through an increase in AMP-activated protein kinase (AMPK), exercise raises PGC-1 $\alpha$ . It is claimed that this increase leads to an increase in anti-inflammatory

mediators, and that in the absence of PGC-1 $\alpha$ , the inflammatory response increases (Metsios et al. 2020). Researchers have looked into this using PGC-1 $\alpha$  knockout animals in experiments. Studies have demonstrated that TNF- $\alpha$  and IL-6, the two primary inflammatory cytokines, are expressed more often when PGC-1 $\alpha$  is deleted. (Handschin et al. 2007).

Chronic exercise also causes the release of stress hormones, which is another way of having an impact. Adrenaline and noradrenaline are released immediately during exercise. Cortisol is then released more often after that. While exercise, these catecholamines and cortisol secretions rapidly elevate. Additionally, it boosts the release of corticotropin-releasing hormone (CRH), which is released during exercise from the hypothalamus, adrenocorticotrophic hormone (ACTH), which is released from the pituitary gland, and cortisol, which is released from the adrenal gland. These varieties have higher levels of adrenaline and cortisol, which promote the immune system's response. Through beta-receptors, the catecholamines noradrenaline and adrenaline affect T cells, natural killer cells, macrophages, and neutrophils. Furthermore, it is claimed that elevated cortisol might also cause elevated IL-6 levels. However, the length and intensity of the activity are also relevant factors in this condition (Scheffer and Latini 2020).

Through the release of anti-inflammatory myokines from contracting skeletal muscle, regular exercise also influences inflammation. Exercise causes the production of many mediators, including IL-6, IL-7, IL-10, IL-15, and irisin. These myokines have a range of anti-inflammatory actions (Scheffer and Latini 2020). For instance, IL-15 works by lowering the amount of white adipose tissue and preadipocyte lipid accumulation. (Das, Graham, and Cardozo 2020; Pedersen 2017). Additionally, research suggests that IL-15 may mitigate negative effects of TNF- $\alpha$  in people with diabetes and obesity who also have low-grade chronic inflammation (Sánchez-Jiménez and Alvarado-Vásquez 2013). Irisin, another well-known myokine, promotes thermogenic activity. Additionally, it plays a significant role in the connection between exercise and the immune system (Scheffer and Latini 2020).

Inflammation is altered by long - term exercise in all of these ways, as well as numerous others that are still unclear. Research findings have shown that long-term exercise has an impact on inflammation in a variety of clinical diseases. One of the investigations was completed by Gondim et al. (2015). This research examined at how long-term exercise affected inflammatory and cardiovascular parameters in obese, overweight, and normal adult participants. The first procedure was to classify the 657 research participants into three groups based on their present weight: normal, overweight, and obese. The individuals were subsequently required to engage in moderate-intensity exercise for 60 minutes, every other day, for 6

and 12 months. Prior to the exercises beginning, as well as six and twelve months into the programs, blood samples were collected and subsequently examined. The results of the investigation showed that leptin and IL-6 levels were high in obese people before exercising and considerably decreased after exercise intervention. Similar circumstances were seen in individuals who were overweight. The study's findings demonstrated that exercise is advantageous for mild inflammatory disorders that affect overweight and obese individuals (Gondim et al. 2015). In their meta-analysis, Meléndez Oliva et al. (2022) included articles investigating the effects of long-term exercise against inflammation in haemodialysis patients. They included 24 trials that satisfied the criteria they established and in which exercise intervention was performed out without any restrictions into their meta-analysis. As a consequence, it has been observed that long-term exercises are beneficial in treating inflammation by affecting various cytokines. However, they mentioned that there is a need for more research on this subject, considering the variety of exercises used in the studies (aerobic, resistant, etc.), the difference in the dose, the fact that they were not performed in a standard time, and/or their frequency (Meléndez Oliva et al. 2022). In another study, the impact of lifetime exercise was investigated. In the research of healthy old persons who do not exercise for life, elderly people who exercise for life, and young people who exercise, the association between exercise and inflammation was examined. There were 41 individuals involved who did not use any kind of tobacco products, had no orthopaedic implantation surgery, and had no additional chronic diseases. Muscle samples from the patients were analysed for factors associated to inflammation, together with their activity and training histories. The evaluations' conclusion highlighted that lifespan exercise has an anti-inflammatory profile, despite the fact that proinflammatory cytokines increases with aging (Lavin et al. 2020).

In conclusion, in the light of this information, it is clear that both acute and chronic exercise have anti-inflammatory effects. However, it is probable that the total effect of the exercise will vary depending on some conditions, such as the demographic characteristics of the person, whether he has chronic diseases, and whether he has been trained before or not. At the same time, we think that when assessing the extent of an exercise-induced reduction in inflammation, factors like the type of exercise performed, the length of the exercise session, the intensity of the activity, and its appropriateness for the individual should be taken into consideration. For all of these reasons, additional research is required to clarify the mechanism of action of exercise on inflammation, elucidate the effects of exercise therapy in inflammatory conditions brought on by diseases, and analyse the information provided in this context in terms of variables like exercise duration, intensity, and type.

## References

- Basso, Julia C., and Wendy A. Suzuki. 2017. “The Effects of Acute Exercise on Mood, Cognition, Neurophysiology, And&nbsp;Neurochemical Pathways: A Review.” *Brain Plasticity* 2(2):127–52. doi: 10.3233/BPL-160040.
- Booth, Frank W., Christian K. Roberts, and Matthew J. Laye. 2012. “Lack of Exercise Is a Major Cause of Chronic Diseases.” *Comprehensive Physiology* 2(2):1143. doi: 10.1002/CPHY.C110025.
- Cavaillon, Jean-Marc. 2001. “Pro- versus Anti-Inflammatory Cytokines: Myth or Reality.” *Cellular and Molecular Biology (Noisy-Le-Grand, France)* 47(4):695–702.
- Cesari, Matteo, Brenda W. J. H. Penninx, Marco Pahor, Fulvio Lauretani, Anna Maria Corsi, G. Rhys Williams, Jack M. Guralnik, and Luigi Ferrucci. 2004. “Inflammatory Markers and Physical Performance in Older Persons: The InCHIANTI Study.” *The Journals of Gerontology: Series A* 59(3):M242–48. doi: 10.1093/GERONA/59.3.M242.
- Colbert, Lisa H., Marjolein Visser, Eleanor M. Simonsick, Russell P. Tracy, Anne B. Newman, Stephen B. Kritchevsky, Marco Pahor, Dennis R. Taaffe, Jennifer Brach, Susan Rubin, and Tamara B. Harris. 2004. “Physical Activity, Exercise, and Inflammatory Markers in Older Adults: Findings from The Health, Aging and Body Composition Study.” *Journal of the American Geriatrics Society* 52(7):1098–1104. doi: 10.1111/J.1532-5415.2004.52307.X.
- Das, Dibash K., Zachary A. Graham, and Christopher P. Cardozo. 2020. “Myokines in Skeletal Muscle Physiology and Metabolism: Recent Advances and Future Perspectives.” *Acta Physiologica* 228(2):e13367. doi: 10.1111/APHA.13367.
- Dimitrov, Stoyan, Elaine Hulteng, and Suzi Hong. 2017. “Inflammation and Exercise: Inhibition of Monocytic Intracellular TNF Production by Acute Exercise via B2-Adrenergic Activation.” *Brain, Behavior, and Immunity* 61:60–68. doi: 10.1016/J.BBI.2016.12.017.
- Docherty, Sophie, Rachael Harley, Joseph J. McAuley, Lindsay A. N. Crowe, Carles Pedret, Paul D. Kirwan, Stefan Siebert, and Neal L. Millar. 2022. “The Effect of Exercise on Cytokines: Implications for Musculoskeletal Health: A Narrative Review.” *BMC Sports Science, Medicine and Rehabilitation* 2022 14:1 14(1):1–14. doi: 10.1186/S13102-022-00397-2.
- Gondim, Olivia Santos, Vinicius Tadeu Nunes de Camargo, Fernanda Almeida Gutierrez, Patricia Fátima de Oliveira Martins, Maria Elizabeth Pereira Passos, Cesar Miguel Momesso, Vinicius Coneglian Santos, Renata Gorjão, Tania Cristina Pithon-Curi, and Maria Fernanda Cury-Boaventura. 2015. “Benefits of Regular Exercise on Inflammatory and Cardiovascular Risk Markers in Normal Weight, Overweight and Obese Adults.” *PLOS ONE* 10(10):e0140596. doi: 10.1371/JOURNAL.PONE.0140596.
- Handschin, Christoph, Soo Choi Cheol, Sherry Chin, Sheene Kim, Dan Kawamori, Amarnath J. Kurpad, Nicole Neubauer, Jiang Hu, Vamsi K.

- Mootha, Young Bum Kim, Rohit N. Kulkarni, Gerald I. Shulman, and Bruce M. Spiegelman. 2007. "Abnormal Glucose Homeostasis in Skeletal Muscle-Specific PGC-1 $\alpha$  Knockout Mice Reveals Skeletal Muscle-Pancreatic  $\beta$  Cell Crosstalk." *The Journal of Clinical Investigation* 117(11):3463. doi: 10.1172/JCI31785.
- He, Feng, Juan Li, Zewen Liu, Chia Chen Chuang, Wenge Yang, and Li Zuo. 2016. "Redox Mechanism of Reactive Oxygen Species in Exercise." *Frontiers in Physiology* 7(NOV):486. doi: 10.3389/FPHYS.2016.00486/BIBTEX.
- Hewitt, Matt, Amy Creel, Kim Estell, Ian C. Davis, and Lisa M. Schwiebert. 2012. "Acute Exercise Decreases Airway Inflammation, but Not Responsiveness, in an Allergic Asthma Model." <https://doi.org/10.1165/Rcmb.2008-0172OC> 40(1):83–89. doi: 10.1165/RCMB.2008-0172OC.
- Kolliniati, Ourania, Eleftheria Ieronymaki, Eleni Vergadi, and Christos Tsatsanis. 2022. "Metabolic Regulation of Macrophage Activation." *Journal of Innate Immunity* 14(1):51–68. doi: 10.1159/000516780.
- Lau, Keith K., Joyce Obeid, Peter Breithaupt, Vladimir Belostotsky, Steven Arora, Thanh Nguyen, and Brian W. Timmons. 2015. "Effects of Acute Exercise on Markers of Inflammation in Pediatric Chronic Kidney Disease: A Pilot Study." *Pediatric Nephrology* 30(4):615–21. doi: 10.1007/S00467-014-2971-8/FIGURES/1.
- Lavin, Kaleen M., Ryan K. Perkins, Bozena Jemiolo, Ulrika Raue, Scott W. Trappe, and Todd A. Trappe. 2020. "Effects of Aging and Lifelong Aerobic Exercise on Basal and Exercise-Induced Inflammation." *Journal of Applied Physiology* 128(1):87–99. doi: 10.1152/jappphysiol.00495.2019.
- Liu, Ting, Lingyun Zhang, Donghyun Joo, and Shao Cong Sun. 2017. "NF-KB Signaling in Inflammation." *Signal Transduction and Targeted Therapy* 2017 2:1 2(1):1–9. doi: 10.1038/sigtrans.2017.23.
- McElvaney, Oliver J., Gerard F. Curley, Stefan Rose-John, and Noel G. McElvaney. 2021. "Interleukin-6: Obstacles to Targeting a Complex Cytokine in Critical Illness." *The Lancet Respiratory Medicine* 9(6):643–54. doi: 10.1016/S2213-2600(21)00103-X.
- Meléndez Oliva, Erika, Jorge H. Villafañe, Jose Luis Alonso Pérez, Alexandra Alonso Sal, Guillermo Molinero Carlier, Andrés Quevedo García, Silvia Turróni, Oliver Martínez-Pozas, Norberto Valcárcel Izquierdo, and Eleuterio A. Sánchez Romero. 2022. "Effect of Exercise on Inflammation in Hemodialysis Patients: A Systematic Review." *Journal of Personalized Medicine* 2022, Vol. 12, Page 1188 12(7):1188. doi: 10.3390/JPM12071188.
- Metsios, George S., Rikke H. Moe, and George D. Kitas. 2020. "Exercise and Inflammation." *Best Practice & Research Clinical Rheumatology* 34(2):101504. doi: 10.1016/J.BERH.2020.101504.
- Panagiotakos, Demosthenes B., Christos Pitsavos, Christina Chrysohoou, Stavros Kavouras, and Christodoulos Stefanadis. 2005. "The Associations between Leisure-Time Physical Activity and Inflammatory and Coagulation Markers Related to Cardiovascular Disease: The ATTICA Study." *Preventive Medicine* 40(4):432–37. doi: 10.1016/J.YPMED.2004.07.010.

- Pedersen, Bente K., and Mark A. Febbraio. 2008. "Muscle as an Endocrine Organ: Focus on Muscle-Derived Interleukin-6." *Physiological Reviews* 88(4):1379–1406. doi: 10.1152/PHYSREV.90100.2007/ASSET/IMAGES/LARGE/Z9J0040824860006.JPEG.
- Pedersen, Bente Klarlund. 2017. "Anti-Inflammatory Effects of Exercise: Role in Diabetes and Cardiovascular Disease." *European Journal of Clinical Investigation* 47(8):600–611. doi: 10.1111/EJC.12781.
- Sánchez-Jiménez, Roberto, and Noé Alvarado-Vásquez. 2013. "IL-15 That a Regulator of TNF- $\alpha$  in Patients with Diabetes Mellitus Type 2." *Medical Hypotheses* 80(6):776–77. doi: 10.1016/J.MEHY.2013.03.009.
- Scheffer, Débora da Luz, and Alexandra Latini. 2020. "Exercise-Induced Immune System Response: Anti-Inflammatory Status on Peripheral and Central Organs." *Biochimica et Biophysica Acta (BBA) - Molecular Basis of Disease* 1866(10):165823. doi: 10.1016/J.BBADIS.2020.165823.
- Scheja, Ludger, and Joerg Heeren. 2019. "The Endocrine Function of Adipose Tissues in Health and Cardiometabolic Disease." *Nature Reviews Endocrinology* 2019 15:9 15(9):507–24. doi: 10.1038/s41574-019-0230-6.
- Scheller, Jürgen, Athena Chalaris, Dirk Schmidt-Arras, and Stefan Rose-John. 2011. "The Pro- and Anti-Inflammatory Properties of the Cytokine Interleukin-6." *Biochimica et Biophysica Acta (BBA) - Molecular Cell Research* 1813(5):878–88. doi: 10.1016/J.BBAMCR.2011.01.034.
- Sellami, Maha, Maha Gasmi, Joshua Denham, Lawrence D. Hayes, Dan Stratton, Johnny Padulo, and Nicola Bragazzi. 2018. "Effects of Acute and Chronic Exercise on Immunological Parameters in the Elderly Aged: Can Physical Activity Counteract the Effects of Aging?" *Frontiers in Immunology* 9(OCT):2187. doi: 10.3389/FIMMU.2018.02187.
- Teixeira De Lemos, Edite, Rui Pinto, Jorge Oliveira, Patrícia Garrido, José Sereno, Filipa Mascarenhas-Melo, Joo Páscoa-Pinheiro, Frederico Teixeira, and Flávio Reis. 2011. "Differential Effects of Acute (Extenuating) and Chronic (Training) Exercise on Inflammation and Oxidative Stress Status in an Animal Model of Type 2 Diabetes Mellitus." *Mediators of Inflammation* 2011. doi: 10.1155/2011/253061.
- Verheggen, R. J. H. M., M. F. H. Maessen, D. J. Green, A. R. M. M. Hermus, M. T. E. Hopman, and D. H. T. Thijssen. 2016. "A Systematic Review and Meta-Analysis on the Effects of Exercise Training versus Hypocaloric Diet: Distinct Effects on Body Weight and Visceral Adipose Tissue." *Obesity Reviews* 17(8):664–90. doi: 10.1111/OBR.12406.
- Woods, Jeffrey A., Victoria J. Vieira, and K. Todd Keylock. 2009. "Exercise, Inflammation, and Innate Immunity." *Immunology and Allergy Clinics of North America* 29(2):381–93. doi: 10.1016/J.IAC.2009.02.011.
- You, Tongjian, Nicole C. Arsenis, Beth L. Disanzo, and Michael J. Lamonte. 2013. "Effects of Exercise Training on Chronic Inflammation in Obesity." *Sports Medicine* 2013 43:4 43(4):243–56. doi: 10.1007/S40279-013-0023-3.





## **CHAPTER 13**

### **THE BUFFALO IN THE WORLD AND TÜRKIYE FROM 1961 TO 2020**

*Memiş BOLACALI<sup>1</sup>, Cahit ÖZCAN<sup>2</sup>, Mürsel KÜÇÜK<sup>3</sup>*

---

1 Assoc. Prof. Department of Animal Breeding and Husbandry, Faculty of Veterinary Medicine, Siirt University, Siirt, Turkey; bolacali@gmail.com; <https://orcid.org/0000-0002-4196-2359>.

2 Asst.. Prof. Department of Animal Nutrition and Nutritional Diseases, Faculty of Veterinary Medicine, Siirt University, 56100 Siirt, Turkey; cahitozcan@siirt.edu.tr; <http://orcid.org/0000-0002-1047-5347>.

3 Prof. Department of Animal Breeding and Husbandry, Faculty of Veterinary Medicine, Siirt University, Siirt, Turkey; murselkucuk@gmail.com; <https://orcid.org/0000-0002-0544-444X>

## 1. Introduction

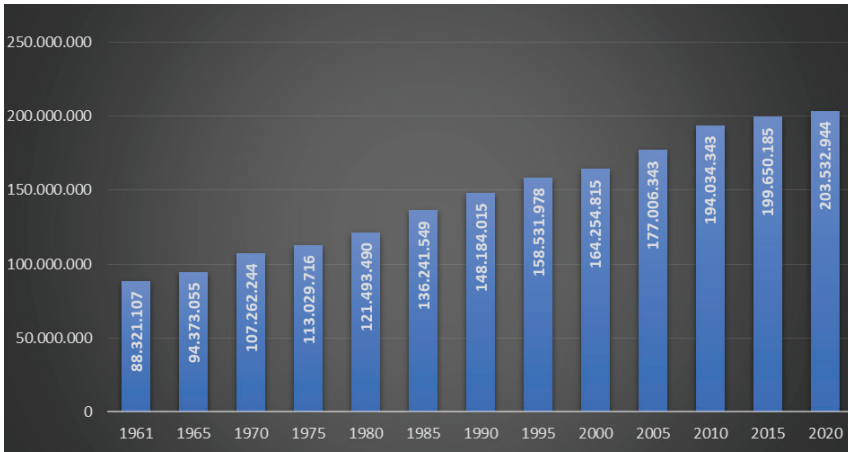
The buffalo breeding is carried out for meat and milk production, in short, for economic gain. In addition to this, the buffalo is also used as an attraction force in some countries. The buffalo stands out with the fact that it is not feed selective compared to other ruminants, can convert poor quality pasture and roughages into meat and milk yield better, and has high feed utilization ability. The buffaloes are also resistant to nature conditions and diseases and can easily adapt to harsh climatic and geographical conditions. Compared to cattle breeding, the buffalo breeding is preferred in less developed nations due to its many advantages such as low feed and labor costs. In addition, since the famous Italian Mozzarella cheese is obtained from the buffalo milk, it is also cultivated in developed countries. The buffalo, which is more suitable for farming in wetlands, meadows, marshes and reeds, is fed extensively in pastures in summer and winter seasons in our country. In regions of Türkiye where winter conditions are harsh, the buffaloes are grazed on pasture as feeding of winter, but in addition, they are fed with a small amount of concentrated feed added to poor quality roughage such as hay, corn stalks and straw (Uslu 1970; İlaslan et al., 1983; Karsli & Küçük, 2000; Demir & Akbulut, 2016; Arslan et al., 2020; Adkinson & Konca, 2021; Di Stasio & Brugiapaglia, 2021; Anonymous, 2022).

Compared to the contents of cow, sheep and goat milk, the buffalo milk has higher protein and fat content and lower lactose content. Due to its high fat content, the buffalo milk is used in the production of many dairy products such as yogurt, cream, butter and ice cream and is more preferred by consumers. Although the buffalo meat contains less fat, cholesterol and calories than beef, it contains more protein and minerals, and it is known that its muscle fibers are thicker and its color is darker red. Almost all of the buffalo meat produced in Türkiye is used in sausage and pastrami production. (Uslu 1970; Fisher, 1975; İlaslan et al., 1983; Canbolat, 2012; Demir & Akbulut, 2016; Di Stasio ne Brugiapaglia, 2021; Anonymous, 2022; Ozturk et al., 2022; Turan & Tatar, 2022).

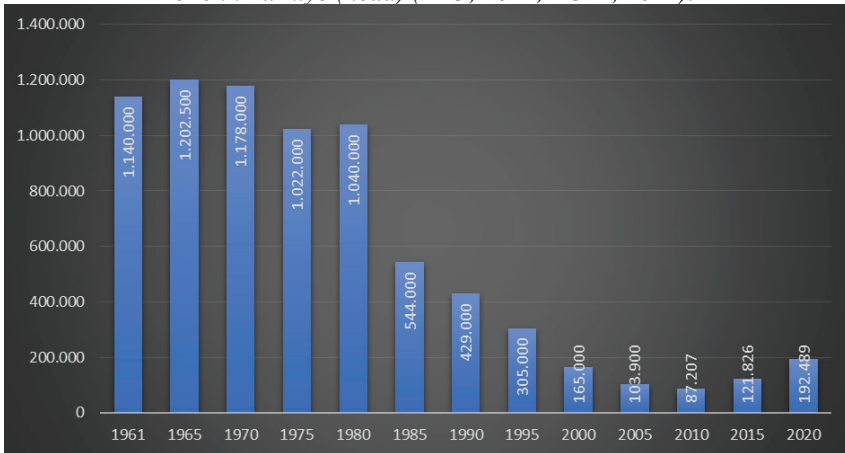
## 2. The Number of Buffalo, and Slaughtered and Milking Buffalo

The number of buffalo in worldwide has generally shown a continuously increasing trend for more than sixty years and exceeded two hundred million by 2020 (Graph 1). In Türkiye, the number of buffalo increased from 1961 to 1965, decreased from 1965 to 2010, and increased again in the following years (Graph 2). In 2020, India top one with 109.7 million, while Türkiye ranks 19th with about 192 thousand (Table 1).

*Graph 1. The Number of Buffalo from 1961 to 2020 in World (head) (FAO, 2022).*



*Graph 2. The Number of Buffalo from 1961 to 2020 in Türkiye (head) (FAO, 2022; TÜİK, 2022).*

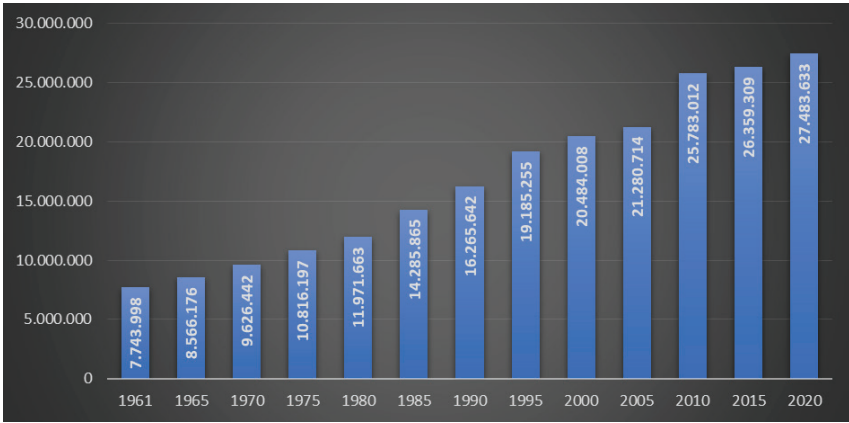


*Table 1. Top Countries for The Buffalo in 2020 (head) (FAO, 2022).*

Rank	Country	The Number of Buffalo	Rank	Country	The Number of Buffalo
1	India	109.719.011	16	Colombia	338.567
2	Pakistan	41.191.000	17	Sri Lanka	323.000
3	China	27.221.008	18	Iraq	233.453
4	Nepal	5.257.591	<b>19</b>	<b>Türkiye</b>	<b>192.489</b>
5	Myanmar	4.125.140	20	Iran	171.156
6	Philippines	2.865.715	21	Azerbaijan	146.652
7	Viet Nam	2.332.754	22	Timor-Leste	129.566
8	Egypt	1.671.378	23	Malaysia	100.242
9	Brazil	1.502.482	24	Bulgaria	20.180
10	Bangladesh	1.493.000	25	Romania	19.900
11	Lao People's Democratic Republic	1.234.000	26	Georgia	18.366
12	Indonesia	1.179.342	27	Tajikistan	15.532
13	Thailand	923.533	28	Germany	10.700
14	Cambodia	639.922	29	Kazakhstan	10.392
15	Italy	407.030	30	Hungary	7.400

The change in the number of slaughtered buffalo on worldwide is presented in Graph 3 and the change in Türkiye is presented in Graph 4. When the change in the number of buffalo slaughtered from 1961 to 2020 at the global level is looked, the number has been increasing continuously from 1961 to 2020 in world. Globally, it reached the highest number with 27.4 million in 2020. Between 1961 and 2020, the number of the buffalo slaughtered in Türkiye was looked; while an increase is observed from 1961 to 1965, a decreasing trend is observed from 1965 to 2020. In 2020, India top one with 11.5 million, while Türkiye ranks 23rd with 2184 (Table 2).

Graph 3. The Number of Slaughtered Buffalo from 1961 to 2020 in the World (head) (FAO, 2022).



Graph 4. The Number of Slaughtered Buffalo from 1961 to 2020 in Türkiye (head) (FAO, 2022; TÜİK, 2022).

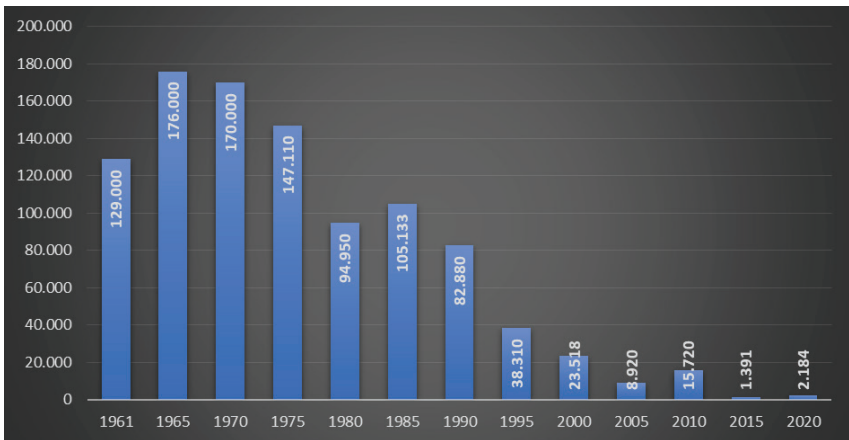
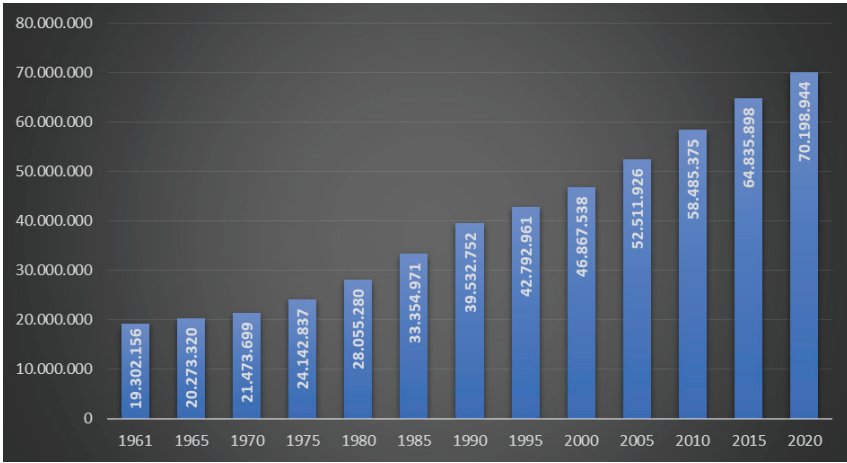


Table 2. Top Countries for Slaughtered Buffalo in 2020 (head) (FAO, 2022).

Rank	Country	The Number of Slaughtered Buffalo	Rank	Country	The Number of Slaughtered Buffalo
1	India	11.508.450	13	Thailand	71.430
2	Pakistan	7.874.000	14	Cambodia	46.098
3	China	4.563.815	15	Sri Lanka	34.871
4	Egypt	796.489	16	Colombia	31.585
5	Nepal	735.627	17	Iraq	28.255
6	Viet Nam	435.279	18	Iran	23.859
7	Philippines	400.276	19	Malaysia	14.553
8	Myanmar	393.254	20	Timor-Leste	6.730
9	Lao People's Democratic Republic	196.104	21	Syrian Arab Republic	3.926
10	Indonesia	119.760	22	Taiwan	2.299
11	Italy	103.566	<b>23</b>	<b>Türkiye</b>	<b>2.184</b>
12	Bangladesh	84.636	24	B r u n e i Darussalam	2.061

It has been determined that the number of milking buffalo worldwide has been increasing continuously for more than half a century (Graph 5). In Türkiye, there was an increase from 1961 to 1965, while there was no change between 1965 and 1980, and there was a rapid decrease from 1980 to 2010 and an increase trend again in the following years (Graph 6). In 2020, India top one with 44.3 million the number of milking buffalo, while Türkiye ranked 11th with about 80 thousand (Table 3).

Graph 5. The Number of Milking Buffalo from 1961 to 2020 in the World (head) (FAO, 2022).



Graph 6. The Number of Milking Buffalo from 1961 to 2020 in Türkiye (head) (FAO, 2022; TÜİK, 2022).

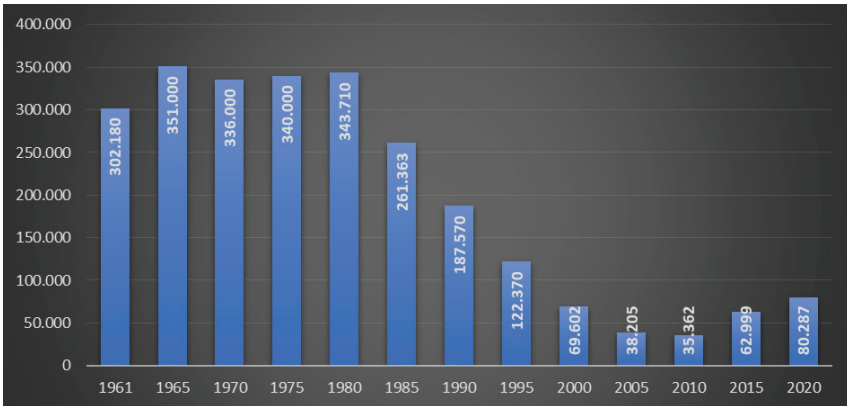


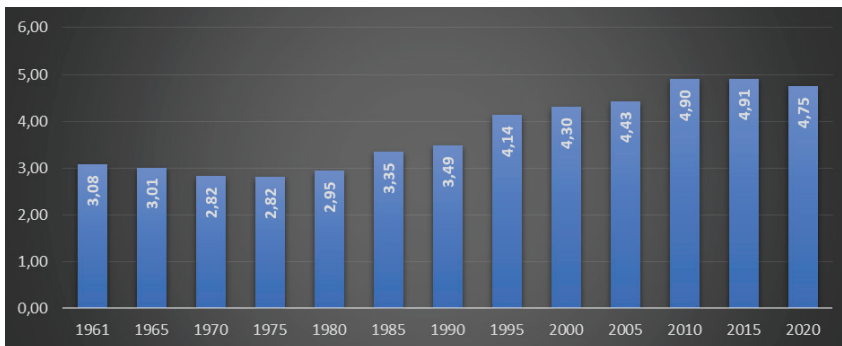
Table 3. Top Countries for The Milking Buffalo in 2020 (head) (FAO, 2022).

Rank	Country	The Number of Milking Buffalo	Rank	Country	The Number of Milking Buffalo
1	India	44.318.220	12	Iraq	53.700
2	Pakistan	15.404.000	13	Iran	45.000
3	China	5.799.582	14	Viet Nam	27.105
4	Nepal	1.635.492	15	Bulgaria	11.471
5	Egypt	1.310.443	16	Georgia	10.249
6	Mongolia	515.987	17	Malaysia	5.348
7	Myanmar	398.944	18	Syrian Arab Republic	4.051
8	Indonesia	123.196	19	Bhutan	239
9	Sri Lanka	102.050	20	B r u n e i Darussalam	179
10	Bangladesh	90.743	21	Albania	30
<b>11</b>	<b>Türkiye</b>	<b>80.287</b>			

### 3. Buffalo Meat Production

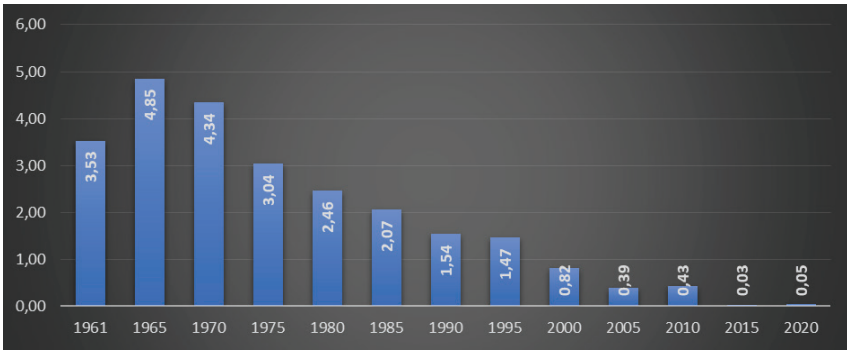
The percentages of the buffalo meat at from cattle, buffalo, sheep, and goat meat production at worldwide and Türkiye are presented in Graphs 7 and 8. When evaluated globally, it is observed that the buffalo meat percentage decreased between 1961 and 1975 and increased from 1975 until the last 5 years. Looking at the change in the buffalo meat percentage in Türkiye over the years, it is observed that there was an increase from 1961 to 1965, a decrease from this year onwards, and it was 0.05% in 2020.

Graph 7. Percentage of Buffalo Meat in Total Red Meat Production from 1961 to 2020 in the World (%) (FAO, 2022).



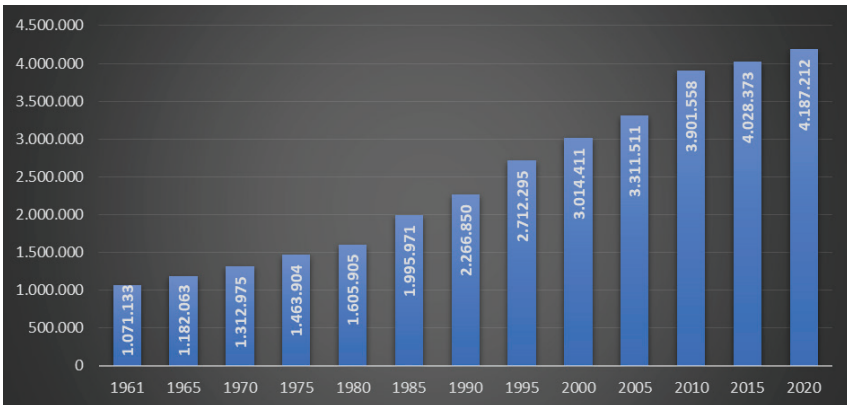


Graph 8. Percentage of Buffalo Meat in Total Red Meat Production from 1961 to 2020 in Türkiye (%) (FAO, 2022).

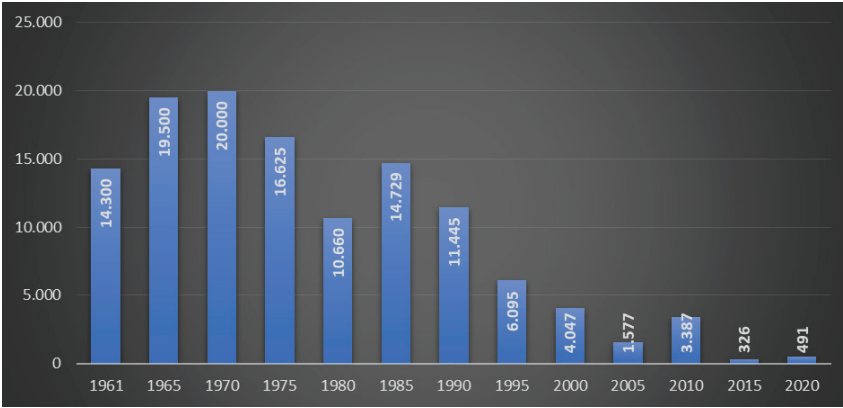


Looking at the change in buffalo meat production over the last sixty years in the world, it is seen that there has been a continuous increase and 4.2 million tonnes of meat was produced in 2020 (Graph 9). When the change in buffalo meat production in Türkiye over more than half a century is evaluated; it is determined that there are fluctuations, and the production in 2020 under review was 491 tonnes (Graph 10).

Graph 9. Buffalo Meat Production from 1961 to 2020 in the World (tonnes) (FAO, 2022).

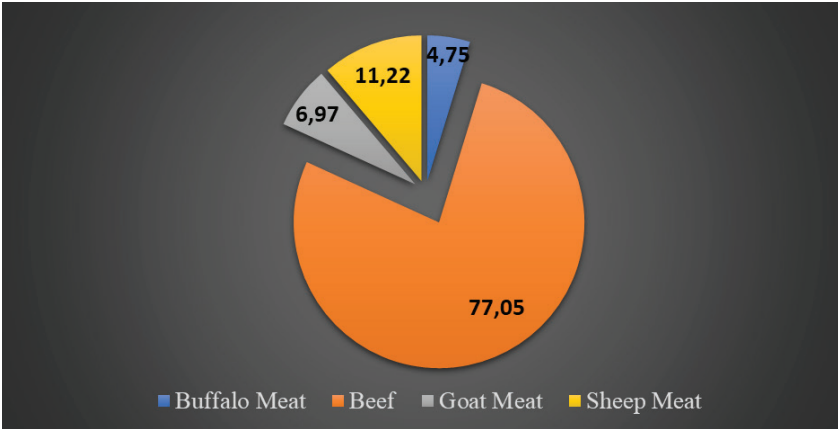


Graph 10. Buffalo Meat Production from 1961 to 2020 in Türkiye (tonnes) (FAO, 2022; TÜİK, 2022).



Distribution of red meat production in the world and Türkiye by some animal species in 2020 are presented in Graphs 11 and 12. When the graphs are evaluated, it is seen that the percentages of buffalo meat production in the world and Türkiye were 4.75% and 0.046% in 2020. In 2020, India top one with 1.6 million tonnes buffalo meat production, while Türkiye ranked 22nd with 491 tonnes (Table 4).

Graph 11. Distribution of Red Meat Production in the World by Some Animal Species in 2020 (FAO, 2022).



Graph 12. Distribution of Red Meat Production in Türkiye by Some Animal Species in 2020 (FAO, 2022).

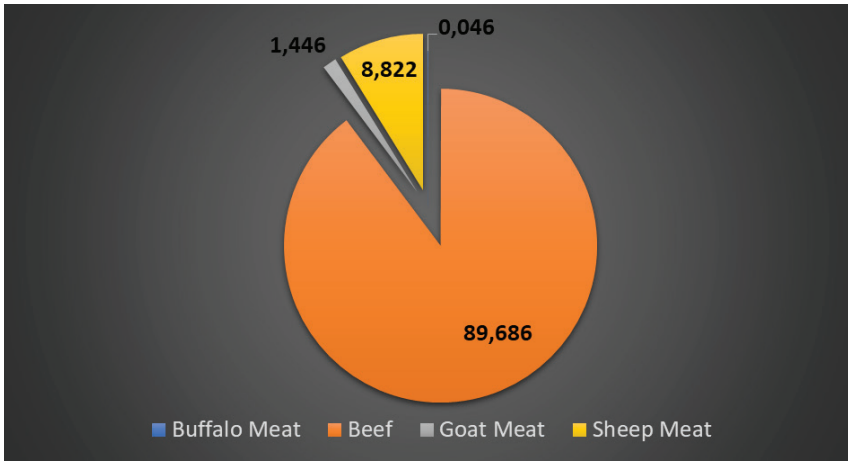


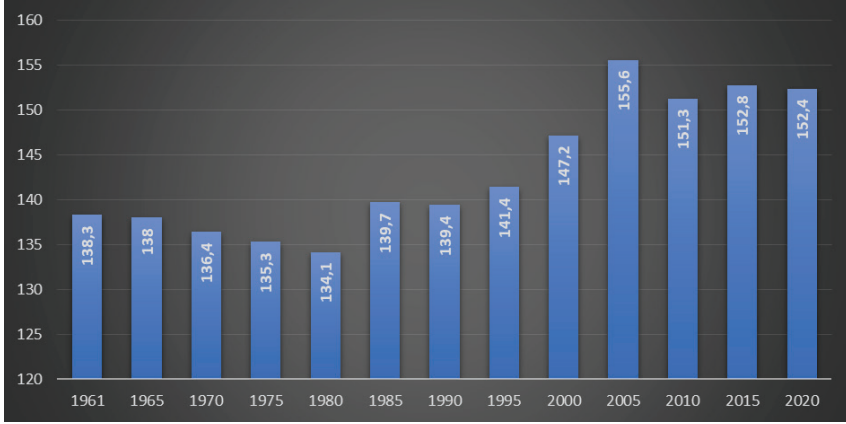
Table 4. Top Countries for Buffalo Meat Production in 2020 (tonnes) (FAO, 2022).

Rank	Country	Meat Production	Rank	Country	Meat production
1	India	1.599.559	13	Colombia	7.137
2	Pakistan	1.118.000	14	Cambodia	6.911
3	China	672.265	15	Bangladesh	6.771
4	Egypt	260.462	16	Malaysia	6.549
5	Nepal	189.517	17	Iraq	5.928
6	Viet Nam	96.732	18	Sri Lanka	3.940
7	Philippines	60.205	19	Timor-Leste	673
8	Myanmar	55.394	20	Syrian Arab Republic	597
9	Indonesia	24.875	21	Taiwan	500
10	Lao People's Democratic Republic	21.601	22	<b>Türkiye</b>	<b>491</b>
11	Thailand	19.033	23	B r u n e i Darussalam	483
12	Iran	8.065	24	Trinidad and Tobago	135

The changes in buffalo carcass weight in the world and Türkiye from 1961 to 2020 are presented in Graphs 13 and 14. When the graphs are evaluated; it is seen that buffalo carcass weight in the world shows a decreasing-increasing-decreasing trend, but in Türkiye there is a general increase. In 2020, Malaysia top one with 450 kg buffalo carcass weight, while Tür-

kiye ranked 8th with about 225 kg (Table 5).

Graph 13. Buffalo Carcass Weight from 1961 to 2020 in the World (kg) (FAO, 2022).



Graph 14. Buffalo Carcass Weight from 1961 to 2020 in Türkiye (kg) (FAO, 2022).

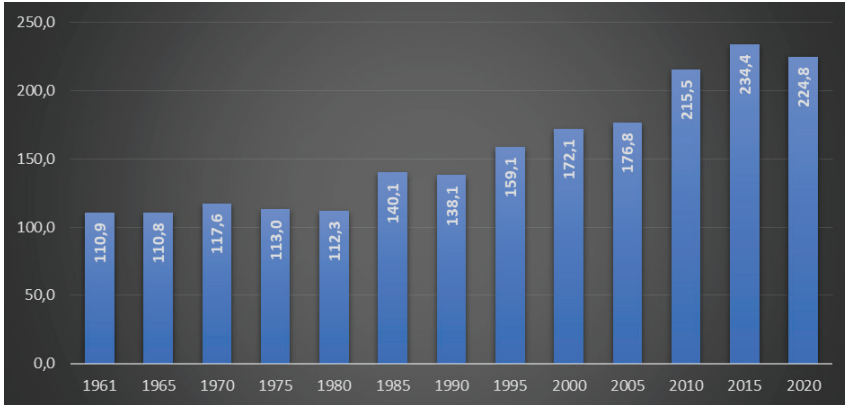


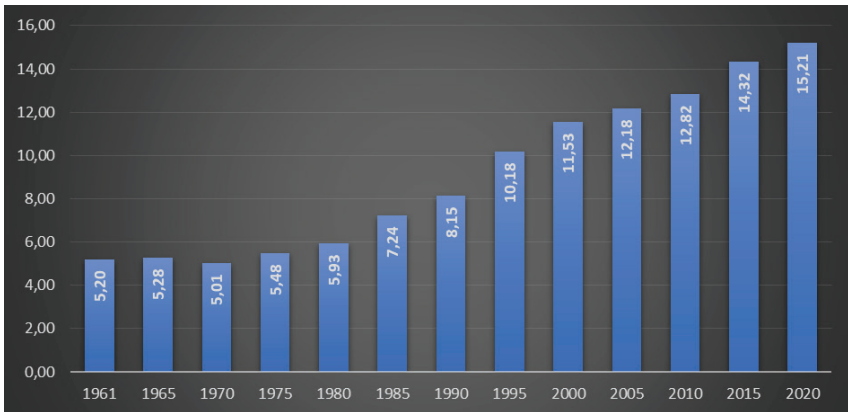
Table 5. Top Countries for Buffalo Carcass Weight in 2020 (kg) (FAO, 2022).

Rank	Country	The Carcass Weight	Rank	Country	The Carcass Weight
1	Malaysia	450,0	13	Syrian Arab Republic	152,1
2	Iran	338,0	14	Philippines	150,4
3	Egypt	327,0	15	Cambodia	149,9
4	Thailand	266,5	16	China	147,3
5	Nepal	257,6	17	Pakistan	142,0
6	B r u n e i Darussalam	234,4	18	Myanmar	140,9
7	Colombia	226,0	19	India	139,0
8	<b>Türkiye</b>	<b>224,8</b>	20	Sri Lanka	113,0
9	Viet Nam	222,2	21	Lao People’s Democratic Republic	110,2
10	Taiwan	217,5	22	Timor-Leste	100,0
11	Iraq	209,8	23	Bhutan	90,9
12	Indonesia	207,7	24	Bangladesh	80,0

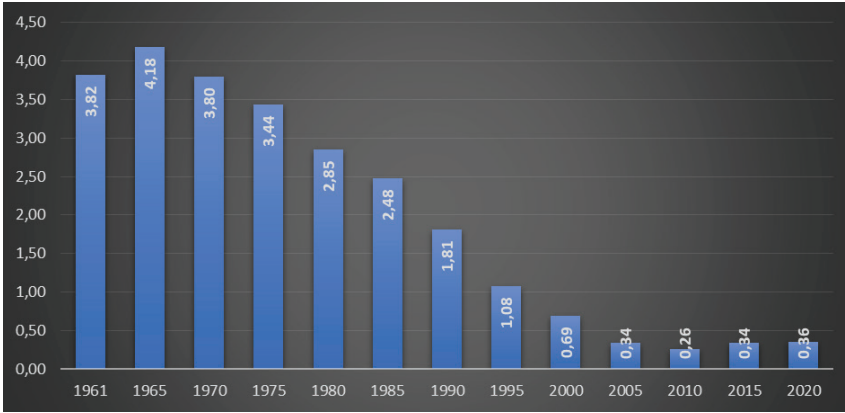
#### 4. Buffalo Milk Production

Changes in the percentage of buffalo milk at total cattle, buffalo, sheep and goat milk in the world and Türkiye are given in Graphs 15 and 16. When the graphs are evaluated; it is seen that the proportion of buffalo milk in total milk production in the world has continuously increased, and in Türkiye it is in a decreasing trend.

Graph 15. Percentage of Buffalo Milk in Total Milk Production from 1961 to 2020 in the World (%) (FAO, 2022).

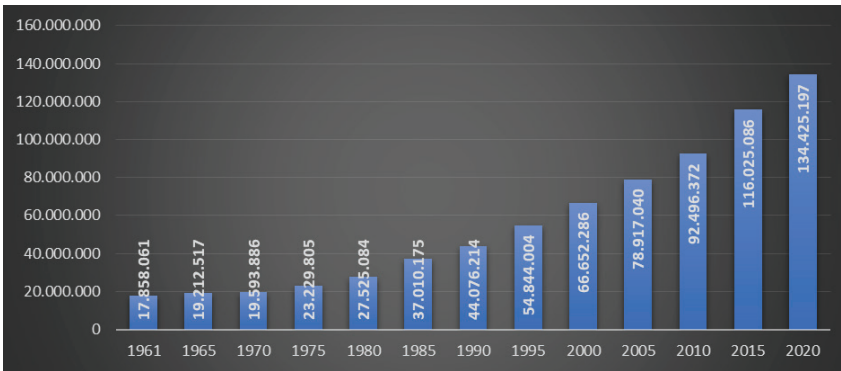


*Graph 16. Percentage of Buffalo Milk in Total Milk Production from 1961 to 2020 in Türkiye (%) (FAO, 2022).*

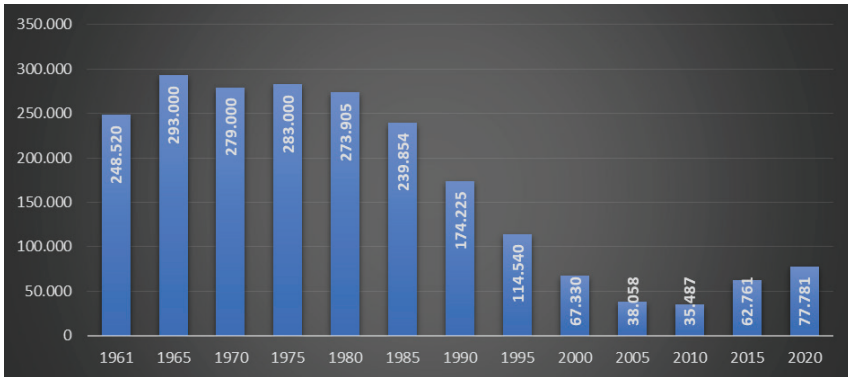


The change in buffalo milk production in the world and Türkiye from 1961 to 2020 is given in Graphs 17 and 18. From 1961 to 2020, there was a continuous increase in buffalo milk production in the world, but in Türkiye, it fluctuated in general, decreased from 1975 to 2010 and then increased.

*Graph 17. Buffalo Milk Production from 1961 to 2020 in the World (tonnes) (FAO, 2022).*

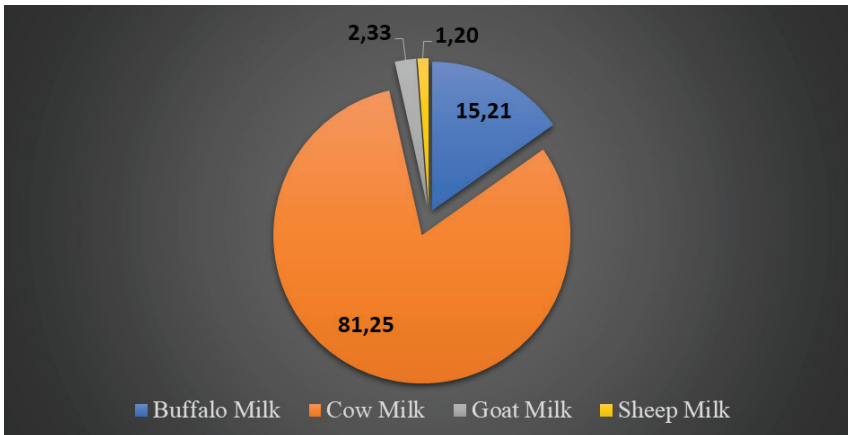


Graph 18. Buffalo Milk Production from 1961 to 2020 in Türkiye (tonnes) (FAO, 2022).



In 2020, the proportion of buffalo milk in total cattle, buffalo, sheep and goat milk production in the world and Türkiye is presented in Charts 15 and 16. When the graphs are analyzed, it is determined that the proportion of buffalo milk in total milk production in the world and Türkiye is 15.21% and 0.36%, respectively. In 2020, India top one with 90-million-ton buffalo milk production, while Türkiye ranked 12th with 77 thousand tonnes (Table 6).

Graph 19. Distribution of Milk Production in the World by Some Animal Species in 2020 (FAO, 2022).



Graph 20. Distribution of Milk Production in Türkiye by Some Animal Species in 2020 (FAO, 2022).

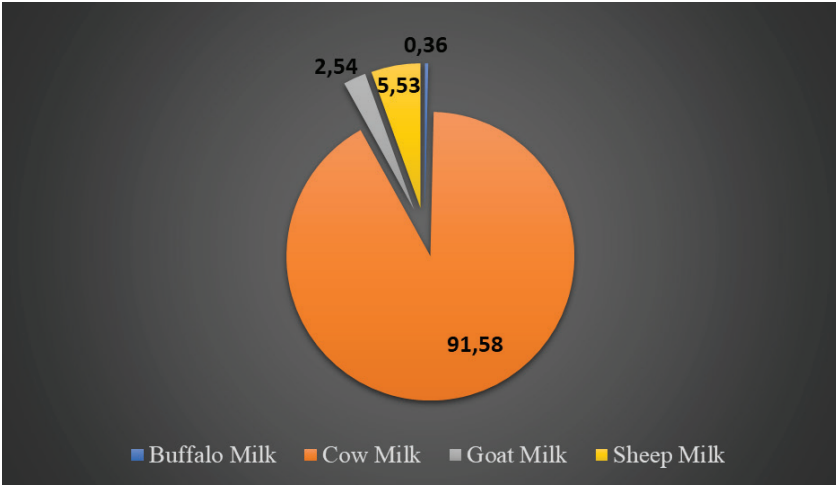


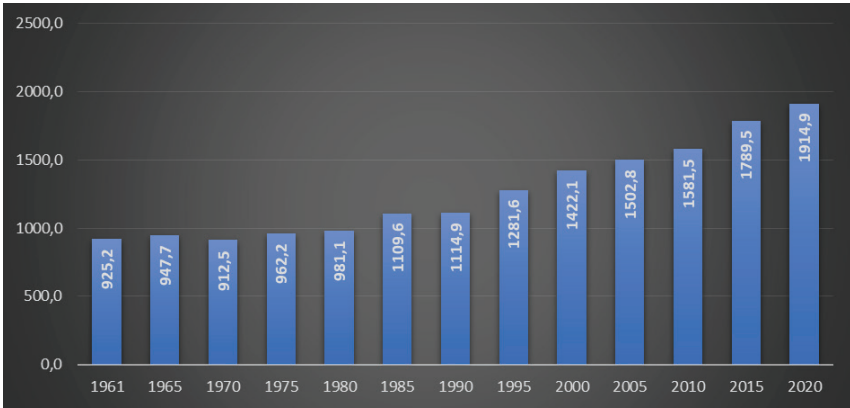
Table 6. Top Countries for Buffalo Milk Production in 2020 (kg) (FAO, 2022).

Rank	Country	The Milk Production	Rank	Country	The Milk Production
1	India	90.026.273	13	Iraq	37.737
2	Pakistan	37.256.000	14	Bangladesh	35.695
3	China	2.919.966	15	Viet Nam	26.983
4	Egypt	1.747.641	16	Romania	16.100
5	Nepal	1.380.600	17	Bulgaria	15.930
6	Italy	253.830	18	Malaysia	7.419
7	Myanmar	205.102	19	Syrian Arab Republic	6.868
8	Iran	128.000	20	Georgia	6.209
9	Mongolia	104.645	21	Netherlands	3.000
10	Indonesia	89.983	22	Germany	1.000
11	Sri Lanka	77.903	23	Bhutan	242
12	<b>Türkiye</b>	<b>77.781</b>	24	B r u n e i Darussalam	186

It is seen that the lactation milk yield of buffalo has continuously increased both in the world and in Türkiye (Graphs 21 and 22). In 2020, Romania top one with 3,305 kg buffalo lactation milk yield, while Türkiye ranked 13th with 968 kg. (Table 7).



Graph 21. The Lactation Milk Yield of Buffalo from 1961 to 2020 in the World (kg) (FAO, 2022).



Graph 21. The Lactation Milk Yield of Buffalo from 1961 to 2020 in Türkiye (kg) (FAO, 2022; TÜİK, 2022).

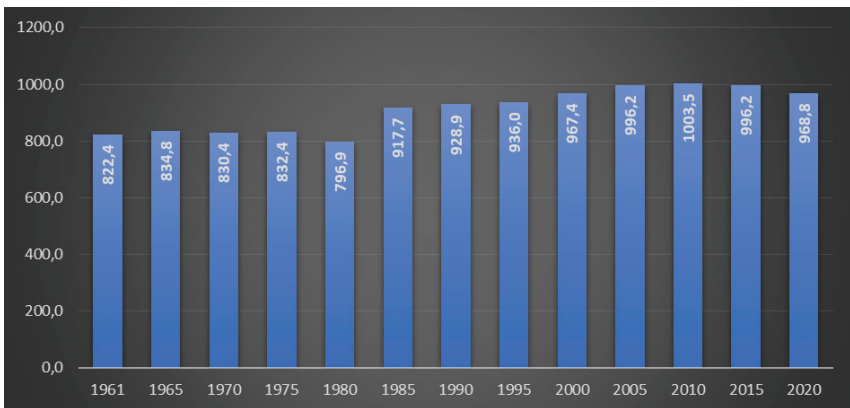


Table 7. Top Countries for Buffalo Lactation Milk Yield in 2020 (kg) (FAO, 2022).

Rank	Country	The Lactation Milk Yield	Rank	Country	The Lactation Milk Yield
1	Romania	3305,3	<b>13</b>	<b>Türkiye</b>	<b>968,8</b>
2	Iran	2844,4	14	Nepal	844,1
3	Pakistan	2418,6	15	Sri Lanka	763,4
4	India	2031,4	16	Indonesia	730,4
5	Syrian Arab Republic	1695,4	17	Iraq	702,7
6	Bulgaria	1388,7	18	Georgia	605,8
7	Malaysia	1387,2	19	Myanmar	514,1
8	Egypt	1333,6	20	China	503,5
9	B r u n e i Darussalam	1039,1	21	Albania	466,7
10	Bhutan	1012,6	22	Bangladesh	393,4
11	Italy	997,5	23	Greece	352,9
12	Viet Nam	995,5	24	Germany	328,9

## 5. Conclusion

Considering the number of the buffalo; although an increase is observed globally, it is observed that there is a decrease in Türkiye until 2010 and an increase since then. The number of buffalo, number of slaughtered buffalo, number of milking buffalo, total buffalo meat production, buffalo carcass weight, buffalo milk production, buffalo lactation milk yield in Türkiye in 2020 were 192.489 heads, 2.184 heads, 80.287 heads, 491 tonnes, 224,8 kg, 77,781 tonnes and 968.8 kg, respectively; top list in the world, Türkiye ranked 19th, 23rd, 11th, 22nd, 8th, 12th, 13th, respectively.

Considering the conditions such as meat and milk yields of buffalo, preferences of breeders and consumers, adoption of traditional breeding model, governmental incentive, condition of pastures, geographical structure and climatic conditions etc.; in order to maintain the increase in the buffalo data in the past decade in Türkiye; it is recommended i) to increase the governmental incentive for the buffalo calves, the buffalo meat and dairy products with feedstuff, ii) to increase biotechnological applications in buffalo breeding, iii) to increase public awareness through promotional activities to support the increase in buffalo products, iv) to support the establishment of large-scale enterprises in the sectoral context by government.

## References

- Adkinson, A.Y., & Konca, Y. (2021). Factors Affecting the Performance and Productivity of Dairy Buffalo Breeds and Future Perspective in Türkiye. *European Journal of Science and Technology*, (25), 498-508.
- Anonymous, (2022). Buffalo Breeding is a Feasible Alternative to Meet the Demand for Both Meat and Milk in Mexico [https://www.gob.mx/cms/uploads/attachment/file/737263/Crianza\\_de\\_b\\_falo\\_ENG.pdf](https://www.gob.mx/cms/uploads/attachment/file/737263/Crianza_de_b_falo_ENG.pdf)
- Arslan, C., Tufan, T., Avci, M., Kaplan, O., & Uyarlar, C. (2020). Effects Of Molasses, Barley, Oak Tannins Extracts and Previously Fermented Juice Addition on Silage Characteristics, in Vitro Organic Matter Digestibility and Metabolisable Energy Content of Grass Silage. *Fresenius Environmental Bulletin*, 29(8), 6533-6542.
- Canbolat, Ö. (2012). Buffalo Breeding and Current Situation in Türkiye. *Tarım Türk Dergisi*, 30: 176-180.
- Demir, Y., & Akbulut, Ö. (2016). Buffalo Growing in Türkiye and Current Situation in Erzurum Province. *Eastern Anatolian Journal of Science*, 2(2), 63-66.
- Di Stasio, L., & Brugiapaglia, A. (2021). Current Knowledge on River Buffalo Meat: a Critical Analysis. *Animals*, 11(7), 2111.
- FAO (2022). The Food and Agriculture Organization <http://www.fao.org/faostat/en/#data/QL> Access date: 12.12.2022
- Fisher, H. (1975). The Water Buffalo. A physiological survey of types and uses. *Animal Research and Adevelopment*, 1, 118-130.
- İlaslan, M., Karabulut, A., Aşkın, Y., and İzgi, A.N. (1983), Yerli Mandalarda Vücut Yapısı, Döl ve Süt Verimi Üzerine Araştırmalar, Zirai Araş. Enst. Yay. No:14 Afyon.
- Karsli, M. A., & Küçük, M. (2000). Grazing Behaviors of Ruminant Livestock. *Yüzüncü Yıl Üniversitesi Veteriner Fakültesi Dergisi*, 11(1), 123-129.
- Ozturk, N., Kocak, O., Peker, A., Serva, L., Kaygisiz, F., Kecici, P. D., ... & Magrin, L. (2022). Characteristics of Buffalo Farming Systems in Türkiye Based on a Multivariate Aggregation of Indicators: A Survey Study. *Animals*, 12(21), 3056.
- TUİK (2022). Turkish Statistical Institute <https://biruni.tuik.gov.tr/medas/?kn=79&locale=tr> Access date:: 14.12.2022
- Turan, M., & Tatar, A. M. (2022). An Evaluation on the Current State of Water Buffalo Breeding in Diyarbakır, Identification of Problems and Solutions. *International Journal of Agriculture Environment and Food Sciences*, 6(1), 141-151.

Uslu, N.T. (1970), Afyon Bölgesi Mandalarının Çeřitli Özellikleri ile Rasyonel ve Köy Şartlarında Süt Verimleri Üzerinde Mukayeseli Arařtırmalar, Birlik Matbaası, Bornova, İzmir.

Williamson, G., Payne, W.J.A. (1968). An Introduction to Animal Husbandry in the Tropics. 2nd Ed. Longrans Green and Co. Ltd. London.



## ***CHAPTER 14***

### **TELOMERASE ACTIVITY IN NEUROBLASTOMA**

*Nihal İNANDIKLIOĞLU<sup>1</sup>*

---

<sup>1</sup> Assoc. Prof., Department of Medical Biology, Faculty of Medicine, Yozgat Bozok University, Yozgat, TÜRKİYE. [nihal.inandiklioglu@yobu.edu.tr](mailto:nihal.inandiklioglu@yobu.edu.tr)  
ORCID ID: 0000-0001-7137-3929

## Neuroblastoma

Peripheral neuroblastic tumors are the most common extracranial solid tumors in childhood and infancy. They constitute approximately 15% of all neoplasms seen in the first four years (1). Prognostic classification for peripheral neuroblastic tumors is an important issue. In 1984 Shimada et al., peripheral neuroblastic tumors were divided into 4 categories with an age-dependent histological classification system (2): I. Neuroblastoma (poor Schwannian stroma), II. Ganglioneuroblastoma intermixed (rich in Schwannian stroma), III. Ganglioneuroblastoma nodular, IV. Ganglioneuroma (Schwannian stroma dominant). Neuroblastoma (NB), like other peripheral neuroblastic tumors, is originated from the neural crest cells of the sympathetic adrenal system. Therefore, tumors can develop anywhere in the sympathetic nervous system. Approximately 65% of primary tumors occur in the abdomen. At least half of these are localized in the adrenal medulla. Other common sites are the neck, thoracic cavity, and pelvis. The most common distant metastases are regional lymph nodes, liver, bone marrow and bones. NB accounts for approximately 7% of malignancies in patients younger than 15 years of age. It is responsible for approximately 15% of all pediatric cancer-related deaths (3).

The system adopted by the Turkish Pediatric Oncology Group (TPOG) in the National Neuroblastoma Treatment Protocol is the “International Staging System”, which is the developed and customized version of the Evans classification (Table-1).

**Table-1:** *International neuroblastoma staging system (INSS)*

Stage	Properties
Stage 1	Macroscopic complete resection of the tumor limited to the organ of origin. Microscopic tumor residue may or may not be present. There is no ipsilateral and contralateral lymph node involvement.
Stage 2a	Unilateral tumor, incomplete macroscopic resection. There is no ipsilateral and contralateral lymph node involvement.
Stage 2b	Unilateral tumor, macroscopic complete or incomplete resection. There is ipsilateral regional lymph node involvement, no contralateral involvement.
Stage 3	There is tumor and regional lymph node involvement that exceeds the midline. - Unilateral tumor and contralateral lymph node involvement - There is a midline tumor and bilateral lymph node involvement.
Stage 4	Disseminated disease, distant metastases (distant lymph node, bone marrow, bone, liver, etc.).
Stage 4-S	Localized primary tumor such as stage 1 and 2. There is only liver, skin and/or bone marrow spread. Age must be < 365 days.

Genetic changes in NB tumor cells play an important role in the prognosis, pathogenesis, classification, and treatment planning of the disease. When we look at the common genetic changes in NB, the MYCN gene is the most important genetic diagnostic criterion. The MYCN nucleoprotein is encoded by the gene located at p24.1 on chromosome 2 and is required for neural development during embryogenesis. MYCN amplification is seen in approximately 20% of NB and is a molecular marker predicting aggressive clinical behavior. It is one of the most important prognostic factors and its presence is associated with advanced stage, high risk, relapsed tumor and poor prognosis. Because of this prognostic importance, it is routinely examined in many centers and affects the treatment plan scheme (4). Another important aberration is the increase in the long arm of the 17th chromosome (+17q). This situation can occur spontaneously, or with a translocation between the 1st and 17th chromosomes. It has been associated with poor prognosis and aggressive tumor (5). Loss of heterozygosity in chromosome 1p and chromosome 11q arms and deletion of chromosome 1p36 are other genetic changes seen in neuroblastomas. Studies have found a significant relationship between loss of 1p36 and 11q23 heterozygosity and high-risk NB (6).

### **Telomere and Telomerase**

Telomeres are DNA-protein structures consisting of 5'-TTAGGG-3' repeating sequences located at the linear ends of chromosomes in eukaryotic cells. The number of repeats of telomeric sequences differs between individuals of the same species and even between chromosomes. The hexanucleotide sequences that make up the telomere terminate in a guanine (G)-rich single-stranded TTAGGG sequence of 100-200 nucleotides called the T-loop. The T-loop occurs when the telomere twists up on itself. The G-rich single strand inserts into the double-stranded telomere, replacing one of the telomere strands, forming a second loop, the D-loop. These structures protect the telomere from fusing with other chromosomes and being perceived as a chromosome break. Thus, telomeres are important in genome stability (7). Telomeres are made up of telomere DNA and telomere-associated proteins. These special proteins, which are attached to telomeres at various sites, function in shaping the ends of telomeres and maintaining telomere length. The single and double branch protein complex that binds to the telomere is called the telosome or shelterin. It protects the telomere from degradation and controls its length by creating this complex T-loop structure. There are 6 main proteins in the telomere complex. These are Rap1 (repressor/activator protein 1), TRF1 (telomere-repeat-binding factor 1), TRF2 (telomere-repeat-binding factor 2), POT1 (protection of telomeres-1), TIN2 (TRF1-interacting nuclear factor 2) and TPP1 (tripeptidylpeptidase 1). Shelterin, a telomere-binding com-

plex protein, combines with telomere DNA and has a protective effect on the chromosome against DNA breaks (8).

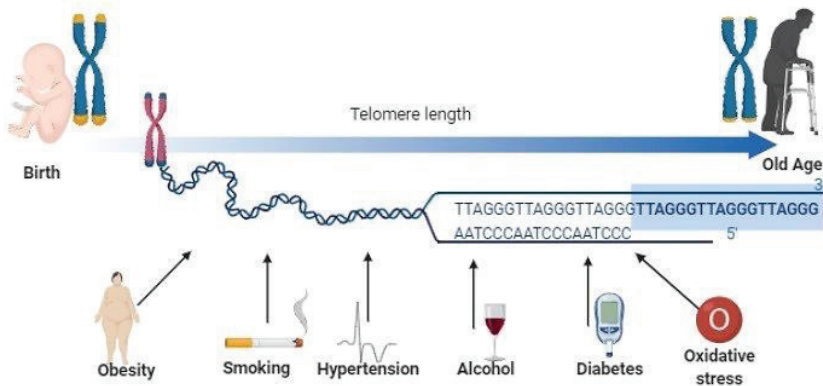
During cell replication, telomeric regions at the ends of chromosomes are not fully replicated. Thus, a decrease in telomere length occurs with each cell division. This shortening averages 50-200 base pairs per cell cycle. Telomerase enzyme is responsible for keeping this shortening under control and maintaining telomere length (9). Telomerase enzyme is a ribonucleoprotein structured reverse transcriptase and a large enzyme complex. It consists of two main subunits, TERT (telomerase reverse transcriptase) and TERC (telomerase RNA component). This complex is responsible for adding telomere sequences to chromosomes. TERT, which constitutes the catalytic subunit of the telomerase enzyme, has a limiting effect on telomerase enzyme activity, thanks to its transcriptional regulation function (10). Telomerase is a reverse transcriptase that allows the addition of telomeric repeats to the telomere sequences of eukaryotic chromosomes. Telomerase is a reverse transcriptase that allows the addition of telomeric repeats to the telomere sequences of eukaryotic chromosomes. Telomerase activity is usually minimal in normal somatic cells, except for highly regenerated tissues (11). The human TERT gene is located on chromosome 5p15.33 and consists of 16 exons and 15 introns. Of the genes known to have 7 transcripts, only 4 of them encode proteins. There are data showing that this gene, which has a very dynamic structure, has different lengths in different databases. The TERC gene is localized to chromosome 3q21-q28. The TERC gene, which consists of a single exon, has a single transcript consisting of 541 base pairs. TERC, a RNA gene, does not code for protein (12).

While telomerase enzyme function is observed in the first weeks of the embryo stage, it then decreases in most cells with age (13). Although telomerase activity is lost in most somatic cells, telomerase activity continues at low levels in germ cells, endometrium, cervical epithelium, epidermis, esophageal epithelium, intestinal crypts and hair follicles, bone marrow cells, hematopoietic stem cells, and activated lymphocytes (14). Telomere dysfunction is linked to the development of age-related pathologies including cardiovascular disease, Parkinson's disease, Alzheimer's disease, and cancer (15). One of the most common diseases in which telomere and telomerase pathologies are seen is cancer. 90% of human cancer cells have high telomerase activity. Telomerase alone cannot transform a normal cell into a cancer cell. However, it is necessary for cells to gain unlimited growth capacity, become immortal and maintain their telomere length (16).

Telomere length, which can be affected by various lifestyle factors, can determine the general health, life expectancy and aging rate of the individual. Telomere length has been associated with normal aging, stress,



inflammatory processes, regeneration, infection, and chronic diseases (such as diabetes mellitus, coronary artery disease, and ulcerative colitis) (17). Inflammation and proliferation of cells during diseases result in loss of telomeric repeats due to increased cell division. Plasma concentration of the inflammatory marker CRP (C-reactive protein) has been found to be negatively correlated with telomere length. The use of anti-inflammatory drugs may reduce the shortening of telomere length following inflammation (18,19). In addition, in different studies, decreased telomere length has been associated with low vitamin D intake, increased oxidative stress, increased body mass index, smoking, low socio-economic status, and decreased physical activity (20-23) (Figure-1).



**Figure-1:** Some factors affecting telomere length.

### Association of telomerase and neuroblastoma

One of the main mechanisms that increase telomerase reactivation and expression in cancer cells is TERT mutation. TERT gene amplification was identified in 73% of all cancers in the Cancer Genome Atlas cohort, which included 6835 patients and 31 tumor types (24). Upregulation or reactivation of telomerase is a critical feature in the development of approximately 85% of human cancers and is associated with poor prognosis (25,26). In recent years, important studies have emphasized that TERT aberrations play a role as important drivers in high-risk neuroblastoma (27,28). In NB, telomeres are protected by MYCN, which transcriptionally activates the TERT gene, TERT rearrangements, or telomerase activation, which results in somatic mutations in the TERT promoter (28). Telomerase can be activated by induction of TERT. This may occur with MYCN amplification and TERT promoter mutations (TERT genomic rearrangements, including TERT structural variants, epigenetic modifications via TERT promoter methylation) (28,29).

In one third of primary NB, alterations of telomerase activation and its association with poor patient survival have been demonstrated. Moreover, it was emphasized that TERT rearrangements are an independent prognostic marker (30). Incidence of hotspot mutations in the TERT promoter directing telomerase activity varies in various human malignancies. Although TERT promoter mutation can be seen in many tumor groups, the most common tumor groups are central nervous system tumors, bladder tumors, thyroid tumors and malignant melanoma (31). TERT promoter hotspot mutations were detected 124 bp (C228T) and 146 bp (C250T) upstream of the transcriptional start site. Mutations in the TERT promoter region are rare in NB primary tumors and cell lines, unlike other cancers (32). In a study by Peifer et al. performed whole genome sequencing in primary NB patients. In 21% of cases, repetitive genomic rearrangements were discovered upstream of the TERT transcriptional start site on chromosome 5p15.33 that did not affect the promoter. In addition, elevated TERT expression levels were detected in all tumors with TERT rearrangements (28). It has been shown that both 5p15.33 rearrangements and MYCN amplification are associated with TERT activation in high-risk neuroblastoma (30). DNA methylation analyzes were indicated to a consistent increase CpG methylation across the TERT locus in rearranged and MYCN+ tumors. The strongest differential methylation was detected in a CpG region located near the core promoter of TERT (33). The results highlighted that the structural rearrangements occurring in 5p15.33 led to the juxtaposition of the TERT locus with strong enhancer elements, resulting in a massive epigenetic remodeling of the affected region (30).

In a study examining the prognostic effect of telomerase activity in NB patients, the 5-year event-free survival rate was 86.5% in patients with low telomerase activity, while it was found 53.8% in patients with high telomerase activity (34). In the semi-quantitative analysis of telomere length and telomerase activity, it was found that telomeres were short in both aggressive and regressive tumors, and telomerase activity was very low or undetectable in regressive tumors. While telomerase activity was determined to be high in 22% of NB patients and low in 74% of NB patients, telomerase activity was not detected in 4%. Accordingly, it was thought that telomerase activity could be a useful method in determining the clinical behavior of neuroblastomas (35). It has been suggested that low or undetectable telomerase activity is frequently seen in younger patients without poor prognostic factors, and high activity in older children with poor prognostic factors (36). High telomerase activity in disseminated disease was significantly associated with poor prognosis and survival rates were below 20%. In high-stage tumors without telomerase activity, survival rates were significantly higher than in tumors of the same stage. In the neuroblastoma study of the German Pediatric Oncology and Hematology Group, the 5-year survival rate was determined as 21-25% (37). In

another study by the same researchers, a significant relationship was found between telomerase activity and clinical behavior. Therefore, it has been recommended to add telomerase activity analysis to other clinical examinations during diagnosis in all neuroblastoma cases (38).

In the light of all these findings and information, several potential drugs based on telomerase and telomere biology have been developed and investigated by biotechnology companies (39). Studies have shown that telomerase represents a potential therapeutic target in patients with telomerase-positive neuroblastoma who have a poor prognosis with current treatment protocols (30). Imetelastat (GRN163L) acts by competitively inhibiting the active site of telomerase, preventing the enzyme from attaching to telomere DNA and adding telomere sequences (40). Clinical development of this compound was halted due to its toxicity as results of Phase I study in 20 children with refractory or recurrent solid tumors with NB and Phase II study in children with central nervous system malignancies (41,42). Recently, both in vitro and in vivo studies of the telomerase substrate nucleoside precursor 6-thio-2'-deoxyguanosine (6-thio-dG) have been performed in preclinical models. It has been shown to significantly impair the growth of telomerase-positive tumors, including neuroblastoma cell lines with TERT rearrangements, MYCN amplification, or high TERT expression (30,43). Since 6-thio-dG is less toxic than other telomerase inhibitors and is the compound of high priority for NB, clinical trials are awaited (44). Although telomerase-targeted therapies are not currently available in a standard cancer treatment, telomerase remains a potential target for the development of new therapies.

### **Conclusion**

In the light of the data in the literature, telomerase activation was evaluated as a strong prognostic marker as a result of multivariate analyzes. Therefore, its potential value for neuroblastoma risk assessment has been emphasized. Recurrent TERT rearrangements, TERT expression activity, and telomere elongation have been discovered in high-risk neuroblastomas. Thus, it has been shown that a molecular definition of the neuroblastoma subtype is provided. Detection and quantification of TERT variants has been interest in terms of clinical outcome and prognosis. It has been observed that the presence of TERT promoter mutation may be associated with prognosis. However, multicenter studies with larger numbers of patients are needed to elucidate its prognostic position. Larger data are needed to better evaluate the relationship of telomerase activity with risk groups and survival in NB patients. Despite the ever-increasing knowledge of telomere and telomerase biology, there are still questions to be answered as clinical strategies are not yet available. A new therapeutic option for this deadly pediatric disease may be promising with the development of effective telomerase inhibitors.

## References

1. Shimada, H., Ambros, I. M., Dehner, L. P., Hata, J., Joshi, V. V., Roald, B., Stram, D. O., Gerbing, R. B., Lukens, J. N., Matthay, K. K., & Castleberry, R. P. (1999). The International Neuroblastoma Pathology Classification (the Shimada system). *Cancer*, *86*(2), 364–372.
2. Altungoz, O., Aygun, N., Tumer, S., Ozer, E., Olgun, N., & Sakizli, M. (2007). Correlation of modified Shimada classification with MYCN and 1p36 status detected by fluorescence in situ hybridization in neuroblastoma. *Cancer genetics and cytogenetics*, *172*(2), 113–119. <https://doi.org/10.1016/j.cancergencyto.2006.10.005>
3. Maris, J. M., Hogarty, M. D., Bagatell, R., & Cohn, S. L. (2007). Neuroblastoma. *Lancet (London, England)*, *369*(9579), 2106–2120. [https://doi.org/10.1016/S0140-6736\(07\)60983-0](https://doi.org/10.1016/S0140-6736(07)60983-0)
4. Matthay, K. K., Maris, J. M., Schleiermacher, G., Nakagawara, A., Mackall, C. L., Diller, L., & Weiss, W. A. (2016). Neuroblastoma. *Nature reviews. Disease primers*, *2*, 16078. <https://doi.org/10.1038/nrdp.2016.78>
5. Łastowska, M., Cotterill, S., Bown, N., Cullinane, C., Variend, S., Lunec, J., Strachan, T., Pearson, A. D., & Jackson, M. S. (2002). Breakpoint position on 17q identifies the most aggressive neuroblastoma tumors. *Genes, chromosomes & cancer*, *34*(4), 428–436. <https://doi.org/10.1002/gcc.10089>
6. Attiyeh, E. F., London, W. B., Mossé, Y. P., Wang, Q., Winter, C., Khazi, D., McGrady, P. W., Seeger, R. C., Look, A. T., Shimada, H., Brodeur, G. M., Cohn, S. L., Matthay, K. K., Maris, J. M., & Children's Oncology Group (2005). Chromosome 1p and 11q deletions and outcome in neuroblastoma. *The New England journal of medicine*, *353*(21), 2243–2253. <https://doi.org/10.1056/NEJMoa052399>
7. Giardini, M. A., Segatto, M., da Silva, M. S., Nunes, V. S., & Cano, M. I. (2014). Telomere and telomerase biology. *Progress in molecular biology and translational science*, *125*, 1–40. <https://doi.org/10.1016/B978-0-12-397898-1.00001-3>
8. O'Connor, M. S., Safari, A., Xin, H., Liu, D., & Songyang, Z. (2006). A critical role for TPP1 and TIN2 interaction in high-order telomeric complex assembly. *Proceedings of the National Academy of Sciences of the United States of America*, *103*(32), 11874–11879. <https://doi.org/10.1073/pnas.0605303103>
9. Zvereva, M. I., Shcherbakova, D. M., & Dontsova, O. A. (2010). Telomerase: structure, functions, and activity regulation. *Biochemistry. Biokhimiia*, *75*(13), 1563–1583. <https://doi.org/10.1134/s0006297910130055>
10. Bell, R. J., Rube, H. T., Xavier-Magalhães, A., Costa, B. M., Mancini, A., Song, J. S., & Costello, J. F. (2016). Understanding TERT Promoter Mutations: A Common Path to Immortality. *Molecular cancer research: MCR*, *14*(4), 315–323. <https://doi.org/10.1158/1541-7786.MCR-16-0003>

11. Prescott, J. C., & Blackburn, E. H. (1999). Telomerase: Dr Jekyll or Mr Hyde?. *Current opinion in genetics & development*, 9(3), 368–373. [https://doi.org/10.1016/s0959-437x\(99\)80055-0](https://doi.org/10.1016/s0959-437x(99)80055-0)
12. Takakura, M., Kyo, S., Kanaya, T., Hirano, H., Takeda, J., Yutsudo, M., & Inoue, M. (1999). Cloning of human telomerase catalytic subunit (hTERT) gene promoter and identification of proximal core promoter sequences essential for transcriptional activation in immortalized and cancer cells. *Cancer research*, 59(3), 551–557.
13. Harley C. B. (2005). Telomerase therapeutics for degenerative diseases. *Current molecular medicine*, 5(2), 205–211. <https://doi.org/10.2174/1566524053586671>
14. Blasco M. A. (2005). Telomeres and human disease: ageing, cancer and beyond. *Nature reviews. Genetics*, 6(8), 611–622. <https://doi.org/10.1038/nrg1656>
15. Paul L. (2011). Diet, nutrition and telomere length. *The Journal of nutritional biochemistry*, 22(10), 895–901. <https://doi.org/10.1016/j.jnutbio.2010.12.001>
16. Targowski, T., Jahnz-Rózyk, K., Szkoda, T., From, S., Rozyńska, R., & Płusa, T. (2005). Wpływ nikotynizmu na aktywność telomerazy w niedrobnokomórkowych guzach złośliwych płuc [Influence of nicotine addiction on telomerase activity in malignant non-small cell lung tumors]. *Przeegląd lekarski*, 62(10), 1043–1046.
17. Aubert, G., & Lansdorp, P. M. (2008). Telomeres and aging. *Physiological reviews*, 88(2), 557–579. <https://doi.org/10.1152/physrev.00026.2007>
18. Epel, E. S., Blackburn, E. H., Lin, J., Dhabhar, F. S., Adler, N. E., Morrow, J. D., & Cawthon, R. M. (2004). Accelerated telomere shortening in response to life stress. *Proceedings of the National Academy of Sciences of the United States of America*, 101(49), 17312–17315. <https://doi.org/10.1073/pnas.0407162101>
19. Aviv, A., Valdes, A., Gardner, J. P., Swaminathan, R., Kimura, M., & Spector, T. D. (2006). Menopause modifies the association of leukocyte telomere length with insulin resistance and inflammation. *The Journal of clinical endocrinology and metabolism*, 91(2), 635–640. <https://doi.org/10.1210/jc.2005-1814>
20. Richards, J. B., Valdes, A. M., Gardner, J. P., Paximadas, D., Kimura, M., Nessa, A., Lu, X., Surdulescu, G. L., Swaminathan, R., Spector, T. D., & Aviv, A. (2007). Higher serum vitamin D concentrations are associated with longer leukocyte telomere length in women. *The American journal of clinical nutrition*, 86(5), 1420–1425. <https://doi.org/10.1093/ajcn/86.5.1420>
21. Haendeler, J., Hoffmann, J., Diehl, J. F., Vasa, M., Spyridopoulos, I., Zeiher, A. M., & Dimmeler, S. (2004). Antioxidants inhibit nuclear export of telomerase reverse transcriptase and delay replicative senescence

- of endothelial cells. *Circulation research*, 94(6), 768–775. <https://doi.org/10.1161/01.RES.0000121104.05977.F3>
22. Aviv, A., Chen, W., Gardner, J. P., Kimura, M., Brimacombe, M., Cao, X., Srinivasan, S. R., & Berenson, G. S. (2009). Leukocyte telomere dynamics: longitudinal findings among young adults in the Bogalusa Heart Study. *American journal of epidemiology*, 169(3), 323–329. <https://doi.org/10.1093/aje/kwn338>
  23. Cherkas, L. F., Hunkin, J. L., Kato, B. S., Richards, J. B., Gardner, J. P., Surdulescu, G. L., Kimura, M., Lu, X., Spector, T. D., & Aviv, A. (2008). The association between physical activity in leisure time and leukocyte telomere length. *Archives of internal medicine*, 168(2), 154–158. <https://doi.org/10.1001/archinternmed.2007.39>
  24. Barthel, F. P., Wei, W., Tang, M., Martinez-Ledesma, E., Hu, X., Amin, S. B., Akdemir, K. C., Seth, S., Song, X., Wang, Q., Lichtenberg, T., Hu, J., Zhang, J., Zheng, S., & Verhaak, R. G. (2017). Systematic analysis of telomere length and somatic alterations in 31 cancer types. *Nature genetics*, 49(3), 349–357. <https://doi.org/10.1038/ng.3781>
  25. Hiyama, E., & Hiyama, K. (2003). Telomerase as tumor marker. *Cancer letters*, 194(2), 221–233. [https://doi.org/10.1016/s0304-3835\(02\)00709-7](https://doi.org/10.1016/s0304-3835(02)00709-7)
  26. Hiyama, E., & Hiyama, K. (2002). Clinical utility of telomerase in cancer. *Oncogene*, 21(4), 643–649. <https://doi.org/10.1038/sj.onc.1205070>
  27. Valentijn, L. J., Koster, J., Zwijnenburg, D. A., Hasselt, N. E., van Sluis, P., Volckmann, R., van Noesel, M. M., George, R. E., Tytgat, G. A., Molenaar, J. J., & Versteeg, R. (2015). TERT rearrangements are frequent in neuroblastoma and identify aggressive tumors. *Nature genetics*, 47(12), 1411–1414. <https://doi.org/10.1038/ng.3438>
  28. Peifer, M., Hertwig, F., Roels, F., Dreidax, D., Gartlgruber, M., Menon, R., Krämer, A., Roncaioli, J. L., Sand, F., Heuckmann, J. M., Ikram, F., Schmidt, R., Ackermann, S., Engesser, A., Kahlert, Y., Vogel, W., Altmüller, J., Nürnberg, P., Thierry-Mieg, J., Thierry-Mieg, D., ... Fischer, M. (2015). Telomerase activation by genomic rearrangements in high-risk neuroblastoma. *Nature*, 526(7575), 700–704. <https://doi.org/10.1038/nature14980>
  29. Ohali, A., Avigad, S., Ash, S., Goshen, Y., Luria, D., Feinmesser, M., Zaizov, R., & Yaniv, I. (2006). Telomere length is a prognostic factor in neuroblastoma. *Cancer*, 107(6), 1391–1399. <https://doi.org/10.1002/cncr.22132>
  30. Roderwieser, A., Sand, F., Walter, E., Fischer, J., Gecht, J., Bartenhagen, C., Ackermann, S., Otte, F., Welte, A., Kahlert, Y., Lieberz, D., Hertwig, F., Reinhardt, H. C., Simon, T., Peifer, M., Ortmann, M., Büttner, R., Hero, B., O'Sullivan, R. J., Berthold, F., ... Fischer, M. (2019). Telomerase Is a Prognostic Marker of Poor Outcome and a Therapeutic Target in Neuroblastoma. *JCO precision oncology*, 3, 1–20. <https://doi.org/10.1200/>

PO.19.00072

31. Vinagre, J., Almeida, A., Pópulo, H., Batista, R., Lyra, J., Pinto, V., Coelho, R., Celestino, R., Prazeres, H., Lima, L., Melo, M., da Rocha, A. G., Preto, A., Castro, P., Castro, L., Pardal, F., Lopes, J. M., Santos, L. L., Reis, R. M., Cameselle-Teijeiro, J., ... Soares, P. (2013). Frequency of TERT promoter mutations in human cancers. *Nature communications*, 4, 2185. <https://doi.org/10.1038/ncomms3185>
32. Lindner, S., Bachmann, H. S., Odersky, A., Schaefer, S., Klein-Hitpass, L., Hero, B., Fischer, M., Eggert, A., Schramm, A., & Schulte, J. H. (2015). Absence of telomerase reverse transcriptase promoter mutations in neuroblastoma. *Biomedical reports*, 3(4), 443–446. <https://doi.org/10.3892/br.2015.463>
33. Castelo-Branco, P., Choufani, S., Mack, S., Gallagher, D., Zhang, C., Lipman, T., Zhukova, N., Walker, E. J., Martin, D., Merino, D., Wasserman, J. D., Elizabeth, C., Alon, N., Zhang, L., Hovestadt, V., Kool, M., Jones, D. T., Zadeh, G., Croul, S., Hawkins, C., ... Tabori, U. (2013). Methylation of the TERT promoter and risk stratification of childhood brain tumours: an integrative genomic and molecular study. *The Lancet. Oncology*, 14(6), 534–542. [https://doi.org/10.1016/S1470-2045\(13\)70110-4](https://doi.org/10.1016/S1470-2045(13)70110-4)
34. Nozaki, C., Horibe, K., Iwata, H., Ishiguro, Y., Hamaguchi, M., & Takahashi, M. (2000). Prognostic impact of telomerase activity in patients with neuroblastoma. *International journal of oncology*, 17(2), 341–345. <https://doi.org/10.3892/ijo.17.2.341>
35. Hiyama, E., Hiyama, K., Ohtsu, K., Yamaoka, H., Ichikawa, T., Shay, J. W., & Yokoyama, T. (1997). Telomerase activity in neuroblastoma: is it a prognostic indicator of clinical behaviour?. *European journal of cancer (Oxford, England: 1990)*, 33(12), 1932–1936. [https://doi.org/10.1016/s0959-8049\(97\)00226-8](https://doi.org/10.1016/s0959-8049(97)00226-8)
36. Streutker, C. J., Thorner, P., Fabricius, N., Weitzman, S., & Zielenska, M. (2001). Telomerase activity as a prognostic factor in neuroblastomas. *Pediatric and developmental pathology : the official journal of the Society for Pediatric Pathology and the Paediatric Pathology Society*, 4(1), 62–67. <https://doi.org/10.1007/s100240010108>
37. Poremba, C., Willenbring, H., Hero, B., Christiansen, H., Schäfer, K. L., Brinkschmidt, C., Jürgens, H., Böcker, W., & Dockhorn-Dworniczak, B. (1999). Telomerase activity distinguishes between neuroblastomas with good and poor prognosis. *Annals of oncology : official journal of the European Society for Medical Oncology*, 10(6), 715–721. <https://doi.org/10.1023/a:1008333500733>
38. Poremba, C., Hero, B., Heine, B., Scheel, C., Schaefer, K. L., Christiansen, H., Berthold, F., Kneif, S., Stein, H., Juergens, H., Boecker, W., & Dockhorn-Dworniczak, B. (2000). Telomerase is a strong indicator for assessing the proneness to progression in neuroblastomas. *Medical*

- and pediatric oncology*, 35(6), 651–655. [https://doi.org/10.1002/1096-911x\(20001201\)35:6<651::aid-mpo36>3.0.co;2-i](https://doi.org/10.1002/1096-911x(20001201)35:6<651::aid-mpo36>3.0.co;2-i)
39. Pendino, F., Tarkanyi, I., Dudognon, C., Hillion, J., Lanotte, M., Aradi, J., & Ségal-Bendirdjian, E. (2006). Telomeres and telomerase: Pharmacological targets for new anticancer strategies?. *Current cancer drug targets*, 6(2), 147–180. <https://doi.org/10.2174/156800906776056482>
  40. Herbert, BS, (2009). Disruption of telomere homeostasis as a new cancer treatment strategy, *Magazine Of European Medical Oncology (memo)*, 2: 21-24.
  41. Thompson, P. A., Drissi, R., Muscal, J. A., Panditharatna, E., Fouladi, M., Ingle, A. M., Ahern, C. H., Reid, J. M., Lin, T., Weigel, B. J., & Blaney, S. M. (2013). A phase I trial of imetelstat in children with refractory or recurrent solid tumors: a Children’s Oncology Group Phase I Consortium Study (ADV1112). *Clinical cancer research : an official journal of the American Association for Cancer Research*, 19(23), 6578–6584. <https://doi.org/10.1158/1078-0432.CCR-13-1117>
  42. Salloum, R., Hummel, T. R., Kumar, S. S., Dorris, K., Li, S., Lin, T., Daryani, V. M., Stewart, C. F., Miles, L., Poussaint, T. Y., Stevenson, C., Goldman, S., Dhall, G., Packer, R., Fisher, P., Pollack, I. F., Fouladi, M., Boyett, J., & Drissi, R. (2016). A molecular biology and phase II study of imetelstat (GRN163L) in children with recurrent or refractory central nervous system malignancies: a pediatric brain tumor consortium study. *Journal of neuro-oncology*, 129(3), 443–451. <https://doi.org/10.1007/s11060-016-2189-7>
  43. Zhang, G., Wu, L. W., Mender, I., Barzily-Rokni, M., Hammond, M. R., Ope, O., Cheng, C., Vasilopoulos, T., Randell, S., Sadek, N., Beroard, A., Xiao, M., Tian, T., Tan, J., Saeed, U., Sugarman, E., Krepler, C., Bradford, P., Sproesser, K., Murugan, S., ... Shay, J. W. (2018). Induction of Telomere Dysfunction Prolongs Disease Control of Therapy-Resistant Melanoma. *Clinical cancer research : an official journal of the American Association for Cancer Research*, 24(19), 4771–4784. <https://doi.org/10.1158/1078-0432.CCR-17-2773>
  44. Sugarman, E. T., Zhang, G., & Shay, J. W. (2019). In perspective: An update on telomere targeting in cancer. *Molecular carcinogenesis*, 58(9), 1581–1588. <https://doi.org/10.1002/mc.23035>





## ***CHAPTER 15***

### **REPRODUCTIVE SYSTEM IN FEMALE RATS**

*Volkan KOŞAL<sup>1</sup>*

---

<sup>1</sup> Van Yuzuncu Yil University, Faculty of Veterinary, Department of Artificial Insemination E-mail: volkan\_kosal@hotmail.com <https://orcid.org/0000-0001-5268-5046>

## **1.Introduction**

Rats are one of the most suitable experimental animals to study reproductive physiology. The reasons for the preference of rats in breeding studies; They reach puberty in a short time, pregnancy, lactation and estrus cycle times are short. These advantages make it preferable to use rats as a model for other mammals in reproductive studies.

## **2.Sex Difference**

Sex difference can be made in newborn rats by measuring distance between the anus and external genitalia. It is very difficult to distinguish between sexes immediately after birth. As the offspring grow, they can be separated as male if the distance between the genital area and anus is large, and as female if they are small (Sarıözkan, 2005).

## **3.Puberty in Females**

Puberty in female rats starts when they are 33-42 days old and after they reach a weight of about 100 g. Between the first 35-40 days after birth, the vaginal opening becomes evident and the first estrus is observed one week later. In this period, nucleated cells begin to be observed in vaginal cytology and the animal reaches a weight of approximately 120 g. (Ojeda and Urbanski, 1994).

## **4.Female Genital System Anatomy**

### **4.1.Mammary gland (Glandula Lactiferi)**

Female rats have a total of 6 pairs of mammary glands, 3 pairs in the thoracic region and 3 pairs in the inguinal region. Between the inguinal and thoracic mammary glands there is a narrow segment. The mammary glands are composed of lobularly arranged ducts and terminal secretory alveoli. The mammary glands are tubuloalveolar. Each mammary gland has a main lactiferous duct that opens into the nipple duct. This canal is lined by cuboidal and myoepithelial cells. (Boorman et al., 1990).

### **4.2.Ovary**

Ovaries are located caudal side of the kidneys. The ovaries are surrounded by the bursa ovarica and connected to the cornu uteri via the oviduct. The surface epithelium of the ovaries covered with single layer of squamous or cubic epithelium is called the germinal epithelium. Beneath the germinal epithelium is a dense connective tissue layer called the tunica albuginea, which gives the ovary its whitish color. In the cortex below the tunica albuginea, there are ovarian follicles containing oocytes. The follicles are embedded in the connective tissue (stroma) of the cortex. This stroma contains typical spindle-shaped fibroblasts, which respond differently to hormonal stimuli than fibroblasts of other organs. The innermost

part of the ovary is the medullary region, which contains a rich vascular system in loose connective tissue. There is no definite border between the cortex and medulla regions (Kierszenbaum, 2006).

### **4.3.Oviduct**

The oviducts begin from the infundibulum protruding into bursa ovarica. It attaches to the cornu uteri via the tuba uterina. In rats, the oviduct is divided into four sections: preampulla, ampulla, isthmus, and junctura of uterus. The wall of oviduct is composed of the tunica mucosal layer. This layer is composed of smooth muscle, ciliary epithelium, tunica adventitia and tunica muscularis (Del Vecchio, 1992).

### **4.4.Uterus**

Rats have a duplex uterus. The uterus consists of a single structure, the cornular is bilaterally symmetrical. The lumens of the cornu uteri are separate, the portio vaginalis opens into the vagina through the uteri and the cervix. The uterine body and vagina lie between the rectum dorsally and the urinary bladder ventrally. It consists of mucosa (endometrium), two layers of smooth muscle (myometrium) and adventitia. It forms a single row of columnar epithelial cells and endometrial uterine glands that form the surface of the mucosa (Tamada et al., 1997; Chakraborty et al., 1988).

### **4.5.Vagina**

The vagina; opens to the outside just below the anus, separate from the urethra. Females who have not reached puberty have a membrane or plug in the vagina. This membrane, called the epithelial septum, begins to dissolve in 20-35 days. In animals that are 70 days old on average, signs of estrus begin and the first estrus is observed at 75-80 days. The vagina is covered with a layer of squamous epithelium, which varies according to the period of the estrous cycle. (Hebel & Stromberg, 1986).

### **5.Estrus Cycle**

Rats are non-seasonal polyestric animals, showing estrus every 5-7 days throughout the year unless they become pregnant. With the opening of the vagina as a result of estrogenic stimulation, puberty and proestrus begin at 28-42 days. Irregular estrus begins to be observed in animals at about 10-12 months, and female rats persistent diestrus is observed at 12-15 months (Bennet & Vickery, 1970).

The estrous cycle; lasts about 4-5 days; It consists of 4 phases: proestrus, estrus, metestrus, and diestrus. Proestrus lasts about 12 hours, estrus 12-24 hours, metestrus 6-8 hours, and diestrus 52-60 hours. Since different cells are observed in the vaginal smear in the diestrus phase, it is classified as diestrus 1 (D1) and diestrus 2 (D2). Lighting programs applied in the es-

trus cycle have an effect. The estrus period lasts for an average of 4 days in 12 hours of darkness and 12 hours of light, and 5 days in an average of 16 hours of light and 8 hours of darkness. (Blandou & Young, 1939; Campell & Schwartz, 1980; Fischer et al., 1986)

### **6.Hormonal Mechanism of the Estrus Cycle**

FSH and LH fluctuations secreted from the anterior pituitary with the release of gonadotropin regulate the changes in the ovaries and follicles. The fluctuations that occur during LH release are highest in proestrus phase and lowest in estrus phase. Ovulation of the preovulatory follicles and subsequent corpus luteum formation is stimulated by the LH surge during proestrus. The growth of small follicles occurs with two preovulatory FSH surges. The first of this fluctuation is related to the LH wave, while the second is related to the decrease of inhibin hormone after ovulation. Follicular development is related to the increase of estradiol-17 $\beta$ . Estradiol levels are low in metestrus and early diestrus. It starts to increase towards the 2nd half of diestrus. During the proestrus phase, the serum estradiol level starts to increase suddenly, stimulating ovulation, and decreases again at the end of the phase. The proestrus phase is followed by the estrus phase. During the estrous phase, the serum estradiol level is still low and does not change. Although progesterone secretion is slightly higher in the meestrus phase, it decreases early in the diestrus phase and peaks in the second half of the proestrus phase (Ackland et al., 1990; Foster & Gray, 2010; Peters & McNatty, 1980).

After mating, the LH level remains low, while the FSH level starts to increase again. Prolactin, which continues at basal level throughout the cycle, also shows pulsatile increases. In unmated animals, the prolactin level remains at basal level. Prolactin level rises after mating, while the formed corpus luteum degenerates after 2 days (Peters & McNatty, 1980).

**Table 1.** *Changes in vagina, uterus and ovary according to estrus phase (Westwood, 2008).*

<b>Estrus phase</b>	<b>Vagina</b>	<b>Uterus</b>	<b>Ovary</b>
Diestrus	<p>Low level of epithelial cell layer</p> <p>Leukocyte infiltration</p> <p>Epithelial thickening following disruption of leukocyte infiltration</p>	<p>The small, avascular lumen is lined by columnar epithelial cells.</p> <p>Degenerate cells can be observed</p> <p>Stromal edema towards the end of diestrus</p>	<p>Large corpus luteum</p>
Proestrus	<p>Mitotic cells begin to appear</p> <p>Degeneration and desquamation of cells begin</p> <p>The stratum granulosum begins to be covered by the superficial mucoid layer and the stratum corneum</p> <p>Cornified cells are observed at the end of the stage</p>	<p>The epithelial layer is lined with cuboidal and columnar epithelial cells.</p> <p>No degeneration or infiltration of epithelial cells</p> <p>Dilation begins towards the end of the phase</p>	<p>Corpus luteum lysed</p> <p>Cytoplasmic vacuoles are observed</p>
Estrus	<p>Increase in superficial cells</p> <p>Mucoid layer and cornification</p> <p>Leukocyte cell infiltration</p>	<p>Cell degeneration and necrosis at the onset of estrus</p> <p>Leukocyte cell infiltration</p> <p>Dilation until the end of estrus</p>	<p>Degenerated corpus luteum</p> <p>Central basophilic cells and small fluid-filled corpus luteums may be observed.</p>
Metestrus	<p>The cornified layer is completely separated from the lumen</p> <p>Desquamation of the stratum granulosum and germinativum layers</p> <p>leukocyte cell infiltration</p>	<p>Degeneration of endometrial epithelial cells</p>	<p>Corpus luteum begins to enlarge but is smaller than during diestrus</p> <p>Few basophilic cells are seen.</p>

## 7. Corpus Luteum

The corpus luteum (CL) is formed by series of biochemical and morphological changes in the preovulatory follicle, which is defined as luteinization after ovulation with the LH peak. LH and Prolactin are responsible for the formation of the Corpus luteum in rats. Prolactin is a stimulator of LH receptor expression in granulosa cells, and PRL receptors play an important role in the regulation of luteal functions. In the first stage of ovulation, the basement membrane of the Graafian follicle ruptures and turns into a temporary endocrine gland. With the ovulation of the follicle, the follicle fluid is also emptied, and the estrogen level in the blood decreases. Structural changes begin with the effect of LH and PRL hormones secreted from the pituitary. In this area, the corpus luteum develops and secretes many hormones, mainly progesterone. Progesterone hormone secreted by the corpus luteum; It stops the pituitary from secreting FSH, thus preventing the development of new primary follicles in the ovarian cortex. If fertilization has not occurred; The CL begins to regress after a few days, shrinks, and is called Corpus albicans (Accialini et al., 2016; Ross & Wojciech, 2011).

In female rats, there are 4 different types in terms of corpus luteum formation period, life span and steroidogenic capacity. Cyclic corpus luteum, pregnancy corpus luteum, pseudopregnancy corpus luteum and lactation corpus luteum (Gibori et al., 1988).

## 8. Reproductive Behavior in Females

### Lordosis Behavior

Lordosis behavior is characterized by dorsiflexia of the vertebral vertebrae (Pfaff, 1980). In order for the lordosis reflex to occur, high levels of ovarian steroids such as progesterone and estrogen are required. The presence of estrogen alone is sufficient for the formation of the lordosis reflex (Sakuma, 1997).

### 9. Pregnancy

The gestation period in the rat is 20-22 days. Despite the presence of large and medium-sized follicles on the ovary during pregnancy in rats, they cannot ovulate and produce steroids because they are not physiologically mature (Miyamoto et al., 1987).

The prolactin surges induced by coitus in the first half of pregnancy increase the secretion of progesterone from the ovary. After the second half of pregnancy, progesterone also begins to be secreted from the placenta. While the progesterone level decreases in the fetus after the 18th day, it decreases in the mother on the 20-21 days. During pregnancy, estrogen

secretion from the ovaries continues, thus ensuring the continuity of the corpus luteum. Estrogen plays a key role in the development and implantation of the embryo, and the estrogen level peaks at 3-11 days (Weisz and Ward, 1980; Peters and McNatty, 1980).

## **10. Neuroendocrine Mechanisms**

Two main GnRH neuronal systems effective in the rat brain: one of them is terminal nervous system and the other is the preoptic system (Schwanzel-Fukuda, 1997). Preoptic GnRH neurons stimulate hormone release from the anterior pituitary lobe. Preoptic GnRH neurons connect to the media eminence from the lower part of the hypothalamus. There is a pulsatile release of GnRH from the media eminence to the pituitary portal vessels. LH and FSH secreted from anterior pituitary lobe; It performs follicular development and stereodogenesis in the ovaries. The level of GnRH and LH secretion depends on the amount of estrogen secreted from the developing and developed follicles (Kawano, 1981).

Environmental stimuli such as nutrition, stress, or lactation affect gonadal activities and secretion of steroid hormones, but have no effect on LH. This is because periovulatory estrogen level does not affect LH secretion during lactation. (Maeda et al., 1995; Tsukamura et al., 1988; Nishihara et al., 1997).

## **11. Placenta**

The rat has two placental structures; the chorioallantoic placenta and the choriovitelline placenta. Choriovitelline placenta consists of trophoblast cells attached to the basement membrane. Choriovitelline placenta degenerates and disappears on the 14th day of pregnancy. The chorioallantoic placenta is located in the mesometrial region of the uterus. It consists of two regions, the junctional and the labyrinth. These regions consist of trophoblast cells and maternal vascular channels (Soares et al., 1998).

## **12. Female Reproductive Hormones**

### **12.1. Hypothalamus**

#### **GnRH**

Gonadotropin Releasing Hormone (GnRH) is a polypeptide hormone consisting of 10 amino acids (Matsuo et al., 1971). The amino acid sequence of GnRH is the same in all mammals (Sherwood et al., 1993). It is synthesized by neurons in the medial preoptic area, medial septum, and diagonal broca band in the hypothalamus. It stimulates the release of LH and FSH from the anterior pituitary gland. It stimulates Ca mobilization and inositol triphosphate by binding to the G protein of Gonadotroph cells in the anterior pituitary lobe (Moenter et al., 1992).

## **12.2.Pituitary Gland**

### **12.2.1.Anterior Pituitary**

#### **Luteinizing Hormone (LH)**

Luteinizing Hormone (LH) is a 32kDa glycoprotein hormone (Combarous, 1992). It is produced and secreted by gonadotroph cells located in the anterior pituitary lobe. LH acts on the gonads in females and males, stimulating steroid synthesis from the ovaries and testicles. LH binds to the G protein in the gonads to produce cyclic AMP (Norris, 1996).

#### **Follicle Stimulating Hormone (FSH)**

Follicle Stimulating Hormone (FSH) is a 32kDa glycoprotein hormone. It is produced and secreted by gonadotroph cells located in the anterior pituitary lobe. It is responsible for follicular development in females and stimulation of spermatogenesis in males. It acts by binding to the FSH G receptor. FSH receptors are strung on c DNA. Inhibin and activin secretion, as well as GnRH released from the hypothalamus, have an effect on FSH secretion (Combarous, 1992).

#### **Prolactin (PRL)**

Prolactin (PRL) hormone is a peptide structure consisting of 198 amino acids released from lactotroph cells. Prolactin is involved in reproduction, water and electrolyte balance, growth and development and body functions in different species. It has effect on mammary gland, pseudopregnancy, pregnancy, lactation, luteal function, progesterone secretion in rats. There are two different forms of prolactin, short and long. These forms are synthesized by cDNA. Prolactin receptors do not have kinase activity. Its release is regulated by a hypothalamic inhibitory mechanism (Freeman, 1994; Meites, 1988; Imura, 1994).

### **12.2.2.Posterior Pituitary**

#### **Oxytocin**

Oxytocin is a peptide neurohormone consisting of 9 amino acids. It is produced by magnocellular neurons in the supraoptic nucleus (SON) and paraventricular nucleus (PVN) of the hypothalamus (Jirikowski et al., 1988). Stimulation of smooth muscles in the uterus induces contraction of myoepithelial cells, mammary alveoli and mammary gland development and milk secretion (Wakerley et al., 1994).

#### **Vasopressin**

Vasopressin; This hormone, also known as arginine vasopressin (AVP), consists of 9 amino acids and has a peptide structure. Like oxytocin, it is produced by magnocellular neurons in the supraoptic nucleus



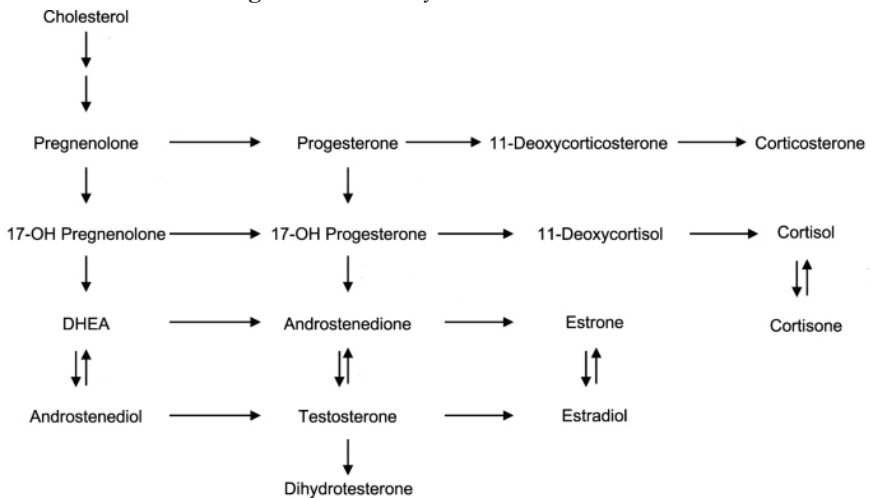
(SON) and paraventricular nucleus (PVN) of the hypothalamus. Its main feature is antidiuretic hormone, it takes part in blood osmolarity and blood pressure (Jirikowski et al., 1988).

### 12.3.Ovary

#### 12.3.1.Steroid Hormones

Steroid hormones have a structure consisting of 4 carbon rings. They originate from cholesterol. The main source of cholesterol is lipoproteins (GoreLantgon and Armstrong, 1994). Steroid hormones cross the cell membrane and bind to the nucleic receptor on the nucleus. The resulting receptor complex acts on DNA and supports mRNA synthesis. (Carson-Jurica et al., 1990; Evans, 1988).

Figure 1. Steroid synthesis mechanism.



(Chakraborty, 2021)

### Estrogen

Estrogens are converted from androgens through an enzymatic reaction (aromatization). It is synthesized from the granulosa cells of the Graafian follicle. There are 3 different natural forms of estrogen; estrone, estradiol and estradiol 17-Beta. It is effective on follicular growth and development, mammary glands, and lordosis behavior (Ramirez et al., 1965; Bayard et al., 1995).

### Progesterone

There are 21 carbon atoms in the structure of the progesterone hormone, and there is a double methyl group in the 10th and 13th row of

these carbon atoms. Progesterone hormone is synthesized from the corpus luteum and a small amount from the adrenal cortex. In rats, unlike other animal species, progesterone is not synthesized from the placenta during pregnancy. (Heap & Flint, 1984).

### **12.3.2. Non-steroid Hormones**

#### **Inhibin and Activin**

Inhibin and activin are glycoprotein hormones secreted from granulosa cells in the ovary. Activins act by interacting with two types of cell surface transmembrane receptors (Types I and II). Activin has intrinsic serine/threonine kinase activities in their cytoplasmic domains. The mechanism of action of inhibin is not fully known. Inhibin inhibits FSH release, and activin stimulates FSH release (Sarıbay & Doğruer 2015).

#### **Follistatin**

Follistatin, also known as activin binding protein, is a single-chain polypeptide structure. It is an endogenous activin inhibitor. It has FSH secretion inhibitory property (Sarıbay & Doğruer 2015).

### **12.4. Uterus**

#### **Prostaglandin**

Prostaglandins are a lipid hormone that originates from arachidonic acid and can be synthesized from many tissues of the body. There are many different subtypes (A, B, C, D, E, F, I). Form E, F and D are primary prostaglandin types. The most important form in reproduction is PGF<sub>2</sub>α. It regulates the lifespan of the corpus luteum and is responsible for its luteolysis. (Smith et al., 1991; Mitchell & Trautman, 1993). In non-pregnant rats, PGF<sub>2</sub>α secreted from the uterus passes into the ovarian artery by diffusion, causes constriction in the uterus and ovarian vessels, prevents the feeding of luteal cells and enables luteolysis to occur (Ford, 1982; Reynolds, 1986; Milvae, 2000).

### **12.5. Placenta**

#### **Placental Lactogen**

Rats have two different forms of placental lactogen; placental lactogen I (PL-I) and II (PL-II). PL-I, a glycoprotein secreted as a heterogeneous complex (36–42 kDa), is mainly found in plasma during midgestation, PL-II (25 kDa) is not glycosylated and is predominantly secreted in the second half of pregnancy. It stimulates progesterone synthesis from the corpus luteum, insulin secretion and cell proliferation in the pancreas during pregnancy (Soares et al., 1991; Robertson et al., 1982).

## References

- Accialini, P., Hernandez, S., Abramovich, D. & Tesone, M. (2016). The Life Cycle of the Corpus Luteum. Meidan R (ed.), *The Rodent Corpus Luteum* (117-131). Springer, Cham, Switzerland.
- Ackland, J. F., D'Agostino, J., Ringstrom, S. J., Hostetler, J. P., Mann, B. G., & Schwartz, N. B. (1990). Circulating radioimmunoassayable inhibin during periods of transient follicle-stimulating hormone rise: secondary surge and unilateral ovariectomy. *Biology of reproduction*, 43(2), 347–352. <https://doi.org/10.1095/biolreprod43.2.347>.
- Bennet, J.P. & Vickery, B.H. (1970). Rats and Mice. Hafez E.S.E. (ed.). *Reproduction and Breeding Techniques for Laboratory Animals* (Chapter 17). Lea & Febiger, Philadelphia..
- Blandau, R.J. & Young, W.C. (1939). The effects of delayed fertilization on the development of the guinea pig ovum. *American Journal of Anatomy*, 64, 303-329.
- Boorman, G.A., Morgan, K.T. & Uria, L.C. (1990). *Pathology of the Fischer Rat*, (315-337). Academic Press, San Diego, USA.
- Campbell, C.S. & Schwartz, N.B. (1980). The impact of constant light on the estrous cycle of the rat. *Endocrinology*, 106 (4), 1230-1238.
- Carson-Jurica, M. A., Schrader, W. T., & O'Malley, B. W. (1990). Steroid receptor family: structure and functions. *Endocrine reviews*, 11(2), 201–220. <https://doi.org/10.1210/edrv-11-2-201>
- Chakraborty, C., Tawfik, O.W. & Dey, S.K. (1988). Epidermal growth factor binding in rat uterus during the peri-implantation period. *Biochem Biophys Res Commun*, 153, 564–569.
- Chakraborty, S., Pramanik, J. & Mahata, B. (2021). Revisiting steroidogenesis and its role in immune regulation with the advanced tools and technologies. *Genes & Immunity*. 22: 1-16. [10.1038/s41435-021-00139-3](https://doi.org/10.1038/s41435-021-00139-3).
- Combarrous, Y. (1992). Molecular basis of the specificity of binding of glycoprotein hormones to their receptors. *Endocrine reviews*, 13(4), 670–691. <https://doi.org/10.1210/edrv-13-4-670>.
- Del Vecchio, E.R. (1992). Mohr, U., Dungworth, D.L. & Capen, C.C. (ed.) *Pathobiology of the Aging Rat*, (331-336). Washington PC: ILSI Press.
- Evans, R.M. (1988). The steroid and thyroid hormone receptor superfamily. *Science (New York, N.Y.)*, 240(4854), 889–895. <https://doi.org/10.1126/science.3283939>
- Bayard, F., Clamens, S., Meggetto, F., Blaes, N., Delsol, G. & Faye, J.C. (1995). Estrogen synthesis, estrogen metabolism, and functional estrogen receptors in rat arterial smooth muscle cells in culture. *Endocrinology*, 136(4), 1523–1529, <https://doi.org/10.1210/endo.136.4.7895662>.

- Fischer, B., Winterhager, E. & Bush, L.C. (1986). Transformation of endometrium and fertility in the late stages of pseudopregnancy in the rabbit. *Journal of Reproduction and Fertility*, 78(2), 529-540.
- Ford, S.P. (1982). Control of uterine and ovarian blood flow throughout the estrous cycle and pregnancy of ewes, sows and cows. *Journal of Animal Science*, 55, 32-42.
- Foster, P.M.D. & Gray, Jr E. (2010). Toxic Responses of the Reproductive System. Klaassen CD, Watkins JB (ed.). *Casarett & Doull's Essentials of Toxicology* (279-293). Mc Graw Hill, New York, USA.
- Freeman, M.E. (1994). Knobil, E. & Neill, J.D. (ed.) *The Physiology of Reproduction* (613-658). New York: Raven Press.
- Gibori, G., Khan, I., Warshaw, M. L., McLean, M. P., Puryear, T. K., Nelson, S., Durkee, T. J., Azhar, S., Steinschneider, A., & Rao, M. C. (1988). Placental-derived regulators and the complex control of luteal cell function. *Recent progress in hormone research*, 44, 377-429. <https://doi.org/10.1016/b978-0-12-571144-9.50016-8>.
- Gore-Langton, R.E. & Armstrong, D.T. (1994) Knobil, E. & Neill, J.D. (ed.) *The Physiology of Reproduction* (571-627). New York: Raven Press.
- Heap, R.B. & Flint, A.E.E. (1984). Austin, C.R. & Short, R.V. (ed.) *Hormonal Control of Reproduction* (153-194). Cambridge: Cambridge University Press.
- Hebel, R. & Stromberg, M.W. (1986). *Anatomy and Embryology of the Laboratory Rat*. Woerthsee: BioMed Verlag.
- Imura, H. (1994). *The Pituitary Gland*. New York: Raven Press.
- Jirikowski, G.E., Caldwell, J.D., Pedersen, C.A. & Stumpf, W.E. (1988) Estradiol influences oxytocin-immunoreactive brain systems. *Neuroscience*, 25, 237-248.
- Kawano, H. & Daikoku, S. (1981). Immunohistochemical demonstration of LHRH neurons and their pathways in the rat hypothalamus. *Neuroendocrinology*, 32, 179-186.
- Kierszenbaum, A.L. (2006). *Histoloji ve Hücre Biyolojisi, Folikül gelişimi ve Menstrual Döngü* (566-572). Palme Yayıncılık, Ankara.
- Sarıbay M.K. & Doğruer G. (2015). Activin, Follistatin and Inhibin. *Türkiye Klinikleri J Vet Sci Obstet Gynecol-Special Topics*, 1(2), 126-33.
- Maeda, K.I., Tsukamura, H., Ohkura, S. & Yokoyama, A. (1995). The LHRH pulse generator: a mediobasal hypothalamic location. *Neurosci Biobehav Rev*, 19, 427-437.
- Matsuo, H., Baba, Y., Nair, R. M., Arimura, A., & Schally, A. V. (1971). Structure of the porcine LH- and FSH-releasing hormone. I. The proposed amino acid sequence. *Biochemical and biophysical research communications*, 43(6), 1334-1339. [https://doi.org/10.1016/s0006-291x\(71\)80019-0](https://doi.org/10.1016/s0006-291x(71)80019-0).

- Meites, J. (1988) Hoshino, K. (ed.) *PRL Gene Family and its Receptors* (123-130). Amsterdam: Elsevier
- Milvae, R.A. (2000). Inter-relationships between endothelin and prostaglandin F<sub>2</sub> $\alpha$  in corpus luteum function. *Reviews of Reproduction*, 5, 1-5.
- Mitchell, M.D. & Trautman, M.S. (1993). Molecular mechanisms regulating prostaglandin action. *Mol Cell Endocrinol*, 93, C7-C10.
- Miyamoto, H., Yoshida, E., Otsuka, Y. & Ishibashi, T. (1987). Ovarian Follicular Development in the Pregnant Rat. *Japanese Journal of Animal Reproduction*, 3, 117-122.
- Moenter, S. M., Brand, R. M., Midgley, A. R., & Karsch, F. J. (1992). Dynamics of gonadotropin-releasing hormone release during a pulse. *Endocrinology*, 130(1), 503–510. <https://doi.org/10.1210/endo.130.1.1727719>.
- Nishihara, M., Yoo, M.J. & Takahashi, M. (1997). Maeda, K.I., Tsukamura, H. & Yokoyama, A. (ed.) *Neural Control of Reproduction: Physiology and Behavior* (31-55). Tokyo/Basel: Japan Scientific Societies Press/ Karger.
- Norris, D.O. (1996). *Vertebrate Endocrinology* (144-150). San Diego, Academic Press.
- Ojeda, S.R. & Urbanski, H.E. (1994). Knobil, E. & Neill, J.D. (ed.). *The Physiology of Reproduction* (363-409). New York: Raven Pres.
- Peters, H. & McNatty, K.P. (1980). *The Ovary: A Correlation of Structure and Function in Mammals* (5-28). Univ of California Press, USA.
- Pfaff, D.W. (1980). *Estrogens and Brain Function* (169-207). New York, Springer.
- Reynolds, L.P. (1986). Utero-ovarian interactions during ear pregnancy: role of conceptus-induced vasodilation. *Journal of Animal Science*, 62, 47- 61.
- Robertson, M. C., Gillespie, B., & Friesen, H. G. (1982). Characterization of the two forms of rat placental lactogen (rPL): rPL-I and rPL-II. *Endocrinology*, 111(6), 1862–1866. <https://doi.org/10.1210/endo-111-6-1862>
- Ross, M. & Wojciech, P. (2011). *Histology: A Text and Atlas: With Correlated Cell and Molecular Biology*. Wolters Kluwer/Lippincott Williams & Wilkins Health, USA.
- Sakuma, Y. (1997). Maeda, K.I., Tsukamura, H. & Yokoyama, A. (ed.). *Neural Control of Reproduction: Physiology and Behavior* (155-164). Tokyo/Basel, Japan Scientific Societies Press, Karger.
- Schwanzel-Fukuda, M. (1997). Parhar, I. & Sakuma, Y. (ed.). *GnRH Neurons: Gene to Behavior* (221-242). Tokyo, Brain Shuppan.
- Sarıözkan, S. (2005). Reproduction in Laboratory Animals. *Lalahan Hay Araşt Enst Derg*, 45 (1) 33 – 39.
- Sherwood, N. M., Lovejoy, D. A., & Coe, I. R. (1993). Origin of mammalian gonadotropin-releasing hormones. *Endocrine reviews*, 14(2), 241–254. <https://doi.org/10.1210/edrv-14-2-241>.

- Smith, W. L., Marnett, L. J., & DeWitt, D. L. (1991). Prostaglandin and thromboxane biosynthesis. *Pharmacology & therapeutics*, 49(3), 153–179. [https://doi.org/10.1016/0163-7258\(91\)90054-p](https://doi.org/10.1016/0163-7258(91)90054-p)
- Soares, M.J., Faria, T.N., Roby, K.F. & Deb, S. (1991). Pregnancy and the prolactin family of hormones: Coordination of anterior pituitary, uterine, and placental expression. *Endocr Rev*, 12, 402-423.
- Soares, M. J. , Muller, H. , Orwig, K. E. , Peters, T. J. & Dai, G. (1998). The uteroplacental prolactin family and pregnancy. *Bio Reprod*, 58, 273–284.
- Tamada, H., Sakamoto, M., Sakaguchi, H., Inaba, T. & Sawada, T. (1997). Evidence for the involvement of transforming growth factor- $\alpha$  in implantation in the rat. *Life Sci*, 60, 1515-1522.
- Tsukamura, H., Maeda, K.I. & Yokoyama, A. (1988). Effect of the suckling stimulus on daily LH surges induced by chronic oestrogen treatment in ovariectomized lactating rats. *J Endocrinol*, 118, 311-316
- Ramirez ,V.D. & Sawyer, C.H. (1965). Advancement of Puberty in the Female Rat by Estrogen, *Endocrinology*, 76(6), 1158–1168. <https://doi.org/10.1210/endo-76-6-1158> .
- Wakerley, J.B., Clarke, G. & Summerlee, A.J.S. (1994). Knobil, E. & Neill, J.D. (ed.) *The Physiology of Reproduction* (1131-1177). New York: Raven Press
- Weisz, J. & Ward, I.L. (1980). Plasma Testosterone and Progesterone Titters of Pregnant Rats, Their Male and Female Fetuses, and Neonatal Offspring. *Endocrinology*, 106(1), 306-316.
- Westwood, F.R. (2008). The female rat reproductive cycle: a practical histological guide to staging. *Toxicologic pathology*, 36(3), 375–384. <https://doi.org/10.1177/0192623308315665>.



## **CHAPTER 16**

### **IS THE ENERGY OF THE FEED GOING INTO THE AIR?**

*Cahit ÖZCAN<sup>1</sup>, Mehmet IRMAK<sup>2</sup>*

---

1 Assist. Prof. Department of Animal Nutrition and Nutritional Diseases, Faculty of Veterinary Medicine, Siirt University, 56100 Siirt, Turkey; cahitozcan@siirt.edu.tr; <http://orcid.org/0000-0002-1047-5347>.

2 Assist. Prof. Department of Animal Nutrition and Nutritional Diseases, Faculty of Veterinary Medicine, Siirt University, 56100 Siirt, Turkey; mehmet.irmak@siirt.edu.tr; <https://orcid.org/0000-0003-3988-2859>.

## INTRODUCTION

More than half of the organic matter in the world is of plant origin and consists of cellulose structures. The aim of ruminant nutrition is to provide ruminants with cellulose and non-protein nitrogenous compounds that humans cannot utilize as food. As a result, animal products such as meat, milk, fleece, etc. are obtained from animals and it is clearly seen that animal production has an important place in the food chain (Kuenzle and Jenny, 1979). Ruminants digest these substances through micro-organisms living symbiotically in the digestive tract, especially those concentrated in the rumen. Rumen flora consists of bacteria, archaea, protozoa, fungi and bacteriophages. Rumen flora is important in the breakdown of lignocellulosic structures. Thanks to the microbial flora in the rumen, carbohydrates such as cellulose are degraded and short chain fatty acids (SCFA), carbon dioxide, methane, microbial, proteins and ammonia are obtained. SCFAs participate in energy metabolism and meet up to 75% of energy needs (Faverdin, 1999). Microbial proteins and vitamins produced by microorganisms are important in ruminant nutrition (Bryant, 1959). Methane (CH<sub>4</sub>) formed as a result of ruminal fermentation is an environmental problem as it is a much more harmful greenhouse gas than CO<sub>2</sub>. Since methane is a high energy gas thanks to the H<sup>+</sup> ions it contains, 2-12% of the energy intake is lost as methane gas. For this reason, the issue becomes very important in terms of animal nutrition.

### *Why Methane Matters?*

The most harmful of the end products of ruminal fermentation is methane gas, which has 28 times more greenhouse effect than carbon dioxide (Gerber et al., 2013). UNFCCC (1998) was signed by many countries to combat global warming and climate change and to reduce the emission of greenhouse gases. Turkey took its place among these countries by signing the agreement in 2009. The Kyoto protocol continued until 2020 and it is expected that enough countries will sign for the second commitment period. Within the framework of this protocol, countries aim to combat climate change by making commitments to reduce greenhouse gas emissions.

### *The Greenhouse Effect*

Due to the atmosphere of various gases around the Earth, it reflects some of the radiation coming from the sun back into space. In doing so,



it converts the incoming short-wavelength radiation into long-wavelength radiation and in the meantime, it gives energy from its structure. The radiation that cannot be reflected reaches the earth and is reflected from there. In the meantime, some of the radiation is absorbed by the greenhouse gases in the atmosphere both before it reaches the earth and when it is reflected back, and these gases continue to emit this radiation at the same time. In this way, our world can remain at temperatures that allow human life to survive (Selici et al., 2008). This is called the greenhouse effect. The most important greenhouse gases are water vapor (H<sub>2</sub>O), methane (CH<sub>4</sub>), diazotmonoxide (N<sub>2</sub>O), carbon dioxide (CO<sub>2</sub>) and ozone (O<sub>3</sub>) (Türkeş, 2001).

Due to the increasing world population and developing technology, the production of greenhouse gases on earth has gradually increased and the amount and proportions of natural greenhouse gases in the atmosphere have changed. This change has disrupted the balance between the levels of energy received and reflected from the sun, causing less energy to be reflected outside the earth and causing the earth to heat up more.

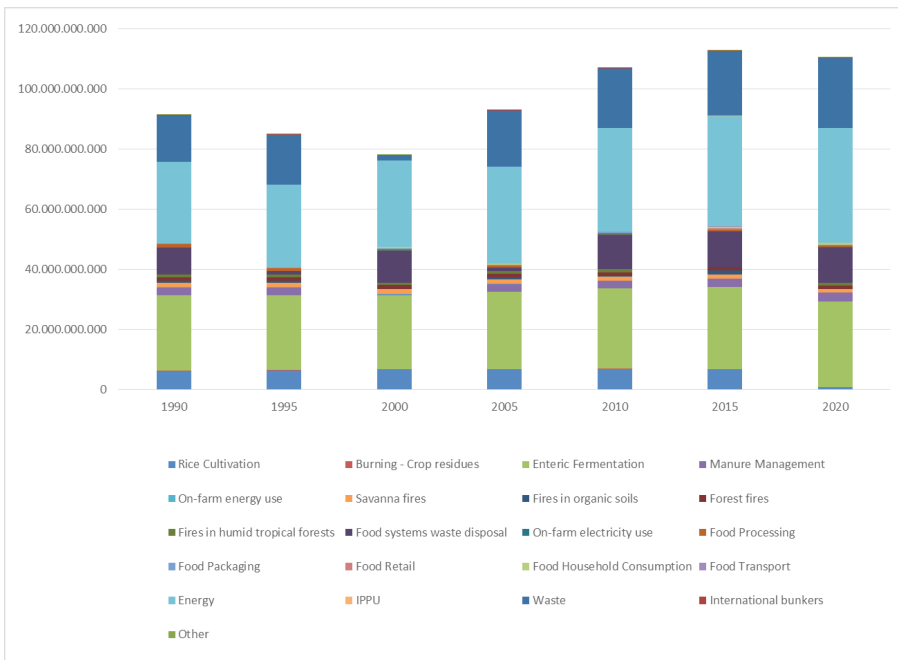
### ***Methane Emission Sources***

The amount of methane emitted from greenhouse gas emission sources monitored worldwide is shown in the Chart of greenhouse gases of the Turkish Statistical Institute (FAO 2022). Rice cultivation, Burning - Crop residues, enteric Fermentation, Manure Management, On-farm energy use, Savanna fires, Fires in organic soils, Forest Fires, Fires in humid tropical forests, Food systems waste disposal, On-farm electricity use, Food Processing, Food Packaging, Food Retail, Food Household Consumption, Food Transport, Energy, IPPU, Waste, International Bunkers and Other sources has investigated. When all these topics that have an impact on methane formation globally are examined, the highest amount in proportional and mathematical terms is Energy, Enteric Fermentation, Waste, Food Systems, respectively. Especially the studies on enteric fermentation by animal nutrition scientists are in an increasing trend.

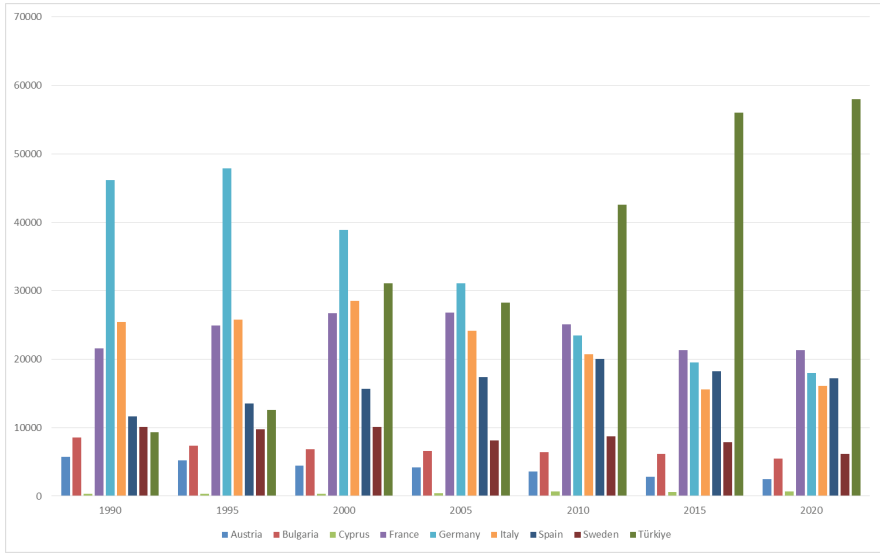
When methane emissions by country are analyzed in Graph 1 (FAO, 2022), it is seen that they vary according to technological developments, increasing population, and the amount of product obtained from unit animal.

Waste production in the world has increased in many areas, especially plastic-based garbage. As a result, waste methane emission is the highest part of emissions. Graph 2 shows the methane emissions generated by different countries in the world due to their wastes. It is seen that developing countries are not yet at a sufficient level in waste management. It can also be said that the Kyoto protocol contributes to the reduction of emissions until 2020. Graph 3 shows that the amount of methane produced as a result of the incineration of agricultural wastes is gradually decreasing. When

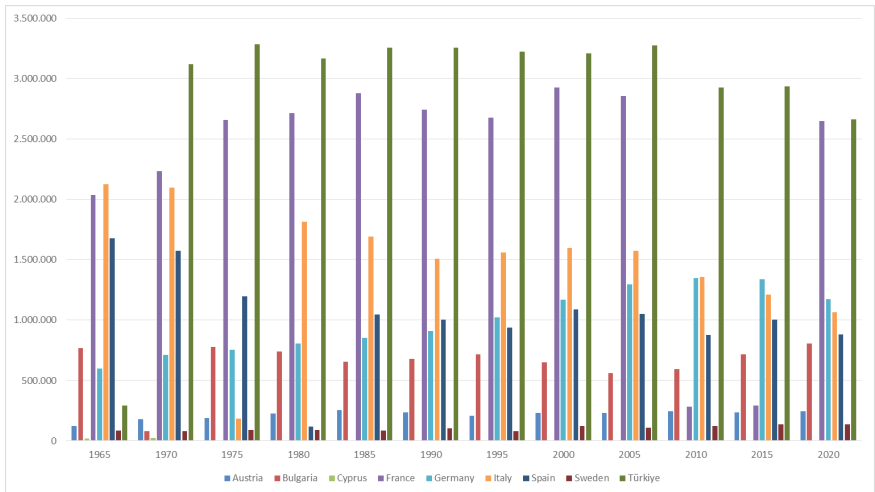
Graph 4 is analyzed, a significant decrease in enteric methane emissions is observed in almost all countries in recent years. This situation can be considered as a result of increasing scientific activities to obtain more yield from unit animals (Johnson et al., 1993; Johnson and Johnson, 1995). On the other hand, considering the growing world population and increasing needs, it is seen that emission figures will cause problems in the long term. Graph 5 shows the distribution of methane emissions from fertilizers, which is another type of agricultural methane emissions, by countries and long years. Especially in countries where pasture-based animal husbandry model is widely practiced, it is seen that manure methane emission has partially decreased (Gonzalez and Ruiz-Suraez, 2001; Boadi et al., 2004).



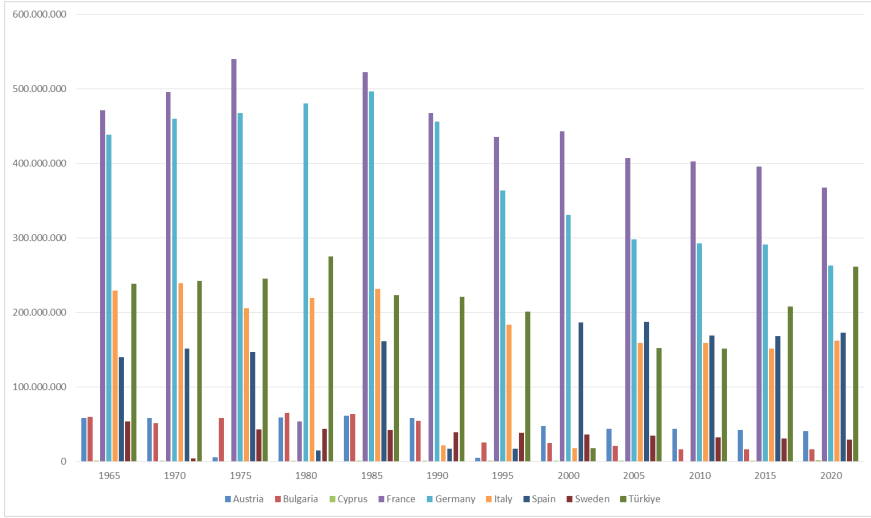
Graph 1: World Methane Emissions (CO2eq) from CH4 / Kilotonnes.



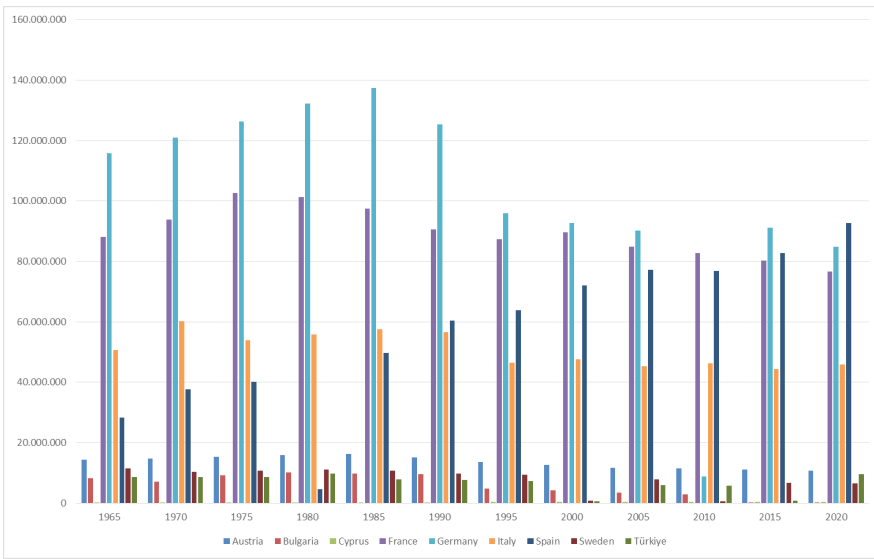
Graph 2: Methane Emissions from Waste (CO2eq) from CH4 / Kilotonnes.



Graph 3: Burning - Crop Residues (CO2eq) from CH4 / Kilotonnes.



Graph 4: Enteric Fermentation Emissions (CO2eq) from CH4 /Kilotonnes



Graph 5: Manure Management Emissions (CO2eq) from CH4 /Kilotonnes

### ***Utilization of Methane in Energy Production:***

According to Öztürk (2008), the concentration of CH<sub>4</sub> in the atmosphere increases 1-2% per year and methane gas causes about 18% of global warming. The calorific value of pure methane gas is 33,810 kJ/m<sup>3</sup> and 1 m<sup>3</sup> of methane produces energy equivalent to 0.8 L of diesel fuel when burned in internal combustion engines. When methane gas is burned in internal combustion engines to generate electricity, approximately 2.48 kilowatts of energy is obtained from 1 m<sup>3</sup> of methane gas (Öztürk, 2008). According to the methane emission inventory while methane gas emission CO<sub>2</sub> equivalent was 29.21 million tons in 1990, it increased by 49.2% to 54.38 million tons in 2007.

Despite this increase, emissions from agricultural activities accounted for 62.78% of total methane emissions in 1990, while this rate decreased to 33.48% in 2007. This proportional change is due to the increase in methane emissions from solid waste landfills.

### ***Methane for Animal Nutrition***

The vast majority of carbohydrates found in nature are cellulosic. Since the digestion of these structures is limited in monogastrics, ruminants pave the way for quality animal protein production without causing nutrient competition. Methane (CH<sub>4</sub>) is formed as a by-product of ruminal digestion of cellulose-rich feeds in ruminants. The breakdown of cellulose by cellulolytic bacteria and protozoa in the reticulo rumen releases carbon dioxide (CO<sub>2</sub>) and hydrogen (H<sub>2</sub>) into the environment. Methanogenic bacteria colonize in the rumen where the breakdown of cellulose in this way is intense and use the hydrogen and carbon dioxide released in their energy metabolism. Anaerobic environment and the presence of sufficient hydrogen in the environment for energy metabolism are the basic conditions for methanogens to survive (Czerkawski, 1986, Finlay et al., 1994).

Methane formed in this way is a colorless, odorless, lighter-than-air gas with a specific gravity of 0.55 g/cm<sup>3</sup> and is rapidly mixed into the atmosphere. Since methane is also an extremely unstable gas, it tends to react with oxygen, resulting in highly destructive explosions, also known as grizu explosions (Öztürk, 2008).

Between 2-12% of the gross energy in feed is lost as methane gas through the ructus, which makes this issue important in terms of animal nutrition. Reducing ruminal methanogenesis is important both ecologically and economically (Johnson and Johnson, 1995; Wittenberg, 2010).

During the digestion of cellulose, carbon dioxide and hydrogen are released as intermediate products and two reactions take place. The (H<sub>2</sub>) produced can be used in volatile fatty acid synthesis or consumed by

micro-organisms to be used in organic matter synthesis. The H used by the micro-organisms will be used for their development and thus for microbial protein production and consequently can be converted into yield. If the main direction of the reactions taking place in the rumen can be directed towards the production of acetate propionate, Hydrogen will be removed from the environment and therefore methane production will be reduced (O'Mara, 2004). Although protozoa and bacteria are responsible for ruminal methane production, the contribution of protozoa to methane production is complicated. Some methanogens colonize the mouth opening of protozoa by attaching to and colonizing the protozoa themselves (Ohene-Adjei et al., 2007). Rumen microflora regenerates sometime after defaunation and methane production decreases (Finlay et al., 1994; Christophersen, 1997). This practice negatively affects cellulose digestion and therefore rumen metabolism is unnecessarily disrupted by this method (Demeyer et al., 1982). In some in vitro studies, no statistical difference was found in methane production when defauna and mixed fauna environments were compared (Ranilla et al., 2007).

### CONCLUSION

Methane emission in ruminants is an important issue both economically and ecologically. I believe that this issue is not yet fully understood in terms of animal nutrition and more comprehensive research is needed. It is a fact that the issue will become more enlightened as the secrets between protozoa and methanogens are unraveled. The methane emission inventory of our country should be prepared and a risk analysis of the situation should be made; if a high risk is determined, universities and other research institutions should accelerate their studies in the field of methane inhibition.

If we evaluate the world in terms of methane emission and inhibition, we see that considerable progress has been made in this regard. Methane emission inventories are taken at routine intervals and the current situation is evaluated.

## REFERENCE

- Boadi, D. A., Wittenberg, K. M., Scott, S. L., Burton, D., Buckley, K., Small, J. A., & Ominski, K. H. (2004). Effect of low and high forage diet on enteric and manure pack greenhouse gas emissions from a feedlot. *Canadian Journal of Animal Science*, 84(3), 445-453.
- Bryant, M. P. (1959). Bacterial species of the rumen. *Bacteriological reviews*, 23(3), 125-153.
- Christophersen, C. (2007). Grain and artificial stimulation of the rumen change the abundance and diversity of methanogens and their association with ciliates. University of Western Australia. PhD Thesis.
- Czerkawski, J. W. (2013). An introduction to rumen studies. Elsevier. Pergamon Press, New York. 1986.
- Demeyer, D. I., Van Nevel, C. J., & Van de Voorde, G. (1982). The effect of defaunation on the growth of lambs fed three urea containing diets. *Archiv für Tierernaehrung*, 32(7-8), 595-604.
- FAO (2022). The Food and Agriculture Organization <http://www.fao.org/faostat/en/#data/QL> Access date: 12.12.2022
- Faverdin, P. (1999). The effect of nutrients on feed intake in ruminants. *Proceedings of the Nutrition Society*, 58(3), 523-531.
- Finlay, B. J., Esteban, G., Clarke, K. J., Williams, A. G., Embley, T. M., & Hirt, R. P. (1994). Some rumen ciliates have endosymbiotic methanogens. *FEMS microbiology letters*, 117(2), 157-161.
- Gerber, P. J., Steinfeld, H., Henderson, B., Mottet, A., Opio, C., Dijkman, J., ... & Tempio, G. (2013). Tackling climate change through livestock: a global assessment of emissions and mitigation opportunities. Food and Agriculture Organization of the United Nations (FAO).
- Gonzalez-Avalos, E., & Ruiz-Suarez, L. G. (2001). Methane emission factors from cattle manure in Mexico. *Bioresource Technology*, 80(1), 63-71.
- Johnson, D. E., Hill, T. M., Ward, G. M., Johnson, K. A., Branine, M. E., Carmean, B. R., & Lodman, D. W. (1993). Ruminants and other animals. In *Atmospheric methane: Sources, sinks, and role in global change* (pp. 199-229). Springer, Berlin, Heidelberg.
- Johnson, K. A., & Johnson, D. E. (1995). Methane emissions from cattle. *Journal of animal science*, 73(8), 2483-2492.
- Kuenzle, C. C., & Jenny, E. (1979). Biochemistry of microbial forestomach digestion in ruminants. *Schweizer Archiv für Tierheilkunde*, 121(10), 503-519.
- Ohene-Adjei, S., Teather, R. M., Ivan, M., & Forster, R. J. (2007). Postinoculation protozoan establishment and association patterns of methanogenic archaea in the ovine rumen. *Applied and Environmental Microbiology*, 73(14), 4609-4618.

- O'Mara F. (2004). Greenhouse Gas Production From Dairyin: Reducing Methane Production. *Advances in Dairy Technology*.16, 295.
- Öztürk, M. (2008). Katı atık depolama alanında metan gazı oluşumu. Online: [http://www.mozturk.net/Upload//DEPO% 20GAZI. pdf](http://www.mozturk.net/Upload//DEPO%20GAZI.pdf).
- Ranilla, M. J., Jouany, J. P., & Morgavi, D. P. (2007). Methane production and substrate degradation by rumen microbial communities containing single protozoal species in vitro. *Letters in applied microbiology*, 45(6), 675-680.
- Selici T, Utlu Z, İlten N. (2008). Enerji Kullanımının Çevresel Etkileri ve Sürdürülebilir Gelişme Açısından Değerlendirilmesi. *Elektrik Mühendisleri Odası*. [https://www.academia.edu/download/41254602/ENERJ\\_KULLANIMININ\\_EVRESEL\\_ETKLER\\_VE\\_SRD20160115-4049-v5io9k.pdf](https://www.academia.edu/download/41254602/ENERJ_KULLANIMININ_EVRESEL_ETKLER_VE_SRD20160115-4049-v5io9k.pdf)  
Date of Access: 12.12.2022
- Türkeş, M. (2000). Hava, İklim, Şiddetli Hava Olayları ve Küresel Isınma. *Devlet Meteoroloji İşleri Genel Müdürlüğü*, 187-205. Ankara.
- UNFCCC, (1998). Kyoto Protocol to the United Nations Framework on Climate Change. <http://unfccc.int/resource/docs/convkp/kpeng.pdf>, Access Date: 11.12.2022.
- Wittenberg, K. (2008). Enteric methane emissions and mitigation opportunities for Canadian cattle production systems. Winnipeg: University of Manitoba <http://www.vido.org/beefinonet/otherareas/pdf/CcbMethaneemissionsWittenburg.pdf> (accessed November, 24, 2019).





## ***CHAPTER 17***

### **MORPHOMETRY AND ORGANIZATION OF FORAMEN JUGULARE IN FETAL CADAVERS<sup>1</sup>**

*Özcan ÖZGEL<sup>2</sup>, Soner ALBAY<sup>3</sup>*

---

1 This study was summarized from the Ph.D. thesis numbered 691524 named "Morphometry and Organization of Foramen Jugulare in Fetal Cadavers".

2 Prof. Dr. Dr., Burdur Mehmet Akif Ersoy University, Faculty of Veterinary Medicine, Department of Anatomy. ozcangel@gmail.com, ORCID ID: 0000-0003-0394-5678

3 Prof. Dr., Süleyman Demirel University, Faculty of Medicine, Department of Anatomy. soneralbay@yahoo.com, ORCID ID: 0000-0001-8438-8628

## INTRODUCTION

Foramen jugulare is an aperture anteriorly located on both sides of foramen magnum at fossa cranii posterior and positioned at the posterior end of fissura petrooccipitalis, and between pars petrosa ossis temporale and os occipitale (Erongun et al., 1989; Caldemeyer et al., 1997; Idowu, 2004; Sharma & Garud, 2011; Ergun & Hayran, 2014).

Foramen jugulare, which has close neighbourhood with truncus encephali, cerebellum, cavitas tympani as well as other important neural and vascular structures, has endocranial and extracranial surfaces with different anatomical structures (Erongun et al., 1989; Tekdemir, 1998).

The foramen jugulare on the intracranial surface is associated with cerebellum in the upper direction, canalis nervi hypoglossi in the medial direction, fissura petrooccipitalis and sinus petrosus inferior in the anterior direction, and meatus acusticus internus in the superolateral direction.

The lateral part of the extracranial surface of the foramen jugulare comprises fossa jugularis and this fossa is located directly right beneath the thin bony base of the tympanum. Foramen stylomastoideum and proc. styloideus are placed in the lateral side of the foramen jugulare while condylus occipitalis is located in its medial side, and apertura externa canalis carotici is situated in right front of the foramen jugulare. The anterolateral and posteromedial bone walls of the foramen jugulare are formed by os temporale and os occipitale, respectively. The larger posterolateral compartment that divides the foramen jugulare into two compartments is called as pars vasculosa. The smaller anteromedial compartment is called as pars nervosa. Sinus petrosus inferior and n. glossopharyngeus pass through the pars nervosa part of the foramen jugulare while v. jugularis interna, n. vagus, n. accessorius, a. pharyngea ascendens and meningeal branches of a. occipitalis pass through pars vasculosa (Dias et al., 2014). Sinus petrosus inferior is located between IX. and X. cranial nerves along pars nervosa and open into v. jugularis interna within or right beneath the foramen jugulare (Caldemeyer et al., 1997; Idowu, 2004; Navsa & Kramer, 1998; Tummala et al., 2005; Das et al., 2016; Saberi, 2019; Constanzo et al., 2020).

Foramen jugulare allows the passage for numerous neurovascular structures. Pars nervosa that is the anteromedial portion of the foramen jugulare involves n. glossopharyngeus and sinus petrosus inferior. On the other side, the posterolateral portion named as pars vasculosa consists of bulbus jugularis, n. vagus and the spinal portion part of n. accessorius. Foramen jugulare has an irregular morphology and there is usually a bilateral disproportion between the widths and lengths of intracranial and extracranial openings. Foramen jugulare may be divided completely or partly into two, three or furthermore four compartments by the means of fibrous or

bony bridges that join the spina jugulare of pars petrosa of os temporale. In case of triseptation, foramen jugulare consists of two venous and one neural compartment. The venous compartments are composed of the larger posterolateral (sigmoid) compartment drained by sinus sigmoideus and the smaller anteromedial (petrosal) compartment drained by sinus petrosus inferior. The intrajugular part located between the sigmoid and petrosal parts of the foramen jugulare is at the site of proc. intrajugularis of the os temporale and os occipitale bones that can be united by fibrous or bony bridges (Erongun et al., 1989; Caldemeyer et al., 1997; Ergun & Hayran, 2014; Tekdemir, 1998; Kryzanski & Heilman, 2005)

Foramen jugulare has become the subject of many morphological studies because of its clinical importance. It can be affected by congenital, vascular and tumoral lesions that emerge in various clinical syndromes. The most common tumours that can be encountered in the region of the foramen jugulare include glomus jugulare tumour, paragangliomas, neuroma, meningioma, metastatic carcinoma, chondroma, nasopharyngeal carcinoma and carcinoma of cavum tympani (Griessenauer et al., 2016).

Various syndromes depending on exposure of varying combinations of neurovascular structures of the foramen jugulare have been observed. The jugular foramen syndrome (*Vernet's Syndrome*) occurs due to the compression of n. glossopharyngeus, n. vagus and n. accessorius, and it is characterised by loss of taste. It is effective on posterior one third of the tongue and vocal cords. It manifests palatal paralysis and weakness of m. trapezius and m. sternocleidomastoideus (Liu & Fukushima; 2012). *Schmidt's Syndrome* is characterised by ipsilateral paralysis of palatum molle, pharynx and larynx and the lesion or radicular findings of vagal and spinal accessory nuclei emerging due to ipsilateral weakness of m. trapezius and m. sternocleidomastoideus. *Tapia syndrome* results in the lesions in motor nucleus roots of n. vagus and ipsilateral paralysis of n. hypoglossus, pharynx and larynx as well as the atrophy of the tongue. *Jackson Syndrome* is caused by nuclear or radicular lesion of n. vagus, n. accessorius and n. hypoglossus and is characterised by ipsilateral paralysis of palatum molle, pharynx and larynx, and also hemianesthesia and ipsilateral paralysis of m. trapezius and m. sternocleidomastoideus. *Collet-Sicard Syndrome* is characterised by the loss of taste in posterior one third of the tongue and the paralysis of the vocal cords and palatum resulting from the affected n. glossopharyngeus, n. vagus, n. accessorius and n. hypoglossus, weakening of m. trapezius and m. sternocleidomastoideus, paralysis of the tongue and hemianesthesia of palatum, pharynx and larynx. *Villarret's Syndrome* manifests itself similarly with *Collet-Sicard Syndrome* with combination of Horner Syndrome (Constanzo et al., 2020; Griessenauer et al., 2016; Vogl & Bisdas, 2009; Skrzat et al., 2016; Erzurumlu et al., 2019).

Sulcus sinus petrosi inferioris is the groove that involves the sinus petrosus inferior. Sulcus sinus petrosi inferioris is formed by the union of pars petrosa ossis temporale and pars basilaris ossis occipital of skull. It starts from the posteroinferior part of the sinus cavernosus and terminates at the bulbus superior of v. jugularis interna by passing through anterior part of the foramen jugulare. Sinus petrosus inferior gets v. auditiva interna and additionally the veins from the lower surfaces of medulla oblongata, pons and cerebellum. Sinus petrosus inferior is located medially and anteriorly together with ramus meningeus of a. pharyngea ascendens and is directed obliquely downward and backward. Sinus transversus is located lateral and posterior to the foramen jugulare together with ramus meningeus of a. occipitalis and n. glossopharyngeus, n. vagus and n. accessorius exit between the two sinuses. These three structural groups are separated by two protuberances of fibrous tissue. The union of sinus petrosus inferior and v. jugularis interna are positioned at the lateral side of the nerves (Drake et al., 2005).

Sulcus sinus sigmoidei is the groove that involves the sinus sigmoideus. Sinus sigmoideus that are also known as pars sigmoidea are the venous sinuses in the ossa cranii that drain blood from the sinus venosus duralis posterior. Sinus sigmoideus drains blood from the sinus transversus that courses along the posterior wall of cavum cranii. It runs inferiorly along os parietale, os temporale and os occipitale and unites with sinus petrosus inferioris to form v. jugularis interna. Each sinus sigmoideus starts beneath os temporale and shows a tortuous course towards the foramen jugulare and at that point sinus sigmoideus presents continuity with v. jugularis interna. Sinus sigmoideus drains blood from the sinuses transversus that drain blood from the posterior surface of the skull and also from the vv. cerebrales, vv. cerebellares, vv. diploicae, and vv. emissariae along its course (Drake et al., 2005).

The present study was based on the statistical analysis of the measurements taken from the related surrounding structures to perform accurate morphometry of the foramen jugulare and to determine its exact localization using a statistically significant number of foetuses from both genders at the second, third and fourth trimester. Since, the surgical treatment of the foramen jugulare tumours may be challenging by application of skull base surgery, the accurate determination of surgical anatomy regarding foramen jugulare and the neighbouring anatomic structures has a great importance in order to achieve successful surgical outcomes with the least possible complications.

## MATERIAL AND METHOD

The study was conducted on the fetuses taken from Isparta Maternity and Children's Hospital in the laboratory of Anatomy Department of Suleyman Demirel University Medical Faculty between the years 1996-2010 by obtaining the approval from their parents. In the study, fetuses that were aged between 22-40 gestational weeks, were from both genders, had no external anomaly or pathology, and were kept in 10% formaldehyde solution, were used. Their intrauterine gestational ages were as follows; 15 fetuses from the Trimester I (22-25 weeks), 30 fetuses from the Trimester III (26-37 weeks), and 12 fetuses from the Trimester IV (38-40 weeks)

**Table 1.** *The parameters used to determine gestational ages of the fetuses*

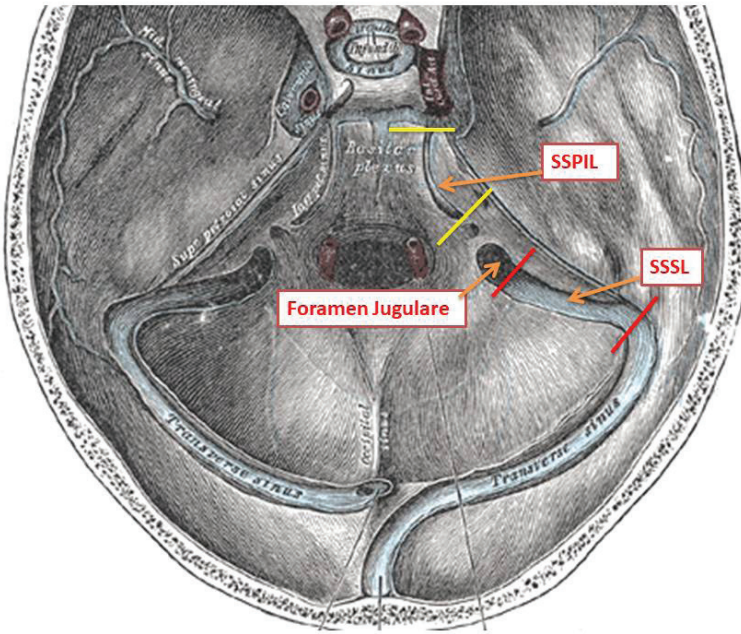
<b>Crown-rump length (CRL)</b>	The length between vertex and the bottom of the buttock
<b>Head Circumference (HC)</b>	The circumferential line passing through glabella, tubers parietale andinion point of os occipitale (protuberantia occipitalis externa)
<b>Biparietal Diameter (BPD)</b>	The width between tubers parietale

Each foetus underwent craniotomy and cerebrum was primarily uncovered. Then, cerebrum was removed meticulously from its location. Dura mater covering cavitas cranii was detached from the junctions and the dissection of the foramen jugulare was performed. EUROMEX Edublu 1805-S binocular digital stereo microscope was utilized for dissection. After the dissection, cranium was fixed and Mitutoyo Digimatic Caliper, Abs 200 mm (500-182-30) was used for the morphometric measurements of the parameters determined related with foramen jugulare, sulcus sinus petrosi inferioris and sinus sigmoideus that will be examined in the study. A Nikon D80 digital camera was utilised for photographing the data.

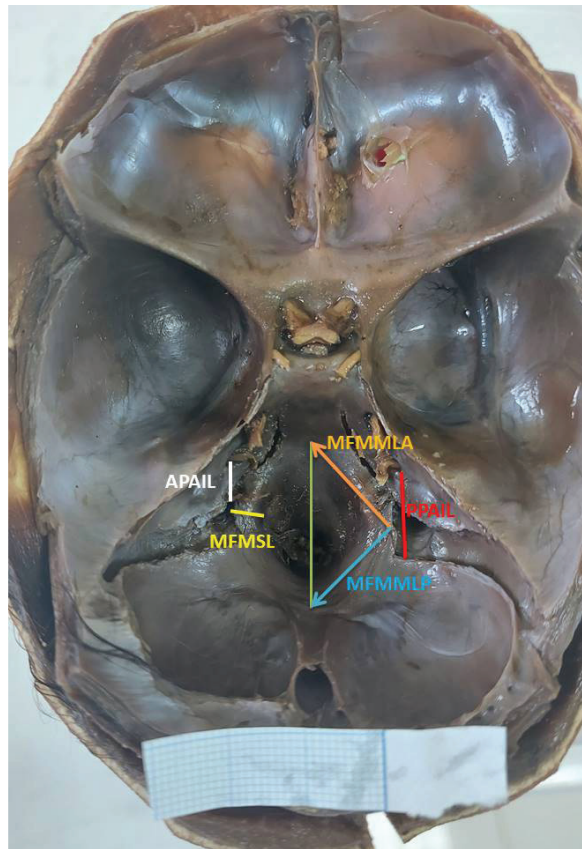
Terminologica Anatomica was taken as a reference in nomenclature of the anatomical terms.

**Table 2.** *The parameters used in the study and their abbreviations*

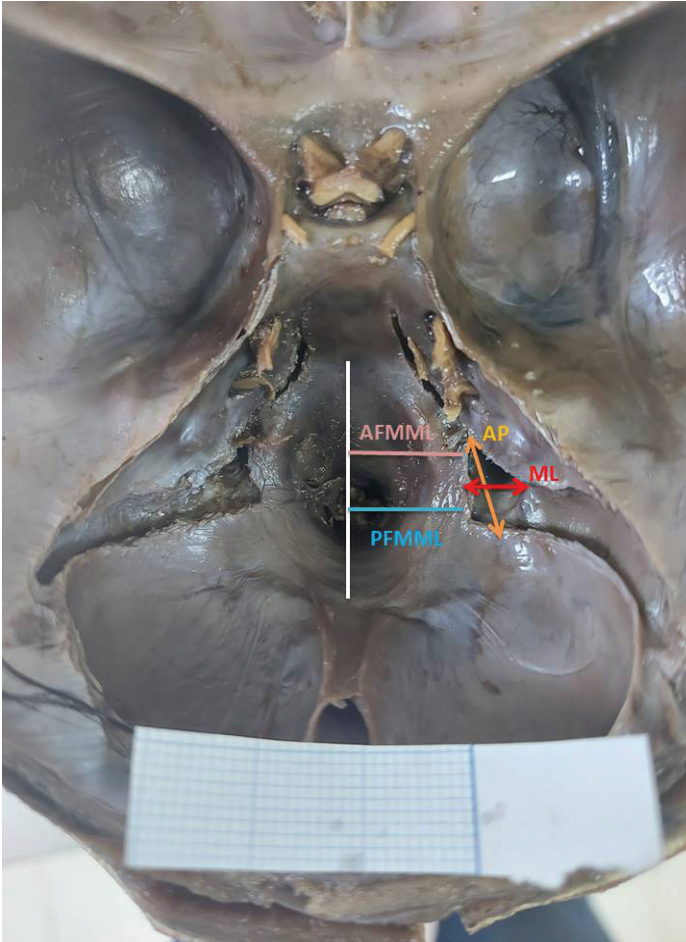
Anteroposterior diameter	AP
Mediolateral diameter	ML
The length of sulcus sinus petrosi inferioris	SSPIL
The length of sulcus sinus sigmoidei	SSSL
The distance from the anterior edge of the foramen jugulare to the median line of the foramen magnum	AFMML
The distance from posterior edge of the foramen jugulare to the median line of the foramen magnum	PFMML
The distance from anterior edge of the foramen jugulare to porus acusticus internus	APAIL
The distance between posterior edge of the foramen jugulare and porus acusticus internus	PPAIL
The distance from the midpoint of the foramen jugulare to the anterior point on the median line of the foramen magnum	MFMMLA
The distance from the midpoint of the foramen jugulare to the posterior point on the median line of the foramen magnum	MFMMLP
The shortest distance from the midpoint of the foramen jugulare to the foramen magnum	MFMSL
CRL	CRL
Head circumference	BÇ
Biparietal diameter	BP



**Figure 1.** *Foramen jugulare and the grooves participating in its formation. SSPIL: The length of sulcus sinus petrosi inferioris, SSSL: The length of sulcus sinus sigmoidei*



**Image 1.** Foramen magnum and the measured neighbouring formations. *APAIL*: The distance from anterior edge of the foramen jugulare to porus acusticus internus, *MFMSL*: The shortest distance from the midpoint of the foramen jugulare to the foramen magnum, *MFMLA*: The distance from the midpoint of the foramen jugulare to the anterior point on the median line of the foramen magnum, *PPAIL*: The distance between posterior edge of the foramen jugulare and porus acusticus internus, *MFMLP*: The distance from the midpoint of the foramen jugulare to the posterior point on the median line of the foramen magnum

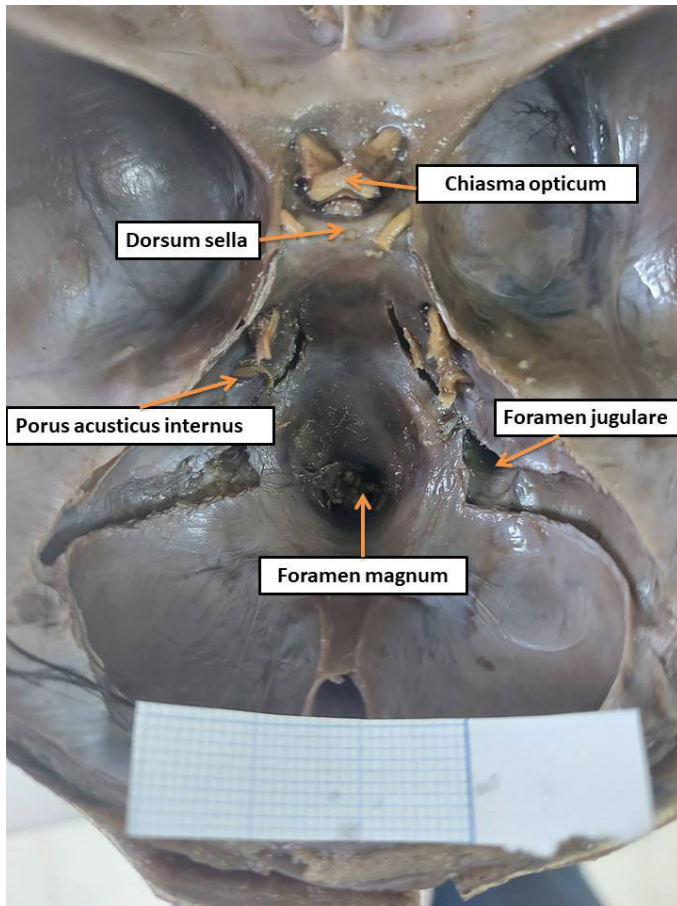


**Image 2.** Foramen jugulare and the measured neighbouring formations  
*AFMML:* The distance from the anterior edge of the foramen jugulare to the median line of the foramen magnum, *PFMML:* The distance from posterior edge of the foramen jugulare to the median line of the foramen magnum, *AP:* Anteroposterior diameter of the foramen jugulare, *ML:* Mediolateral diameter of the foramen jugulare

SPSS 20.0 for Windows software was used for the analysis of the data. Normality tests (Kolmogorov Smirnov, Shapiro Wilk-W, Q-Q Plot, Histogram Graph) were applied to determine whether or not data were parametric or nonparametric. The data were compared between right-left sides, genders and trimesters and correlations of the data were checked. Since all the parameters were normally distributed, Independent Sample T test was used to compare the sides and genders. One Way Anova test was applied to compare the trimesters. Pearson's correlation test was carried out for correlation analysis. The value of  $p < 0.05$  was accepted as statistically significant.



## RESULTS



**Image 3.** *The general appearance of the foramen jugulare and the surrounding structures*

### Macroanatomical Results

The shape of the foramen jugulare was found to be oval-elliptical on the right and left sides in all the pieces of the male and female foetuses from the 2<sup>nd</sup> trimester, only a female foetus was detected to have round-shaped foramen jugulare on the right and left sides.

It was determined in the examined foetuses from the 3<sup>rd</sup> trimester that approximately 60% and 40% of the male foetuses had round and oval-elliptical shaped foramen jugulare, respectively, and foramen jugulare was round and oval-elliptical shaped in 40% and 60% of the female foetuses for both left and right sides, respectively.

Foramen jugulare was round and oval-elliptical shaped in 2 and 4 pieces for both right and left sides of the male foetuses examined at the 4<sup>th</sup> trimester, respectively, while all the female foetuses from the 4<sup>th</sup> trimester had a oval-elliptical shaped foramen jugulare.

The division of the foramen jugulare by bony bridges (septation) was a very rarely seen phenomenon in the present study. Among the examined foetuses, septation was encountered as division into two compartments on the left side of 1 female foetus from the 2<sup>nd</sup> trimester, and unilaterally only right side in one of the two male foetuses from the 3<sup>rd</sup> trimester and on both right and left sides of the other male foetus.

### Statistical Results

**Table 3.** *The number of the foetuses in terms of trimesters*

Trimester	Number of foetuses	Percentage
2 <sup>nd</sup> Trimester	15	26.3
3 <sup>rd</sup> Trimester	30	52.6
4 <sup>th</sup> Trimester	12	21.1
Total	57	100

**Table 4.** *The general parameters of the morphometric data of the foramen jugulare in terms of direction*

PARAMETERS	N	MINIMUM VALUE	MAXIMUM VALUE	AVERAGE	STANDART DEVIATION	p
AP-RIGHT	56	3,07	11,77	5,66	1,56	0,993
AP-LEFT	57	2,41	12,81	5,61	1,62	
ML-RIGHT	56	1,45	5,48	3,39	0,97	0,954
ML-LEFT	57	1,47	5,32	3,37	0,95	
SSPIL-RIGHT	56	4,36	15,61	10,75	2,55	0,631
SSPIL-LEFT	57	6,22	15,17	10,71	2,37	
SSSL-RIGHT	56	6,06	20,32	12,52	2,87	0,859
SSSL-LEFT	57	6,69	19,60	12,51	2,79	
AFMML-RIGHT	56	4,94	15,59	9,12	2,09	0,506
AFMML-LEFT	57	5,74	14,97	8,98	1,96	
PFMML-RIGHT	56	7,45	17,12	11,34	2,20	0,544
PFMML-LEFT	57	7,00	17,26	10,92	2,38	
APAIL-RIGHT	56	3,04	7,97	5,80	1,08	0,591
APAIL-LEFT	57	3,09	8,04	5,61	1,17	
PPAIL-RIGHT	56	7,45	17,14	11,30	1,85	0,997
PPAIL-LEFT	57	7,26	16,69	11,22	1,90	
MFMLLA-RIGHT	56	6,73	18,87	10,83	2,27	0,628
MFMLLA-LEFT	57	6,92	18,17	11,36	2,36	
MFMLLP-RIGHT	56	7,01	18,89	11,90	2,71	0,413
MFMLLP-LEFT	57	7,21	19,70	11,93	2,92	
MFMSL-RIGHT	56	1,92	5,85	3,24	0,89	0,171
MFMSL-LEFT	57	2,00	5,14	3,14	0,75	

Table 4 shows mean, standard deviation, minimum, and maximum values of morphometric data of the foramen jugulare in terms of direction and p values obtained by statistical comparison. Accordingly, mean anteroposterior diameter (AP) of the right foramen jugulare was 5.66 mm whereas the mean anteroposterior diameter (AP) of the left foramen jugulare was 5.61 mm. Moreover, mean mediolateral (ML) diameter of the right foramen jugulare was 3.39 mm whereas the mean mediolateral (ML) diameter of the left foramen jugulare was 3.37 mm. No statistically significant difference was found in the statistical comparison carried out between the quantitative values of right and left side parameters obtained in the study ( $p>0.05$ ).

**Table 5.** *The general parameters of the morphometric data of the foramen jugulare in terms of gender*

PARAMETERS		MALE	FEMALE	p
AP-RIGHT	Average	5,85±1,74	5,41±1,29	0,422
	N	32	24	
AP-LEFT	Average	5,77±1,82	5,41±1,34	0,826
	N	32	25	
ML-RIGHT	Average	3,47±0,98	3,27±0,96	0,346
	N	32	24	
ML-LEFT	Average	3,51±0,94	3,19±0,95	0,856
	N	32	25	
SSPIL-RIGHT	Average	10,24±2,42	11,40±2,61	0,281
	N	32	24	
SSPIL-LEFT	Average	10,41±2,13	11,10±2,65	0,094
	N	32	25	
SSSL-RIGHT	Average	12,70±3,10	12,28±2,60	0,538
	N	32	24	
SSSL-LEFT	Average	12,67±2,94	12,30±2,63	0,603
	N	32	25	
AFMML-RIGHT	Average	8,91±1,81	9,40±2,44	0,104
	N	32	24	
AFMML-LEFT	Average	8,88±1,70	9,10±2,28	0,158
	N	32	25	
PFMML-RIGHT	Average	11,21±1,94	11,52±2,54	0,098
	N	32	24	
PFMML-LEFT	Average	10,83±2,25	11,05±2,57	0,349
	N	32	25	
APAIL-RIGHT	Average	5,67±1,11	5,96±1,05	0,542
	N	32	24	
APAIL-LEFT	Average	5,59±1,21	5,65±1,14	0,575
	N	32	25	
PPAIL-RIGHT	Average	11,50±1,95	11,04±1,71	0,645
	N	32	24	
PPAIL-LEFT	Average	11,51±1,95	10,84±1,80	0,559
	N	32	25	

<b>MFMLA- RIGHT</b>	Average	10,68±1,98	11,03±2,64	0,298
	N	32	24	
<b>MFMLA- LEFT</b>	Average	11,27±2,28	11,47±2,49	0,563
	N	32	25	
<b>MFMLP- RIGHT</b>	Average	11,80±2,47	12,03±3,05	0,296
	N	32	24	
<b>MFMLP- LEFT</b>	Average	11,96±2,87	11,90±3,05	0,971
	N	32	25	
<b>MFMSL-RIGHT</b>	Average	3,16±0,73	3,35±1,08	0,044
	N	32	24	
<b>MFMSL-LEFT</b>	Average	2,99±0,64	3,32±0,85	0,173
	N	32	25	

Table 5 shows mean, standard deviation, minimum, and maximum values of morphometric data of the foramen jugulare in terms of gender and p values obtained by statistical comparison. Based on the table, mean anteroposterior diameter (AP) of the foramen jugulare on the right and sides was 5.85 mm and 5.77 mm in the male foetuses, respectively, whereas mean anteroposterior diameter (AP) of the foramen jugulare on the right and sides was 5.41 mm and 5.41 mm in the female foetuses, respectively. In addition, mean mediolateral diameter (ML) values of the foramen jugulare on the right and sides was 3.47 mm and 3.51 mm in the male foetuses, respectively, whereas mean mediolateral diameter (ML) of the foramen jugulare on the right and sides was 3.27 mm and 3.19 mm in the female foetuses, respectively. The statistical comparison performed between the numerical values of the right and left side parameters obtained in the study in terms of gender revealed a significant difference only in the right MFMSL parameter ( $p < 0.05$ ).

**Table 6.** *The general parameters of the morphometric data of the foramen jugulare in terms of foetal age.*

PARAMETERS	2.TRIMESTER	3.TRIMESTER	4.TRIMESTER		
<b>AP-RIGHT</b>	5,21±1,44	5,69±1,88	6,20±1,27	0,283	
	15	30	11		
<b>AP-LEFT</b>	5,01±1,18	5,69±1,88	6,17±1,20	0,168	
	15	30	12		
<b>ML-RIGHT<sup>a</sup></b>	2,65±0,82	3,42±0,78	4,29±0,86	0,000	$p < 0,001$
	15	30	11		
<b>ML-LEFT<sup>a</sup></b>	2,59±0,62	3,44±0,79	4,16±0,96	0,000	$p < 0,001$
	15	30	12		
<b>SSPIL-RIGHT<sup>b</sup></b>	8,68±2,08	10,79±2,07	13,42±1,73	0,000	$p < 0,001$
	15	30	11		
<b>SSPIL-LEFT<sup>a</sup></b>	8,83±1,74	10,82±1,98	12,80±2,20	0,000	$p < 0,001$
	15	30	12		
<b>SSSL-RIGHT<sup>a</sup></b>	9,54±1,92	13,02±2,21	15,22±2,03	0,000	$p < 0,001$
	15	30	11		

<b>SSSL-LEFT<sup>a</sup></b>	9,46±1,88 15	13,06±2,05 30	14,94±2,04 12	0,000	p<0,001
<b>AFMML- RIGHT<sup>b</sup></b>	7,33±1,33 15	8,98±1,42 30	11,94±1,50 11	0,000	p<0,001
<b>AFMML-LEFT<sup>b</sup></b>	7,25±1,07 15	8,81±1,25 30	11,55±1,61 12	0,000	p<0,001
<b>PFMML- RIGHT<sup>b</sup></b>	9,29±1,21 15	11,25±1,52 30	14,40±1,17 11	0,000	p<0,001
<b>PFMML-LEFT<sup>c</sup></b>	8,48±1,03 15	10,90±1,48 30	14,05±1,70 12	0,000	p<0,001
<b>APAIL-RIGHT<sup>d</sup></b>	5,37±1,04 15	5,76±1,08 30	6,49±0,89 11	0,030	
<b>APAIL-LEFT<sup>d</sup></b>	5,12±1,00 15	5,48±1,14 30	6,56±0,93 12	0,003	
<b>PPAIL-RIGHT<sup>d</sup></b>	10,28±1,20 15	11,15±1,77 30	13,10±1,59 11	0,000	p<0,001
<b>PPAIL-LEFT<sup>b</sup></b>	10,00±1,41 15	11,17±1,79 30	12,84±1,56 12	0,000	p<0,001
<b>MFMMLA- RIGHT<sup>b</sup></b>	9,16±1,76 15	10,88±1,64 30	13,11±2,40 11	0,000	p<0,001
<b>MFMMLA- LEFT<sup>b</sup></b>	9,40±1,84 15	11,43±1,75 30	13,62±2,25 12	0,000	p<0,001
<b>MFMMLP- RIGHT<sup>b</sup></b>	9,71±1,88 15	11,93±2,21 30	14,79±2,20 11	0,000	p<0,001
<b>MFMMLP- LEFT<sup>b</sup></b>	9,55±1,94 15	11,72±2,35 30	15,44±1,71 12	0,000	p<0,001
<b>MFMSL- RIGHT<sup>b</sup></b>	2,42±0,29 15	3,18±0,57 30	4,51±0,76 11	0,000	p<0,001
<b>MFMSL-LEFT<sup>b</sup></b>	2,42±0,35 15	3,06±0,43 30	4,21±0,55 12	0,000	p<0,001

a: p<0.05 (between 2<sup>nd</sup> -3<sup>rd</sup> trimesters, between 2<sup>nd</sup> trimester-term)

b: p<0.05 (between 2<sup>nd</sup> -3<sup>rd</sup> trimesters, between 2<sup>nd</sup> trimester-term and 3<sup>rd</sup> trimester-term)

c: p<0.05 (between 2<sup>nd</sup> trimester-term)

d: p<0.05 (between 2<sup>nd</sup> trimester-term, between 3<sup>rd</sup> trimester-term)

Table 6 shows mean, standard deviation, minimum, and maximum values of morphometric data of the foramen jugulare in terms of foetal age groups and p values obtained by statistical comparison. Based on the table, mean anteroposterior diameter (AP) of the foramen jugular was 5.21 mm, 5.69 mm, and 6.20 mm on the right side in the 2<sup>nd</sup> trimester, 3<sup>rd</sup> trimester and term groups, respectively, whereas the values of this parameter were detected to be 5.01 mm, 5.69 mm and 6.17 mm on the left side, respectively. Additionally, mean mediolateral diameter (ML) of the foramen jugulare was 2.65 mm, 3.42 mm and 4.29 mm on the right side in the 2<sup>nd</sup> trimester,

3<sup>rd</sup> trimester and term groups, respectively, whereas those values were 2.59 mm, 3.44 mm and 4.16 mm on the left side, respectively. Statistically significant differences were identified in terms of other parameters except for the anteroposterior diameter (AP) parameter of the foramen jugulare in the statistical comparison carried out between the numerical values of right and left side parameters obtained in the study in terms of foetal age groups ( $p < 0.05$ ,  $p < 0.01$ ,  $p < 0.001$ , respectively). It was also determined that the numerical values of the parameters in terms of the study groups increased the 2<sup>nd</sup> trimester to term.

### Correlation Results

**Table 7.** *The correlation data between the data of the foramen jugulare and foetal age (weeks)*

PARAMETER 1	PARAMETER 2	CORRELATION
Week	AP <sub>Right</sub>	0,225
Week	AP <sub>Left</sub>	0,216
Week	ML <sub>Right</sub>	0,490
Week	ML <sub>Left</sub>	0,506
Week	SSPIL <sub>Right</sub>	0,694
Week	SSPIL <sub>Left</sub>	0,654
Week	SSSL <sub>Right</sub>	0,724
Week	SSSL <sub>Left</sub>	0,736
Week	AFMML <sub>Right</sub>	0,787
Week	AFMML <sub>Left</sub>	0,801
Week	PFMML <sub>Right</sub>	0,822
Week	PFMML <sub>Left</sub>	0,835
Week	APAIL <sub>Right</sub>	0,453
Week	APAIL <sub>Left</sub>	0,456
Week	PPAIL <sub>Right</sub>	0,562
Week	PPAIL <sub>Left</sub>	0,578
Week	MFMMLA <sub>Right</sub>	0,696
Week	MFMMLA <sub>Left</sub>	0,722
Week	MFMMLP <sub>Right</sub>	0,773
Week	MFMMLP <sub>Left</sub>	0,774
Week	MFMSL <sub>Right</sub>	0,825
Week	MFMSL <sub>Left</sub>	0,863

Table 7 shows the Pearson’s correlation values (r) obtained as a result of the analysis performed to determine whether or not morphometric data of the foramen jugulare was correlated with foetal age (weeks). According to the analysis results, all the data of the foramen jugulare showed a positive and statistically significant correlation except for the AP ( $p>0.05$ ) parameter ( $p<0.001$ ). Also, correlation level was high and very high in the parameters except for  $ML_{Right}$  and  $APAIL_{Right-Left}$  parameters.

**Table 8.** *The correlation results between the data of the foramen jugulare and delivery weight of the fetus.*

PARAMETER 1	PARAMETER 2	CORRELATION
Weight	$AP_{Right}$	0,325
Weight	$AP_{Left}$	0,212
Weight	$ML_{Right}$	0,513
Weight	$ML_{Left}$	0,469
Weight	$SSPIL_{Right}$	0,636
Weight	$SSPIL_{Left}$	0,591
Weight	$SSSL_{Right}$	0,643
Weight	$SSSL_{Left}$	0,645
Weight	$AFMML_{Right}$	0,764
Weight	$AFMML_{Left}$	0,779
Weight	$PFMML_{Right}$	0,840
Weight	$PFMML_{Left}$	0,839
Weight	$APAIL_{Right}$	0,469
Weight	$APAIL_{Left}$	0,493
Weight	$PPAIL_{Right}$	0,562
Weight	$PPAIL_{Left}$	0,588
Weight	$MFMMLA_{Right}$	0,662
Weight	$MFMMLA_{Left}$	0,673
Weight	$MFMMLP_{Right}$	0,753
Weight	$MFMMLP_{Left}$	0,745
Weight	$MFMSL_{Right}$	0,827
Weight	$MFMSL_{Left}$	0,849

Table 8 shows the Pearson's correlation values (r) obtained as a result of the analysis performed to determine whether or not morphometric data of the foramen jugulare was correlated with delivery weight of the foetus. According to the analysis results, all the data of the foramen jugulare showed a positive and statistically significant correlation except for the  $AP_{left}$  ( $p>0.05$ ) parameter ( $p<0.001$ ). In the light of this analysis,  $AP_{right}$  and the other parameters had the significance levels of  $p<0.05$  and  $p<0.001$ , respectively. In addition, statistically significant correlation levels were high and very high in the parameters except for  $AP_{Right}$ ,  $ML_{Left}$  and  $APA-IL_{Right-Left}$  parameters.

**Table 9.** *The correlation data between the data of the foramen jugulare and CRL parameter*

PARAMETER 1	PARAMETER 2	CORRELATION
CRL		0,232
CRL	$AP_{Right}$	0,220
CRL	$AP_{Left}$	0,513
CRL	$ML_{Right}$	0,483
CRL	$ML_{Left}$	0,709
CRL	$SSPIL_{Right}$	0,668
CRL	$SSPIL_{Left}$	0,723
CRL	$SSSL_{Right}$	0,726
CRL	$SSSL_{Left}$	0,804
CRL	$AFMML_{Right}$	0,790
CRL	$AFMML_{Left}$	0,853
CRL	$PFMML_{Right}$	0,865
CRL	$PFMML_{Left}$	0,468
CRL	$APAIL_{Right}$	0,459
CRL	$APAIL_{Left}$	0,532
CRL	$PPAIL_{Right}$	0,540
CRL	$PPAIL_{Left}$	0,703
CRL	$MFMMLA_{Right}$	0,712
CRL	$MFMMLA_{Left}$	0,717
CRL	$MFMMLP_{Right}$	0,689
CRL	$MFMMLP_{Left}$	0,818
CRL	$MFMSL_{Right}$	0,851
CRL	$MFMSL_{Left}$	



Table 9 shows the Pearson’s correlation values (r) obtained as a result of the correlation analysis performed to determine whether or not morphometric data of the foramen jugulare was correlated with CRL. According to the analysis results, all the data of the foramen jugulare showed a positive and statistically significant correlation except for the AP<sub>Right</sub> and AP<sub>Left</sub> (p<0.05) parameters (p<0.001). Additionally, correlation level was high and very high in the parameters except for ML<sub>Left</sub>, APAIL<sub>Right</sub> and PPAIL<sub>Right</sub> parameters.

**Table 10.** *The correlation data between the data of the foramen jugulare and fetal head circumference*

PARAMETER 1	PARAMETER 2	CORRELATION
Head Circumference	AP <sub>Right</sub>	0,238
Head Circumference	AP <sub>Left</sub>	0,263
Head Circumference	ML <sub>Right</sub>	0,556
Head Circumference	ML <sub>Left</sub>	0,568
Head Circumference	SSPIL <sub>Right</sub>	0,696
Head Circumference	SSPIL <sub>Left</sub>	0,635
Head Circumference	SSSL <sub>Right</sub>	0,751
Head Circumference	SSSL <sub>Left</sub>	0,760
Head Circumference	AFMML <sub>Right</sub>	0,796
Head Circumference	AFMML <sub>Left</sub>	0,791
Head Circumference	PFMML <sub>Right</sub>	0,834
Head Circumference	PFMML <sub>Left</sub>	0,833
Head Circumference	APAIL <sub>Right</sub>	0,445
Head Circumference	APAIL <sub>Left</sub>	0,433
Head Circumference	PPAIL <sub>Right</sub>	0,564
Head Circumference	PPAIL <sub>Left</sub>	0,584
Head Circumference	MFMMMLA <sub>Right</sub>	0,718
Head Circumference	MFMMMLA <sub>Left</sub>	0,728
Head Circumference	MFMMMLP <sub>Right</sub>	0,777
Head Circumference	MFMMMLP <sub>Left</sub>	0,778
Head Circumference	MFMSL <sub>Right</sub>	0,825
Head Circumference	MFMSL <sub>Left</sub>	0,868

Table 10 shows the Pearson's correlation values (r) obtained as a result of the analysis performed to determine whether or not morphometric data of the foramen jugulare was correlated with head circumference. Accordingly, all the data of the foramen jugulare showed a positive and statistically significant correlation except for the  $AP_{Right}$  and  $AP_{Left}$  ( $p>0.05$ ) parameters ( $p<0.001$ ). Additionally, correlation level was high and very high in the parameters except for  $APAIL_{Right-Left}$  parameter.

**Table 11.** *The correlation data between the data of the foramen jugulare and foetal biparietal diameter*

PARAMETER 1	PARAMETER 2	CORRELATION
Biparietal Diamater	$AP_{Right}$	0,177
Biparietal Diamater	$AP_{Left}$	0,175
Biparietal Diamater	$ML_{Right}$	0,490
Biparietal Diamater	$ML_{Left}$	0,506
Biparietal Diamater	$SSPIL_{Right}$	0,658
Biparietal Diamater	$SSPIL_{Left}$	0,607
Biparietal Diamater	$SSSL_{Right}$	0,729
Biparietal Diamater	$SSSL_{Left}$	0,727
Biparietal Diamater	$AFMML_{Right}$	0,705
Biparietal Diamater	$AFMML_{Left}$	0,707
Biparietal Diamater	$PFMML_{Right}$	0,766
Biparietal Diamater	$PFMML_{Left}$	0,779
Biparietal Diamater	$APAIL_{Right}$	0,429
Biparietal Diamater	$APAIL_{Left}$	0,399
Biparietal Diamater	$PPAIL_{Right}$	0,437
Biparietal Diamater	$PPAIL_{Left}$	0,464
Biparietal Diamater	$MFMMLA_{Right}$	0,629
Biparietal Diamater	$MFMMLA_{Left}$	0,647
Biparietal Diamater	$MFMMLP_{Right}$	0,696
Biparietal Diamater	$MFMMLP_{Left}$	0,686
Biparietal Diamater	$MFMSL_{Right}$	0,773
Biparietal Diamater	$MFMSL_{Left}$	0,822

Table 11 shows the Pearson's correlation values ( $r$ ) obtained as a result of the analysis performed to determine whether or not morphometric data of the foramen jugulare was correlated with biparietal diameter. According to the analysis results, all the data of the foramen jugulare showed a positive and statistically significant correlation except for the AP ( $p > 0.05$ ) parameter ( $p < 0.001$ ). Moreover correlation level was high and very high in the parameters except for  $ML_{Right}$ ,  $APAIL_{Right-Left}$  and  $PPAIL_{Right-Left}$  parameters.

## DISCUSSION

The studies on the adult individuals have suggested that size of v. jugularis interna and the presence or absence of a remarkable bulbus superior directly affect the size of the foramen jugulare and the right foramen jugulare is commonly larger than the left foramen jugulare (Navsa & Kramer, 1998; Tummala et al., 2005; Hatipoglu & Anıl, 1992; Aydınlioğlu et al., 2001; Sahep et al., 2010; Khanday et al., 2013; Junior et al., 2014; Shruthi et al., 2015; Desai & Havaladar, 2017; Lovely & Kushwah, 2018).

In the foetal period, foramen jugulare develops asymmetrically caused by the direction of the venous blood flow due to the effect of confluens sinuum. It has been observed that foramen jugulare and veins its contains are larger on the right side than the left side in the early development stage of foetal cranial since main bloodstream of confluens sinuum is directed towards the right side instead of the left side (Ayeni et al. 1995). It has been pointed out in most cases that dominance of the right foramen jugulare is consistent with the superiority of the right v. jugularis interna. The studies have explained this superiority with the dominance of intracranial venous sinus. The sinus sagittalis superior which is the origin of right v. jugularis interna is larger than the sinus sagittalis inferior which is the origin of left v. jugularis inferior. Furthermore, it has been reported that variations in the anatomy of intracranial venous sinuses cause variations in the size of the foramina (Ergun & Hayran, 2014; Dias et al., 2014; Sethi et al., 2011; Hamzaoglu et al., 2018). Also, the dominance of right foramen jugulare is associated with larger flow of right sinus sigmoideus (Rhoton, 2000). Besides, the studies carried out on skull base embryology have noted that foramen jugulare has formed as a result of the differentiation of the parachordal cartilages around the v. jugularis (Di Ieva et al., 2014).

According to the results of the measurements performed in the foetuses examined as the subject of the present study; mean anteroposterior (AP) diameter of the right foramen jugulare at the 2<sup>nd</sup>, 3<sup>rd</sup>, and 4<sup>th</sup> trimesters was 5.17 mm, 5.05 mm, and 6.21 mm, respectively, while mean anteroposterior (AP) diameter of the left foramen jugulare at the 2<sup>nd</sup>, 3<sup>rd</sup>, and 4<sup>th</sup> trimesters was 4.96 mm, 5.06 mm, and 6.18 mm, respectively, and although the studies

conducted on fetuses (Skrzat et al., 2016; Shapiro & Robinson, 1967) and a study carried out on adults (Kayahoglu, et al., 1996) have reported that there as no significant difference between the right and left sides, data obtained from the right side were larger in the present study, which is compatible in the literature (Khanday et al., Freitas et al., 2020; Amudha et al., 2019).

It was determined in a study that mean diameter of right foramen jugulare of MS patients ( $6.3\pm 1.6$  mm) was 10% smaller ( $p=0.020$ ) compared to the control group ( $7.0\pm 1.4$  mm) and mean diameter of the left foramen jugulare ( $5.6\pm 1.3$  mm) of MS patients was 7% smaller ( $p=0.089$ ) compared to the control group ( $6.0\pm 1.3$  mm). In addition, the same researcher has noted that sum of the diameters of both foramen jugulare (averagely  $11.9\pm 2.3$  mm) was 8% smaller in MS patients compared to the control group (averagely  $13.0\pm 2.1$  mm) ( $p=0.009$ ) (Papini et al., 2017).

Besides, it was determined that mean mediolateral (ML) diameter of the right foramen jugulare at the 2<sup>nd</sup>, 3<sup>rd</sup> and 4<sup>th</sup> trimesters was 2.56 mm, 2.95 mm, and 4.3 mm, respectively, while mean mediolateral (ML) diameter of the left foramen jugulare at the 2<sup>nd</sup>, 3<sup>rd</sup>, and 4<sup>th</sup> trimesters was 2.54 mm, 3.02 mm and 4.16 mm, respectively, and no significant difference was found between the right and left sides, which is compatible with the literature (Khanday et al., 2013). However, Amudha et al., (2019) noted that data obtained from the right side were larger in the examined materials.

According to the measurements performed considering the genders of the fetuses, mean anteroposterior (AP) diameter of foramen jugulare in the male fetuses at the 2<sup>nd</sup>, 3<sup>rd</sup>, and 4<sup>th</sup> trimesters were measured to be 5.24 mm, 5.26 mm, and 5.63 mm, respectively, while mean anteroposterior (AP) diameter of the foramen jugulare in the female fetuses at the 2<sup>nd</sup>, 3<sup>rd</sup>, and 4<sup>th</sup> trimesters was 4.91 mm, 4.87 mm, and 6.84 mm, respectively. Besides, mean mediolateral (ML) diameter of foramen jugulare at the 2<sup>nd</sup>, 3<sup>rd</sup>, and 4<sup>th</sup> trimesters in the male fetuses was 2.59 mm, 3.31 mm and 4.24 mm, respectively, while mean mediolateral (ML) diameter of the foramen jugulare in the female fetuses at the 2<sup>nd</sup>, 3<sup>rd</sup>, and 4<sup>th</sup> trimesters was 2.51 mm, 2.66 mm, and 4.25 mm, respectively. The literature reviews revealed no study that has been conducted on the anteroposterior and mediolateral evaluation of the foramen jugulare in terms of gender.

Foramen jugulare is composed of two compartments without a distinct septum between them. Its anterior compartment is smaller and narrower whereas the posterior compartment is larger (Tekdemir et al., 1998). The division (septation) of the foramen jugulare by bony bridges was a very rarely seen phenomenon in the present study. Among the examined fetuses, septation was encountered as division into two compartments on the left side of 1 female fetus from the 2<sup>nd</sup> trimester, and unilaterally only

right side in one of the two male fetuses from the 3<sup>rd</sup> trimester and on both right and left sides of the other male foetus. Dodo (1986) indicated that the foramen jugulare divided with a statistically insignificant septation in 7 (10.9%) and 27 (12.2%) of 64 foetus and 222 adult skulls, respectively, while Das et al., (2016) demonstrated that foramen jugulare divided with a statistically insignificant septation in 3.5% and 11.4% of males and females, respectively. Desouky et al., (2018) detected complete and partial septation on the right side in 22% and 7% of the skulls, respectively; however, they did not encounter septation at the rate of 7%. On the other hand, although they detected complete and partial septation on the left side in 20% and 77% of the skulls, respectively, they did not encounter septation at the rate of 3%. Amudha et al., (2019) have identified the presence of a partial septum at the rates of 90% and 99.7% on the right and left sides, respectively in the foramen jugulare. Rubinstein et al., (1995) stated that foramen jugulare was partially divided into two compartments with a bone in 8 of 39 cadavers and this septation coursed along the whole length of the foramen jugular in a cadaver although despite its shortness. However, some researchers (Skrzat et al, 2016) have expressed that they have rarely observed the septation of the foramen jugulare by the bony bridges, which is compatible with the present study.

The simultaneous sampling from sinus petrosus inferior by catheterization is gold standard in the diagnostic examination of Cushing's Syndrome (Miller et al., 1993; Zampetti et al., 2016). This method is the most accurate procedure in the differential diagnosis of pituitary or ectopic hypercortisolism with sensitivity of 88-100% and specificity of 67-100% compared to clinical, biochemical and imaging analyses (Zampetti et al., 2016). The anatomical information of sinus petrosus inferior has a great importance with respect to open surgical approaches for skull base and endovascular access for sinus cavernosus and cellar region (Miller et al., 1993; Mortazavi et al., 2014). On the other side, in the study by Kornieieva (2019) it was stated that at the beginning of early foetal period, the dural venous complex of the skull base was formed by two sinuses cavernosus connected by the sinus intercavernosus anterior, sinus intercavernosus posterior, sinus petrosus inferior, sinus petrosus superior and the sinus marginalis localised around the foramen magnum. From this complex, the diameter of the sinus petrosus inferior ranged between 0.9 mm and 1.4 mm and its length ranged between 7.2 mm and 16.7 mm in the measurements performed on 112 fetuses that were delivered as stillborn between the 16<sup>th</sup> and 36<sup>th</sup> gestational weeks. It was determined in the present study that length of sulcus sinus petrosi inferioris ranged between 4.36 mm and 15.61 mm on the right side and had a mean length of 10.75 mm while its length ranged between 6.22 mm and 15.17 mm on the left side and had a mean length of 10.71 mm.

Sinus sigmoideus may be easily lacerated during lateral suboccipital craniotomies since sinus sigmoideus holds the sulcus which it is embedded into and venae emissariae draining Sinus sigmoideus is strictly adhered to the bone (Hamasaki et al., 2009). Because, sinus transversus and sinus sigmoideus carry damage risk in the surgical interventions that will be performed on fossa cranii posterior at approximately 10 mm above and below the asterion, therefore determination of location of the asterion by the means of superficial remarkable points may provide protection of the venous sinuses (Çırpan et al., 2019). It was suggested in a study (Chijo et al., 1993) on the morphology of sinus sigmoideus in the adults that morphology of sinus sigmoideus exhibited significant differences among the individuals according to the findings obtained using high-resolution computed tomography and sinus sigmoideus was larger on the right side. The mean width of sulcus sinus sigmoidei was measured to be 9.17 mm and 8.54 mm on the right and left sides, respectively, in a study conducted on ossa cranii in the adults (Çırpan et al., 2019). In the present study, the length of sulcus sinus sigmoidei which is one of the structures related with the foramen jugulare was measured separately at the 2<sup>nd</sup>, 3<sup>rd</sup>, and 4<sup>th</sup> trimesters and mean length of sulcus sinus sigmoidei was found to be  $9.54 \pm 1.92$  mm,  $13.02 \pm 2.21$  mm, and  $15.22 \pm 2.03$  mm on the right side, respectively, and  $9.46 \pm 1.88$  mm,  $13.06 \pm 2.05$  mm, and  $14.94 \pm 2.04$  mm on the left side at the 2<sup>nd</sup>, 3<sup>rd</sup>, and 4<sup>th</sup> trimesters, respectively. The results of the present study supported numerically the findings in the literature (Chijo et al., 1993) for the 2<sup>nd</sup> and 4<sup>th</sup> trimesters.

In addition, the diameter of the foramen jugulare and the width of sulcus sinus sigmoidei were found to be correlated with each other at the rate of 81% and uncorrelated with each other at the rate of 9% in another study conducted on the adult individuals (Öztürk, et al., 1992).

## CONCLUSION

The information about the anatomical localization of the foramen jugulare (including size, morphology and also neighbourhoods) belonging to the foetuses that are examined in various periods throughout the complete developmental period appear to be important for anatomical studies that aim to evaluate the normal and pathological variations of the foramen jugulare as well as their relationship with the venous system of the skull. The morphometric analysis results of the foramen jugulare may be helpful for particularly neurosurgeons and radiologists in their clinical practices. Because, damages to the neural and vascular structures would be prevented during the surgical interventions thanks to the detailed identification about the surgical site based on the information about the developmental factors that affect the foramen jugulare and related structures.

## REFERENCES

- Amudha, G., Aishwarya, C. N., Hepzibah, D. J., Kesavan, V. A., & Vasuki, A. K. M. (2019). Morphometric Study of Jugular Foramen and Jugular Fossa of Dried Adult Human Skulls and Its Clinical Significance. *National Journal of Clinical Anatomy*. 8: 160-164.
- Aydınlıoğlu, A., Yeşilyurt, H., Erdem, S., Daştan, A. (2001). Foramen jugulare: a local investigation and a review of the literature. *Kaibogaku Zasshi Journal of Anatomy* 76(6): 541-5.
- Ayeni, S. A., Ohata, K., & Tanaka, K. (1995). The Microsurgical Anatomy of the Jugular Foramen. *Journal of Neurosurgery*. 83: 903-909.
- Bakar, B. (2008). The Jugular Foramen Schwannomas: Review of the Large Surgical Series. *Journal of Korean Neurosurgical Society*. 44: 285-294.
- Caldemeyer, K. S., Mathews, V. P., Azzarelli, B., & Smith, R. R. (1997). The Jugular Foramen, A Review of Anatomy, Masses, and Imaging Characteristics. *Scientific Exhibit*. 17(5): 1123-1139.
- Chijo, H., Hosokava, M., & Shinkava, H. (1993). Differences in Size and Shape Between the Right and Left Sigmoid Sinuses. *European Archives of Otorhinolaryngology*. 250: 297-299.
- Constanzo, F., Neto, M. C., Nogueira, G. F., Silva, E. B., Ramina, R. (2020). Surgical Anatomy of the Jugular Foramen. *Jornal Brasileiro de Neurocirurgia*. 29(2): 13-17.
- Çırpan, S., Yonguç, G. N., Sayhan, S., Eyüpoğlu, C., Güvençer, M. (2019). As-terion Yerleşiminin Posterolateral İntrakraniyal Girişimler Açısından Değerlendirilmesi. *Ege Journal of Medicine*. 58(2): 108-114.
- Das, S.S., Saluja, S., & Vasudeva, N. (2016). Complete Morphometric Analysis of Jugular Foramen and Its Clinical Implications. *Journal of Craniovertebral Junction and Spine*. 7: 257-64.
- Desai, V. C., & Havaladar, P. P. (2017). A Morphological Study of Jugular Foramen. *Journal of Pharmaceutical Sciences & Research*. 9(4): 456-458.
- Desouky, M. A., Ouies, S. M., & Naeemi, A. F. A. (2018). A Morphologic and Morphometric Study of the Jugular Foramen of the Adult Human Skulls: An Osteological Study in Upper Egypt. *Sohag Medical Journal*. 22(3): 189-193.
- Di Ieva, A., Bruner, E., Haider, T., Rodella, L. F., Lee, J. M., Cusimano, M.D., & Tschabitsche, M. (2014). Skull base embryology: a multidisciplinary review. *Child's Nervous System*. 30: 991-1000.
- Dias, G. J., Perumal, V., Smith, C., & Cornwall, J. (2014). The Relationship Between Jugular Foramen Asymmetry and Superior Sagittal Venous Sinus Laterality. *Antropological Science*. 122(2): 115-120.
- Dodo, Y. (1986). Observations on the bony bridging of the jugular foramen in

- man. *Journal of Anatomy*. 144, 153-165.
- Drake RL, Gray H, Vogl W, Mitchell, AWM. (2005). *Gray's Anatomy for Students*. Philadelphia: Elsevier/Churchill Livingstone.
- Ergun, K. M., & Hayran M. (2014). *Anatomi. MN Medikal & Nobel Tıp Kitabevi*. Ankara.
- Erongun, U., Uyar, Y., Ziyilan, T., Acar, O., & Şeker M. (1989). Foramen Jugulare'nin Mikroanatomisi. *Türk Nöroşirurji Dergisi*. 1(1): 9-13.
- Erzurumlu, R., Şengül, G., Ulupınar, E. (2019). *Nöroanatomî*. Güneş Tıp Kitabevleri. Ankara.
- Freitas, C. A. F., Santos, L. R. M., Santos, A. N., Neto, A. B. A., & Brandao, L. G. (2020). Anatomical Study of Jugular Foramen in the Neck. *Brazilian Journal of Otorhinolaryngology*. 86(1): 44-48.
- Griessenauer, C. J., McGrew, B., Matusz, P., De Caro, R., Loukas, M. & Tubbs, R. S. (2016). Surgical Approaches to the Jugular Foramen: A Comprehensive Review. *Journal of Neurological Surgery Part B: Skull Base*. 77(3): 260–264.
- Hamasaki, T., Morioka, M., Nakamura, H., Yano, S., Hirai, T., & Kuratsu, J. (2009). A 3-Dimensional Computed Tomographic Procedure for Planning Retrosigmoid Craniotomy. *Neurosurgery*. 64(5): 241-6.
- Hamzaoglu, V., Aktekin, M., Ismi, O., Ozalp, H., Karşıyaka, D., Baskan, F. C., Vayisoglu, Y., Arpacı, R. B., Cayan, F., Eti, C. M., Cakir, E. E., Gocer, P., Turkegun, M., Kanik, A., Bagdatoglu, C., & Talas, D. U. (2018). The Measurement of Various Anatomical Structures and Assessment of Morphometric Development of Fetal Skull Base. *The Journal of Craniofacial Surgery*. 29(3): e232-e238.
- Hatipoglu, M. T., & Anıl, A. (1992). Structural Variations in the Jugular Foramen of the Human Skull. *Journal of Anatomy*. 180: 191-96.
- Idowu, O.E. (2004). The jugular foramen-a morphometric study. *Folia Morphologica*. 63(4): 419-422.
- Junior, S. P. R., Gusmao, S. N. S., Raso, J. L., Nicolato, A. A., Santos, M., & Caetano, I. M. (2014). Comparative Morphometric Study of the Sigmoid Sinus Sulcus and The Jugular Foramen. *Arquivos Neuropsiquiatria*. 72(9): 694-698.
- Kayahoglu, G., Gövsa, F., Ertürk, M., Arısoy, Y., & Varol, T. (1996). An anatomical study of the sigmoid sulcus and related structures. *Surgical and Radiologic Anatomy*. 18, 289-294 <https://doi.org/10.1007/BF01627607>.
- Khanday, S., Subramanian, R. K., Rajendran, M., Hassan, A. U., & Khan, S.H. (2013). Morphological and Morphometric Study of Jugular Foramen in South Indian Population. *International Journal of Anatomy and Research*. 1(3): 122-27.
- Kornicieva, M. (2019). Morphology of the Dural Venous Complex of Skull Base



- in Human Ontogenesis. *Austin Journal of Anatomy*. 6(1): 1091-97.
- Kryzanski, J. T., & Heilman, C. B. (2005). Clinicopathologic Features of Jugular Foramen Tumors. *Operative Techniques in Neurosurgery*. 8(1): 6-12.
- Liu, J. K., Fukushima, T. (2012). In Schmidek and Sweet Operative Neurosurgical Techniques. Sixth Ed. Vol. I.
- Lovely, J. S. R., & Kushwah, S. (2018). Study of Morphometric Variations in Jugular Foramen and Jugular Fossa of Dried Adult Human Skulls. *International Journal of Contemporary Medical Research*. 5(5): E6-E10.
- Miller, D. L., Doppman, J. L., & Chang, R. (1993). Anatomy of the Junction of the Inferior Petrosal Sinus and the Internal Jugular Vein. *American Journal of Neuroradiology*. 14: 1075-1083.
- Mortazavi, M. M., Griessenauer, C. J., Krishnamurthy, S., Verma, K., Loukas, M., & Tubbs, R. S. (2014). The inferior petrosal sinus: a comprehensive review with emphasis on clinical implications. *Child's Nervous System*. 30:831–834. doi: 10.1007/s00381-014-2378-7.
- Navsa, N., & Kramer, B. (1998). A Quantitative Assessment of the Jugular Foramen. *Annals of Anatomy*. 180: 269-273.
- Öztürk, L., Uysal, A., & Pala S. (1992). Jugular foramen ile sulcus sigmoideus ve fossa jugularis arasındaki ilişkilerin incelenmesi. *Ege Tıp Fak Derg*. 31: 111-114.
- Papini, G. D. E., Leo, G. D., Zanardo, M., Fedeli, M.P., Merli, I., & Sardanelli, F. (2017). Measurement of jugular foramen diameter using MRI in multiple sclerosis patients compared to control subjects. *European Radiology Experimental*. 1:4. doi: 10.1186/s41747-017-0008-3
- Rhoton A. L. (2000). Jugular Foramen. *Neurosurgery*. 47: 267-285.
- Rubinstein, D., Burton, B. S., & Walker, A. L. (1995). The Anatomy of the Inferior Petrosal Sinus, Glossopharyngeal Nerve, Vagus Nerve, and Accessory Nerve in the Jugular Foramen. *American Journal of Neuroradiology*. 16: 185-194.
- Saberi, B. (2019). Surgical Anatomy of the Foramen Jugular. *Techniques in Neurosurgery & Neurology*. 2(2): doi: 10.31031/TNN.2019.02.000537.
- Sahep, H. S., Mavishetter, G. F., Thomas, S. T., Prasanna, L. C., & Muralidhar, P. (2010). A Morphometric Study of the Jugular Foramen in Human Adult Skulls of South India. *Journal of Biomedical Science and Research*. 2(4): 240-243.
- Sethi, R., Singh, V., & Kaul, N. V. (2011). Morphological Variations of a Jugular Foramen in North Indian Human Adult Skulls. *Indian Journal of Otology*. 17: 14-16.
- Shapiro, R., & Robinson, F. (1967). The foramina of the middle fossa: a phylogenetic, anatomic and pathologic study. Vol: 101, No: 1, New Haven, Yale University School of Medicine.

- Sharma, N. A., & Garud, R. S. (2011). Foramine of the Posterior Cranial Base: A Study of Adult Indian Skulls. *Revista Argentina de Anatomia Clinica*. 3(2): 89-98.
- Shruthi, B. N., Havaldar, P. H., & Saheb, S. H. (2015). Study on Morphological Variations in Structure of the Jugular Foramen. *International Journal of Anatomy and Research*. 3(4): 1533-35.
- Skrzat, J., Mróz, I., Spulber, A., & Walocha, J. (2016). Morphology, topography and clinical significance of the jugular foramen. *Folia Medica Cracoviensia*. 56(1): 71–80.
- Tekdemir, I., Tuccar, E., Aslan, A., Elhan, A., Deda, H., Ciftci, E., & Akyar, S. (1998). The Jugular Foramen: A Comparative Radioanatomic Study. *Surgical Neurology*. 50: 557-62.
- Tummala, R. P., Coscarella, E., & Morcos, J. J. (2005). Surgical Anatomy of the Jugular Foramen. *Operative Techniques in Neurosurgery*. 8: 2-5.
- Vogl, T. J., & Bisdas, S. (2009). Differential Diagnosis of Jugular Foramen Lesions. *Skull Base*. 19(1): 3-16.
- Zampetti, B., Grossrubatscher, E., Ciaramella, P. D., Boccardi, E., & Loli, P. (2016). Bilateral inferior petrosal sinus sampling. *Endocrine Connections*. 5, R12–R25.